

---

## Awareness on Oral Manifestation of Sarcoidosis Among Dental Students

---

PATHMASHRI.V. P<sup>1</sup>, DHANRAJ GANAPATHY<sup>2\*</sup>, KIRAN KUMAR PANDURANGAN,  
ASHOK VELAYUDHAN<sup>4</sup>

<sup>1</sup>Saveetha Dental College and Hospital, Saveetha Institute of Medical and Technical Sciences, Saveetha University, Chennai

<sup>2</sup>Professor and H.O.D, Department of Prosthodontic, Saveetha Dental College and Hospital, Saveetha Institute of Medical and Technical Sciences, Saveetha University, Chennai

<sup>3</sup>Senior lecturer, Department of Prosthodontic, Saveetha Dental College and Hospital, Saveetha Institute of Medical and Technical Sciences, Saveetha University, Chennai

<sup>4</sup>Professor and Head, Department of Prosthodontic, Saveetha Dental College and Hospital, Saveetha Institute of Medical and Technical Sciences, Saveetha University, Chennai

\*Corresponding Author

Email: pathmashri1997@gmail.com

---

**Abstract:** The aim is to understand and create awareness about the oral manifestation of sarcoidosis among the dental students. Sarcoidosis is a common multisystemic granulomatous disease. Sarcoidosis is an inflammatory disease characterized by formation of non-necrotizing epithelioid granulomas. Granulomas are tiny clumps of inflammatory cells in one or more organs in our body. These can interfere with an organ's function and structure, if our immune system is over driven by these clumps of inflammatory cells. The commonly affected organs are lungs and in the head and neck its salivary glands. Oral manifestations of sarcoidosis are very rare and usually appear as non-tender swelling and ulcers in the lips, hard and soft palate, buccal mucosa, tongue and tonsils. The intraoral localized sarcoid lesion is histologically similar to a generalized sarcoidosis. No single test is enough for diagnosing and the presence of granuloma is also not enough to conclude the diagnosis. Oral manifestation of sarcoidosis is unusual, dentists must be aware that oral manifestation is specific localization and it is usually the first manifestation of the diseases. Therefore by knowing the oral manifestation of sarcoidosis, the dental students can be more aware of the prevalence of sarcoidosis and spread awareness among the patients.

**Keywords:** Sarcoidosis, Granuloma, Oral cavity, Oral sarcoidosis, Granulomatosis.

---

### INTRODUCTION

Sarcoidosis is a multisystemic inflammatory disease. It is characterized by abnormal collection of inflammatory cells leading to formation of non-necrotizing granulomas (Radochová *et al.*, 2016). The first person to describe sarcoidosis is English doctor Jonathan Hutchison. He described it as a non-painful skin disease (James and Sharma, 2002). Sarcoidosis has a distinguished medical history that stretches over all continents and since 1950 there has been rapid progress in understanding the clinical, physiological, pathological and histological aspects of sarcoidosis. The most commonly affected system is the respiratory system, more clearly Lungs. Pulmonary hypertension, cardiomyopathy, renal failure, blindness, neurological diseases and uveitis are some of the manifestations of sarcoidosis (Iannuzzi and Fontana, 2011).

It is of unknown origin and its prognosis is uncertain. It usually presents with bilateral lymphadenopathy, pulmonary infiltrates and skin lesions (Spagnolo, 2015). Increased T-helper cell type 1 and decreased cutaneous delayed type hypersensitivity are the frequently observed immunological features. B-Cell hypersensitivity with circulating immune-complexes can also be seen (Sharma, 2005). With the cause of its occurrence being unknown, the diagnosis of these diseases is not easy since there is no reliable diagnostic test (Baughman *et al.*, 2006). It is believed by some as an immune reaction to an infection or chemical in those people who are already predisposed to it genetically. So the people with a genetic history of sarcoidosis are at greater risk than others (Baughman, Culver and Judson, 2011).

The diagnosis of sarcoidosis remains a challenging issue principally because there is no specific reliable diagnostic test. Various criteria have been established as diagnostic guidelines like the following. Since there is no reliable specific test for diagnosing sarcoidosis, diagnosing itself is a challenging task. But diagnosis can be made using various guidelines. First is Granulomas, a collection of inflammatory cells. In a study done in 2013 on pathological and clinical analysis of completely respected nodules in 131 patients, it was found that 40%

were unknown and the remaining 5% of the nodules were due to sarcoidosis (Judson, 2014) (Mukhopadhyay *et al.*, 2013).

Second is to exclude the alternative diagnosis to granulomatous inflammation like Tuberculosis, Mycoplasma, Reaction to foreign bodies like paraffin, beryllium, tattooing, Rheumatoid nodules, Hodgkin's disease, Non-Hodgkin's lymphomas, Atypical mycobacteriosis, Sarcoid reaction in regional lymph nodes to carcinoma, GLUS syndrome, Reaction to few drugs, Hypersensitivity pneumonitis, Kikuchi's diseases (Granulomatous histiocytic necrotizing lymphadenitis)(Newman *et al.*, 1989) (Mukhopadhyay and Gal, 2010). Third is to understand that Sarcoidosis is not confined to lungs or any other organ. It is a systemic disease. To confirm it is sarcoidosis, granuloma must be seen in at least two organs(Harris, McConnochie and Adams, 1993).

Oral manifestation of this disease is rare but in most cases the clinical presentation of sarcoidosis in the head and neck region appears as non-tender swelling or nodular lesion. These swellings are firm on palpation with no pain. Most commonly affected organs in the head and neck region are salivary gland and lymph nodes, oral mucosa involvement is not that common(Radochová *et al.*, 2016). In this study the knowledge of dental students on sarcoidosis and its oral manifestation are analyzed through a questionnaire. Since the head and neck presentation of sarcoidosis is non tender most of the patients may not take it seriously and it's the responsibility of the dentist to bring awareness to the patient. Our team has rich experience in research and we have collaborated with numerous authors over various topics in the past decade (Deogade, Gupta and Ariga, 2018; Ezhilarasan, 2018; Ezhilarasan, Sokal and Najimi, 2018; Jeevanandan and Govindaraju, 2018; J *et al.*, 2018; Menon *et al.*, 2018; Prabakar *et al.*, 2018; Rajeshkumar *et al.*, 2018, 2019; Vishnu Prasad *et al.*, 2018; Wahab *et al.*, 2018; Dua *et al.*, 2019; Duraisamy *et al.*, 2019; Ezhilarasan, Apoorva and Ashok Vardhan, 2019; Gheena and Ezhilarasan, 2019; Malli Sureshbabu *et al.*, 2019; Mehta *et al.*, 2019; Panchal, Jeevanandan and Subramanian, 2019; Rajendran *et al.*, 2019; Ramakrishnan, Dhanalakshmi and Subramanian, 2019; Sharma *et al.*, 2019; Varghese, Ramesh and Veeraiyan, 2019; Gomathi *et al.*, 2020; Samuel, Acharya and Rao, 2020)

## **MATERIALS AND METHODS**

A cross sectional study was conducted among 100 randomly selected dental students who were in their third year, final year or doing their internship in dental school, attending a private dental college in Chennai. A self-structured questionnaire was used to assess the knowledge of the participants based on their knowledge on sarcoidosis, etiology, its clinical features on body and oral cavity, diagnosis and treatment. Most of the questions were true or false type questions.

## **RESULTS AND DISCUSSION**

Cancer is a group of diseases involving abnormal growth of cells which tend to proliferate in an uncontrolled way, with the potential to invade or spread to other parts of the body(Watters, Epstein and Agulnik, 2011). Sarcoidosis is not contagious, not a type or form of cancer. It does not cause the affected individuals disabled, most people with sarcoidosis who were not diagnosed at the tertiary stage but earlier live a normal life. And in the majority of the cases the disease appears briefly and disappears on its own. In this study majority of the participants thought it is a form of cancer, mainly because it appears as a lump or growth but in sarcoidosis the lump consists of inflammatory cells, where in cancer it's a mass of abnormal growth of cells in that particular region. In this study 74% of the participants answered that sarcoidosis is a form of cancer and the rest said sarcoidosis was a type or form of cancer. It is represented in Graph 1.

Sarcoidosis can be inherited. Sarcoidosis is an immunological disorder. It is believed that it occurs in people with genetic predisposition to sarcoidosis. When an individual with the genetic predisposition to sarcoidosis is exposed to certain triggers like bacteria, viruses, chemicals, etc, their bodies produce inappropriate immune response or in other words their bodies over react to the triggers leading to the formation of granulomas in various organs(Kamangar, Rohani and Shorr, 2014). In a study by Iannuzzi in the year 2007 on the genetics of sarcoidosis, Iannuzzi explained that sarcoidosis usually results as a result of both genetic and environmental cause and there is no single causative agent. In his study it is also said that HLA alleles (Human Leukocyte Antigen) of some type are associated with sarcoidosis. There are two human genome scan linkages reported in sarcoidosis. Among them one belongs to African American linkage to chromosome 5 and the other is German family linkage to chromosome 6(Iannuzzi and Rybicki, 2007). In this study 78% of the participants answered right by answering it as an inherited disease. And 22% of the participants answered it wrong. And their explanation was that they thought it was a transmitting disease. It is represented in Graph 2.

Sarcoidosis is a common disease but oral manifestation of sarcoidosis is not very common and the oral lesion may be the initial manifestation of the diseases. In a review by Dr.suresh L in the year 2005 he has documented 47 cases among which 21 cases involved jaw bones and the rest involved buccal mucosa, gingiva, lips, floor of the mouth, submandibular gland, tongue and palate. Due to its nature of presentation the patient may not know the seriousness of sarcoidosis and it is important to understand the prognosis of the diseases. In this study 71 % participants answered the question right about the question on incidence of oral sarcoidosis. It is represented in Graph 3.

Sarcoidosis indirectly causes tooth mobility by causing vertical bone loss in the jaws. Sarcoidosis affecting the bones or the skeletal structure is not very common. But in some cases intraosseous sarcoidosis causes loss of the bone with pain and mobility of tooth eventually leading to loss of tooth. In a study by Mortti AJ in the year 2007 did a long term follow up of a case which was reported for pulmonary sarcoidosis with periodontitis. Though initial preventive and preliminary procedures like scaling, oral hygiene reinforcement, root planing and periodontal management were done. The patient reported back again with pain and mobility of tooth and on investigation it was found that there was intraosseous bone loss. The affected teeth were extracted followed by debridement of the bone (Moretti, Fiocchi and Flaitz, 2007) (Suresh *et al.*, 2004). In this study 66% of the participants answered the question right by saying sarcoidosis causes tooth mobility and the rest 34% answered the question wrong. It is represented in Graph 4.

The characteristic feature of sarcoidosis is Granuloma. Granuloma is a growth containing inflammatory cells. In a well developed granuloma in sarcoidosis a mix of epithelioid cells and multinucleated giant cells surrounded by lymphocytes can be seen. The surrounding cells mainly consist of CD4 T helper cells, CD8 T helper cells and B cells. Due to lack of research the exact reason and order of formation of these granulomas are not clear. A thorough clinical and histological trail must be done before arriving at a conclusion for granuloma. And also further research studies are needed to understand the cellular and molecular mechanisms of granuloma and its formation (Kosjerina *et al.*, 2012). In this study 64% of the participants answered granuloma followed by 30% answered mouth ulcers. It is represented in Graph 5.

The most classical clinical feature of granuloma is painless swellings. Granuloma are painless but they disturb the normal functioning and structure of the organ it is present in. For example, when the pulmonary fibrosis in the lungs (the commonly affected organ) is left to persist for a long time it can lead to respiratory failure. Ulcers in oral mucosa is present but not very common, these ulcers can be tender on palpation. Tender swellings are not seen in sarcoidosis. In case of sarcoidosis in the salivary glands the granuloma disturbs the whole anatomy of the gland there by disturbing the salivary flow leading to pain. Swellings and nodules are not tender on its own but do affect the function and thereby causing further complication. Bleeding gums are not a feature of sarcoidosis. In this study 64% of the participants said the characteristic feature of sarcoidosis is painless nodules and 30% of individuals answered mouth ulcers and the rest said bleeding gums. It is represented in Graph 6.

As represented in Graph 7, Salivary glands are involved in sarcoidosis. Sarcoidosis in salivary glands is present as painless swellings, with the enlargement being persistent and xerostomia. In case of parotid gland involvement there is persistent painless swelling with rise in body temperature indicating fever (Rao *et al.*, 2008). In this study 72% of the individuals answered that salivary glands are involved in sarcoidosis. 28% of the participants answered there is no salivary involvement.

Buccal sarcoidosis is not associated with severe cases. Buccal sarcoidosis a secondary feature of sarcoidosis. Presence of ulcerative lesions can be seen in the buccal mucosa. In this study 76% of the students said that buccal sarcoidosis is not associated with the severity of the diseases. And the rest 24% said it is associated. The mouth ulcers may look severe and the patient may undergo a lot of pain due to those lesions in buccal mucosa but they are not associated with the severe cases. As represented in Graph 8.

Angular cheilitis and lingual placita are other oral manifestations of sarcoidosis. Angular cheilitis is cracks and inflammation seen in the one or both the corners of lips. It is mainly caused due to buildup of microorganisms in the corners of the lips. Patients may complain of painful sores in either the corners or any one corner of the lip with burning sensation, which can be aggravated on intake of hot and spicy food. Lingual placita are deep grooves on the dorsum of the tongue. They sometimes occur on the sides of the tongue too. These as the angular cheilitis can cause discomfort during intake of hot or spicy foods. In this study 70 % of the students said true, there by saying angular cheilitis and lingual placita are other oral manifestations of sarcoidosis. It is represented in graph 9.

The last question was whether Anti-malarial drugs are used in treating sarcoidosis. The correct answer is Anti-malarial drugs are used in treating sarcoidosis. Anti-malarial drugs include Hydroxychloroquine and Chloroquine is used in treating sarcoidosis. These drugs are used to prevent the release of chemicals that promote the inflammation process. These are the drugs of choice in any type of sarcoidosis like pulmonary sarcoidosis, cutaneous sarcoidosis, neurosarcoidosis, etc. this is because granuloma the main characteristic feature of sarcoidosis is a clustering of inflammatory cells leading to the formation of a lump. In this study 78% of the participants answered anti-malarial drugs are used in treating sarcoidosis and the rest 22% answered that the anti-malarial drugs are not used to treat sarcoidosis. It is represented in graph 10.

In a study done by Suresh L on a case report review on intraosseous sarcoidosis of jaws which mimics progressive periodontitis. A 46 year old male reported for replacement of his lost teeth with implants. He gave the history of sarcoidosis being diagnosed in 1998 and he had also been losing all his teeth gradually since 1999. On radiographic analysis bilateral cotton wool appearance was seen in his mandible. In histological examination of soft tissue and bone biopsy there were non caseating granulomatous inflammations consistent with skeletal sarcoidosis. Thus in conclusion it can be said that though in intraosseous sarcoidosis of the jaw the progressive

loss of alveolar bone may resemble progressive periodontitis, a thorough examination is very important to diagnose this condition (Suresh *et al.*, 2004).

In a study by Danielle Blinder MD on oral manifestation of sarcoidosis 45 cases of sarcoidosis with oral manifestations were analyzed among those 43 cases from previous reports and the rest two were new cases reported for sarcoidosis. On analysis it was revealed 12 lesions in the jaw, 5 in the floor of the mouth, 4 in the lips, 5 in the tongue and 3 in the palate. In each part of the oral cavity the presentation of the sarcoidosis varied. In gingiva there were painless swellings, in lips, palate and buccal mucosa there were submucosal nodules, and sarcoidosis can also be presented as ranula in the tongue and floor of the mouth. Thus considering oral sarcoidosis as a differential diagnosis for soft tissue swelling in the oral cavity was the conclusion of this study (Blinder, Yahatom and Taicher, 1997).

A study on oral and extra oral manifestation of sarcoidosis by Sanjay Gupta a case report of a 40 year old male patient with oral cavity lesion and sarcoidosis was analyzed and the conclusion was though sarcoidosis is a common disease, its oral manifestations are uncommon. So for diagnosing a case a complete test involving clinical history, biochemical, and hematological tests are important. Since it is a multisystemic disorder it cannot be cured completely (Gupta *et al.*, 2015).

A similar study was done by A E Kolokotronis on sarcoidosis and its oral and perioral manifestations. This was a case report study of a 46 year old white woman who was reported because of a persisting lesion on the skin of her chin region and lower lip and also the soft tissues of oral cavity. On examination there was a well circumscribed plaque of skin on the chin and lower lip, well defined asymptomatic red-violet nodule in the mid palatal region and a diffuse erythematous and hyperplastic gingiva in the maxillary incisor region, along with no palpable lymph nodes and normal salivary glands. In conclusion it was said that oral involvement of these diseases was very rare and in case of oral manifestation of sarcoidosis the prognosis, initial onset, progression, extent of diseases and so on must be considered (Kolokotronis *et al.*, 2009). In another case study by Vladimira Radochova on a 59 year old female reported with a chief complaint of three months lasting painless ulcer in the lower lip region. On examination the lesions were seen on buccal mucosa too. The patient was diagnosed with sarcoidosis after a series of tests and was treated with a treatment plan involving a combination of surgery and topical steroids (Radochová *et al.*, 2016). Our institution is passionate about high quality evidence based research and has excelled in various fields (Pc, Marimuthu and Devadoss, 2018; Ramesh *et al.*, 2018; Vijayashree Priyadharsini, Smiline Giriya and Paramasivam, 2018; Ezhilarasan, Apoorva and Ashok Vardhan, 2019; Ramadurai *et al.*, 2019; Sridharan *et al.*, 2019; Vijayashree Priyadharsini, 2019; Chandrasekar *et al.*, 2020; Mathew *et al.*, 2020; R *et al.*, 2020; Samuel, 2021)

## CONCLUSION

Sarcoidosis can be painless until the function of the organ is affected. Oral manifestation is not very common in sarcoidosis and the oral manifestation alone cannot be sarcoidosis. Bone loss is very common in intraosseous sarcoidosis thus leading to mobility of teeth, which can be very well misinterpreted for progressive periodontitis. Due to its non tender nature it may not bother the patient much but it has to be treated with utmost importance, since it may lead to loss of teeth, xerostomia and so on. The etiology cannot be determined or pin pointed to one cause, the most common is genetic predisposition. Clinical presentation varies from person to person and also depends on the severity of the diseases. In case of treatment it is immune suppressants, antimalarial drugs, topical steroids for the ulcerative lesions and surgery.

## REFERENCES

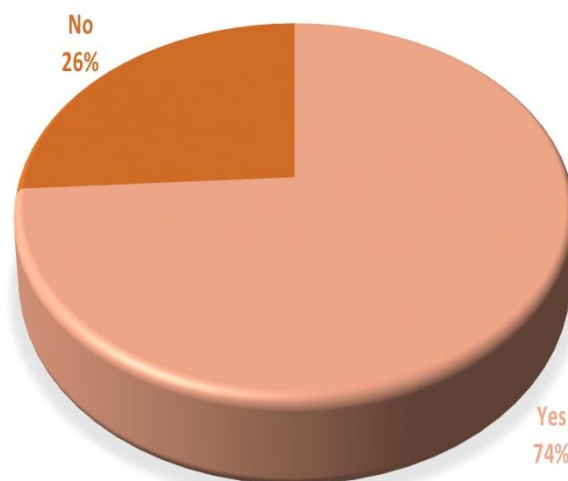
1. Baughman, R. P. et al. (2006) 'Infliximab therapy in patients with chronic sarcoidosis and pulmonary involvement', *American journal of respiratory and critical care medicine*, 174(7), pp. 795–802. doi: 10.1164/rccm.200603-402OC.
2. Baughman, R. P., Culver, D. A. and Judson, M. A. (2011) 'A concise review of pulmonary sarcoidosis', *American journal of respiratory and critical care medicine*, 183(5), pp. 573–581. doi: 10.1164/rccm.201006-0865CI.
3. Blinder, D., Yahatom, R. and Taicher, S. (1997) 'Oral manifestations of sarcoidosis', *Oral surgery, oral medicine, oral pathology, oral radiology, and endodontics*, 83(4), pp. 458–461. doi: 10.1016/s1079-2104(97)90145-1.
4. Chandrasekar, R. et al. (2020) 'Development and validation of a formula for objective assessment of cervical vertebral bone age', *Progress in orthodontics*, 21(1), p. 38. doi: 10.1186/s40510-020-00338-0.
5. Deogade, S., Gupta, P. and Ariga, P. (2018) 'Effect of monopoly-coating agent on the surface roughness of a tissue conditioner subjected to cleansing and disinfection: A Contact Profilometric In vitro study', *Contemporary Clinical Dentistry*, p. 122. doi: 10.4103/ccd.ccd\_112\_18.
6. Dua, K. et al. (2019) 'The potential of siRNA based drug delivery in respiratory disorders: Recent advances and progress', *Drug development research*, 80(6), pp. 714–730. doi: 10.1002/ddr.21571.
7. Duraisamy, R. et al. (2019) 'Compatibility of Nonoriginal Abutments With Implants: Evaluation of

- Microgap at the Implant-Abutment Interface, With Original and Nonoriginal Abutments', *Implant dentistry*, 28(3), pp. 289–295. doi: 10.1097/ID.0000000000000885.
8. Ezhilarasan, D. (2018) 'Oxidative stress is bane in chronic liver diseases: Clinical and experimental perspective', *Arab journal of gastroenterology: the official publication of the Pan-Arab Association of Gastroenterology*, 19(2), pp. 56–64. doi: 10.1016/j.ajg.2018.03.002.
  9. Ezhilarasan, D., Apoorva, V. S. and Ashok Vardhan, N. (2019) 'Syzygium cumini extract induced reactive oxygen species-mediated apoptosis in human oral squamous carcinoma cells', *Journal of oral pathology & medicine: official publication of the International Association of Oral Pathologists and the American Academy of Oral Pathology*, 48(2), pp. 115–121. doi: 10.1111/jop.12806.
  10. Ezhilarasan, D., Sokal, E. and Najimi, M. (2018) 'Hepatic fibrosis: It is time to go with hepatic stellate cell-specific therapeutic targets', *Hepatobiliary & pancreatic diseases international: HBPD INT*, 17(3), pp. 192–197. doi: 10.1016/j.hbpd.2018.04.003.
  11. Gheena, S. and Ezhilarasan, D. (2019) 'Syringic acid triggers reactive oxygen species-mediated cytotoxicity in HepG2 cells', *Human & experimental toxicology*, 38(6), pp. 694–702. doi: 10.1177/0960327119839173.
  12. Gomathi, A. C. et al. (2020) 'Anticancer activity of silver nanoparticles synthesized using aqueous fruit shell extract of Tamarindus indica on MCF-7 human breast cancer cell line', *Journal of Drug Delivery Science and Technology*, p. 101376. doi: 10.1016/j.jddst.2019.101376.
  13. Gupta, S. et al. (2015) 'Sarcoidosis: Oral and extra-oral manifestation', *Journal of Indian Society of Periodontology*, 19(5), pp. 582–585. doi: 10.4103/0972-124X.167167.
  14. Harris, K. M., McConnochie, K. and Adams, H. (1993) 'The computed tomographic appearances in chronic berylliosis', *Clinical radiology*, 47(1), pp. 26–31. doi: 10.1016/s0009-9260(05)81209-7.
  15. Iannuzzi, M. C. and Fontana, J. R. (2011) 'Sarcoidosis: clinical presentation, immunopathogenesis, and therapeutics', *JAMA: the journal of the American Medical Association*, 305(4), pp. 391–399. doi: 10.1001/jama.2011.10.
  16. Iannuzzi, M. C. and Rybicki, B. A. (2007) 'Genetics of sarcoidosis: candidate genes and genome scans', *Proceedings of the American Thoracic Society*, 4(1), pp. 108–116. doi: 10.1513/pats.200607-141JG.
  17. James, D. G. and Sharma, O. P. (2002) 'From Hutchinson to now: a historical glimpse', *Current opinion in pulmonary medicine*, 8(5), pp. 416–423. doi: 10.1097/00063198-200209000-00013.
  18. Jeevanandan, G. and Govindaraju, L. (2018) 'Clinical comparison of Kedo-S paediatric rotary files vs manual instrumentation for root canal preparation in primary molars: a double blinded randomised clinical trial', *European Archives of Paediatric Dentistry*, pp. 273–278. doi: 10.1007/s40368-018-0356-6.
  19. J, P. C. et al. (2018) 'Prevalence and measurement of anterior loop of the mandibular canal using CBCT: A cross sectional study', *Clinical implant dentistry and related research*, 20(4), pp. 531–534. doi: 10.1111/cid.12609.
  20. Judson, M. A. (2014) 'Advances in the diagnosis and treatment of sarcoidosis', *F1000prime reports*, 6, p. 89. doi: 10.12703/P6-89.
  21. Kamangar, N., Rohani, P. and Shorr, A. F. (2014) 'Peters SP, Talavera F, Rice TD, Mosenifar Z, ed', *Sarcoidosis*. Medscape Reference. Web-MD.
  22. Kolokotronis, A. E. et al. (2009) 'Sarcoidosis: oral and perioral manifestations', *Hippokratia*, 13(2), pp. 119–121. Available at: <https://www.ncbi.nlm.nih.gov/pubmed/19561785>.
  23. Kosjerina, Z. et al. (2012) 'The sarcoid granuloma: "epithelioid" or "lymphocytic-epithelioid" granuloma?', *Multidisciplinary respiratory medicine*, 7(1), p. 11. doi: 10.1186/2049-6958-7-11.
  24. Malli Sureshbabu, N. et al. (2019) 'Concentrated Growth Factors as an Ingenious Biomaterial in Regeneration of Bony Defects after Periapical Surgery: A Report of Two Cases', *Case reports in dentistry*, 2019, p. 7046203. doi: 10.1155/2019/7046203.
  25. Mathew, M. G. et al. (2020) 'Evaluation of adhesion of Streptococcus mutans, plaque accumulation on zirconia and stainless steel crowns, and surrounding gingival inflammation in primary molars: Randomized controlled trial', *Clinical oral investigations*, pp. 1–6. Available at: <https://link.springer.com/article/10.1007/s00784-020-03204-9>.
  26. Mehta, M. et al. (2019) 'Oligonucleotide therapy: An emerging focus area for drug delivery in chronic inflammatory respiratory diseases', *Chemico-biological interactions*, 308, pp. 206–215. doi: 10.1016/j.cbi.2019.05.028.
  27. Menon, S. et al. (2018) 'Selenium nanoparticles: A potent chemotherapeutic agent and an elucidation of its mechanism', *Colloids and Surfaces B: Biointerfaces*, pp. 280–292. doi: 10.1016/j.colsurfb.2018.06.006.
  28. Moretti, A. J., Fiocchi, M. F. and Flaitz, C. M. (2007) 'Sarcoidosis affecting the periodontium: A long-term follow-up case', *Journal of periodontology*. Available at: <https://aap.onlinelibrary.wiley.com/doi/abs/10.1902/jop.2007.070117>.
  29. Mukhopadhyay, S. et al. (2013) 'Pulmonary necrotizing granulomas of unknown cause: clinical and pathologic analysis of 131 patients with completely resected nodules', *Chest*, 144(3), pp. 813–824. doi: 10.1378/chest.12-2113.

30. Mukhopadhyay, S. and Gal, A. A. (2010) 'Granulomatous lung disease: an approach to the differential diagnosis', *Archives of pathology & laboratory medicine*, 134(5), pp. 667–690. doi: 10.1043/1543-2165-134.5.667.
31. Newman, L. S. et al. (1989) 'Pathologic and immunologic alterations in early stages of beryllium disease. Re-examination of disease definition and natural history', *The American review of respiratory disease*, 139(6), pp. 1479–1486. doi: 10.1164/ajrccm/139.6.1479.
32. Panchal, V., Jeevanandan, G. and Subramanian, E. M. G. (2019) 'Comparison of post-operative pain after root canal instrumentation with hand K-files, H-files and rotary Kedo-S files in primary teeth: a randomised clinical trial', *European archives of paediatric dentistry: official journal of the European Academy of Paediatric Dentistry*, 20(5), pp. 467–472. doi: 10.1007/s40368-019-00429-5.
33. Pc, J., Marimuthu, T. and Devadoss, P. (2018) 'Prevalence and measurement of anterior loop of the mandibular canal using CBCT: A cross sectional study', *Clinical implant dentistry and related research*. Available at: <https://europepmc.org/article/med/29624863>.
34. Prabakar, J. et al. (2018) 'Comparative Evaluation of Retention, Cariostatic Effect and Discoloration of Conventional and Hydrophilic Sealants - A Single Blinded Randomized Split Mouth Clinical Trial', *Contemporary clinical dentistry*, 9(Suppl 2), pp. S233–S239. doi: 10.4103/ccd.ccd\_132\_18.
35. Radochová, V. et al. (2016) 'Oral manifestation of sarcoidosis: A case report and review of the literature', *Journal of Indian Society of Periodontology*, 20(6), pp. 627–629. doi: 10.4103/jisp.jisp\_378\_16.
36. Rajendran, R. et al. (2019) 'Comparative Evaluation of Remineralizing Potential of a Paste Containing Bioactive Glass and a Topical Cream Containing Casein Phosphopeptide-Amorphous Calcium Phosphate: An in Vitro Study', *Pesquisa Brasileira em Odontopediatria e Clínica Integrada*, pp. 1–10. doi: 10.4034/pboci.2019.191.61.
37. Rajeshkumar, S. et al. (2018) 'Biosynthesis of zinc oxide nanoparticles using *Mangifera indica* leaves and evaluation of their antioxidant and cytotoxic properties in lung cancer (A549) cells', *Enzyme and microbial technology*, 117, pp. 91–95. doi: 10.1016/j.enzmictec.2018.06.009.
38. Rajeshkumar, S. et al. (2019) 'Antibacterial and antioxidant potential of biosynthesized copper nanoparticles mediated through *Cissus arnotiana* plant extract', *Journal of photochemistry and photobiology. B, Biology*, 197, p. 111531. doi: 10.1016/j.jphotobiol.2019.111531.
39. Ramadurai, N. et al. (2019) 'Effectiveness of 2% Articaine as an anesthetic agent in children: randomized controlled trial', *Clinical oral investigations*, 23(9), pp. 3543–3550. doi: 10.1007/s00784-018-2775-5.
40. Ramakrishnan, M., Dhanalakshmi, R. and Subramanian, E. M. G. (2019) 'Survival rate of different fixed posterior space maintainers used in Paediatric Dentistry - A systematic review', *The Saudi dental journal*, 31(2), pp. 165–172. doi: 10.1016/j.sdentj.2019.02.037.
41. Ramesh, A. et al. (2018) 'Comparative estimation of sulfiredoxin levels between chronic periodontitis and healthy patients - A case-control study', *Journal of periodontology*, 89(10), pp. 1241–1248. doi: 10.1002/JPER.17-0445.
42. Rao, V. et al. (2008) 'Salivary glands sarcoidosis', *Operative Techniques in Otolaryngology-Head and Neck Surgery*, 19(4), pp. 234–236. doi: 10.1016/j.otot.2008.10.006.
43. R, H. et al. (2020) 'CYP2 C9 polymorphism among patients with oral squamous cell carcinoma and its role in altering the metabolism of benzo[a]pyrene', *Oral Surgery, Oral Medicine, Oral Pathology and Oral Radiology*, pp. 306–312. doi: 10.1016/j.oooo.2020.06.021.
44. Samuel, S. R. (2021) 'Can 5-year-olds sensibly self-report the impact of developmental enamel defects on their quality of life?', *International journal of paediatric dentistry / the British Paedodontic Society [and] the International Association of Dentistry for Children*, 31(2), pp. 285–286. doi: 10.1111/ipd.12662.
45. Samuel, S. R., Acharya, S. and Rao, J. C. (2020) 'School Interventions-based Prevention of Early-Childhood Caries among 3-5-year-old children from very low socioeconomic status: Two-year randomized trial', *Journal of public health dentistry*, 80(1), pp. 51–60. doi: 10.1111/jphd.12348.
46. Sharma, O. P. (2005) 'Definition and history of sarcoidosis', *European Respiratory Monograph*, 32, p. 1. Available at: [https://books.google.com/books?hl=en&lr=&id=G5UpFyIqy\\_IC&oi=fnd&pg=PA1&dq=Sharma+OP+Definition+and+history+of+sarcoidosis&ots=0OtCpU68ZK&sig=Ea6M5G3VVCVH544tuCf0QR3odFXg](https://books.google.com/books?hl=en&lr=&id=G5UpFyIqy_IC&oi=fnd&pg=PA1&dq=Sharma+OP+Definition+and+history+of+sarcoidosis&ots=0OtCpU68ZK&sig=Ea6M5G3VVCVH544tuCf0QR3odFXg).
47. Sharma, P. et al. (2019) 'Emerging trends in the novel drug delivery approaches for the treatment of lung cancer', *Chemico-biological interactions*, 309, p. 108720. doi: 10.1016/j.cbi.2019.06.033.
48. Spagnolo, P. (2015) 'Sarcoidosis: a Critical Review of History and Milestones', *Clinical reviews in allergy & immunology*, 49(1), pp. 1–5. doi: 10.1007/s12016-015-8480-0.
49. Sridharan, G. et al. (2019) 'Evaluation of salivary metabolomics in oral leukoplakia and oral squamous cell carcinoma', *Journal of oral pathology & medicine: official publication of the International Association of Oral Pathologists and the American Academy of Oral Pathology*, 48(4), pp. 299–306. doi: 10.1111/jop.12835.
50. Suresh, L. et al. (2004) 'Intraosseous sarcoidosis of the jaws mimicking aggressive periodontitis: a case

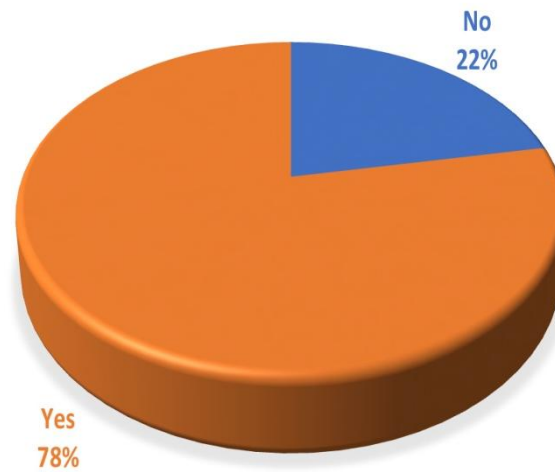
- report and literature review', *Journal of periodontology*, 75(3), pp. 478–482. doi: 10.1902/jop.2004.75.3.478.
51. Varghese, S. S., Ramesh, A. and Veeraiyan, D. N. (2019) 'Blended Module-Based Teaching in Biostatistics and Research Methodology: A Retrospective Study with Postgraduate Dental Students', *Journal of dental education*, 83(4), pp. 445–450. doi: 10.21815/JDE.019.054.
  52. Vijayashree Priyadharsini, J. (2019) 'In silico validation of the non-antibiotic drugs acetaminophen and ibuprofen as antibacterial agents against red complex pathogens', *Journal of periodontology*, 90(12), pp. 1441–1448. doi: 10.1002/JPER.18-0673.
  53. Vijayashree Priyadharsini, J., Smiline Girija, A. S. and Paramasivam, A. (2018) 'In silico analysis of virulence genes in an emerging dental pathogen *A. baumannii* and related species', *Archives of oral biology*, 94, pp. 93–98. doi: 10.1016/j.archoralbio.2018.07.001.
  54. Vishnu Prasad, S. et al. (2018) 'Report on oral health status and treatment needs of 5-15 years old children with sensory deficits in Chennai, India', *Special care in dentistry: official publication of the American Association of Hospital Dentists, the Academy of Dentistry for the Handicapped, and the American Society for Geriatric Dentistry*, 38(1), pp. 58–59. doi: 10.1111/scd.12267.
  55. Wahab, P. U. A. et al. (2018) 'Scalpel Versus Diathermy in Wound Healing After Mucosal Incisions: A Split-Mouth Study', *Journal of oral and maxillofacial surgery: official journal of the American Association of Oral and Maxillofacial Surgeons*, 76(6), pp. 1160–1164. doi: 10.1016/j.joms.2017.12.020.
  56. Watters, A. L., Epstein, J. B. and Agulnik, M. (2011) 'Oral complications of targeted cancer therapies: a narrative literature review', *Oral oncology*, 47(6), pp. 441–448. doi: 10.1016/j.oraloncology.2011.03.028.

### SARCOIDOSIS IS A FORM OF CANCER



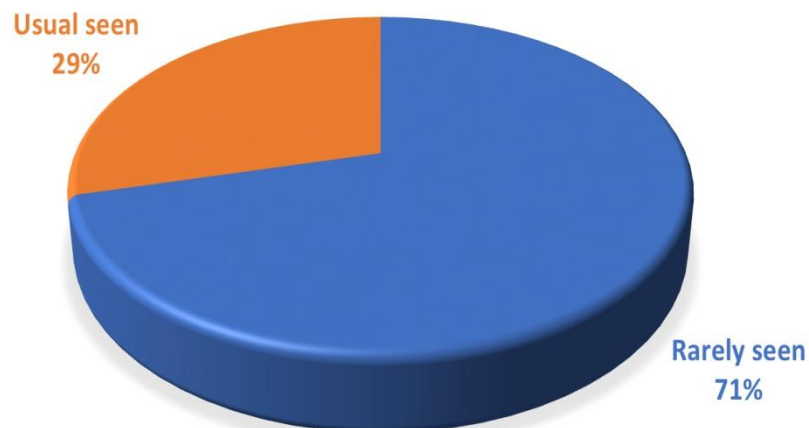
**Graph 1: The first question was “Sarcoidosis is a form of cancer”. graph 1 represents the answer for the question regarding the nature of sarcoidosis. In this study majority of the participants thought it is a form of cancer, mainly because it appears as a lump or growth but in sarcoidosis the lump consists of inflammatory cells, where in cancer it’s a mass of abnormal growth of cells in that particular region. 74% of the participants answered that sarcoidosis is a form of cancer and the rest said sarcoidosis was a type or form of cancer.**

## SARCOIDOSIS A INHERITED DISEASES



**Graph 2:** The second question was “Sarcoidosis is an inherited disease”. Sarcoidosis can be inherited. Sarcoidosis is an immunological disorder. It is believed that it occurs in people with genetic predisposition to sarcoidosis. an individual with inherited sarcoidosis may or maynot be affected by sarcoidosis. This depends on the individual's exposure to a tigger which activates the inherited gene. In this study 78% of the participants answered right by answering it as an inherited disease. And 22% of the participants answered it wrong. And their explanation was that they thought it was a transmitting disease. It is represented in Graph 2.

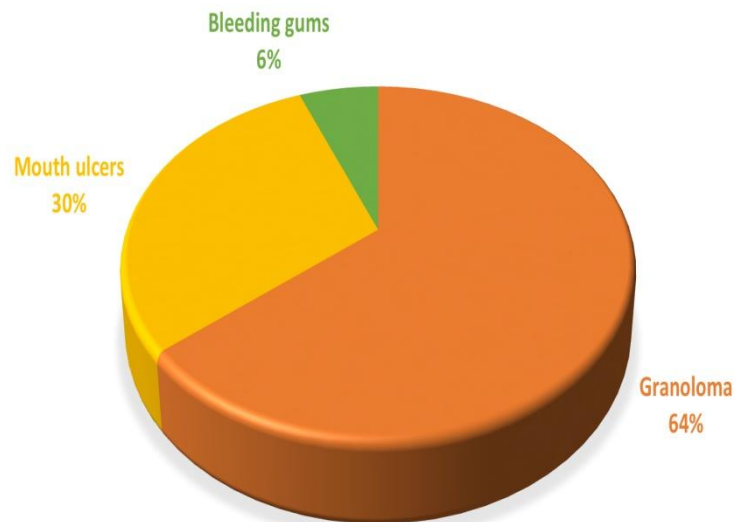
## ORAL MANIFESTATION OF SARCOIDOSIS



**Graph 3:** The third question was “Oral manifestations of sarcoidosis are” the multiple choice answers were rarely seen or Usually seen. Sarcoidosis is a common disease but oral manifestation of sarcoidosis is not very common and the oral lesion may be the initial manifestation of the diseases. In this study 71 % participants answered the question right about the question on incidence of oral sarcoidosis. Graph 3 represents the answer for the question regarding the oral manifestation of sarcoidosis.

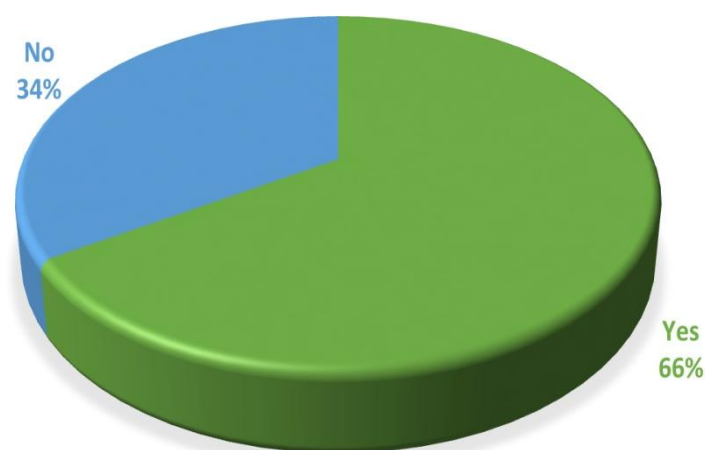


### CHARACTERISTIC FEATURE OF SARCOIDOSIS

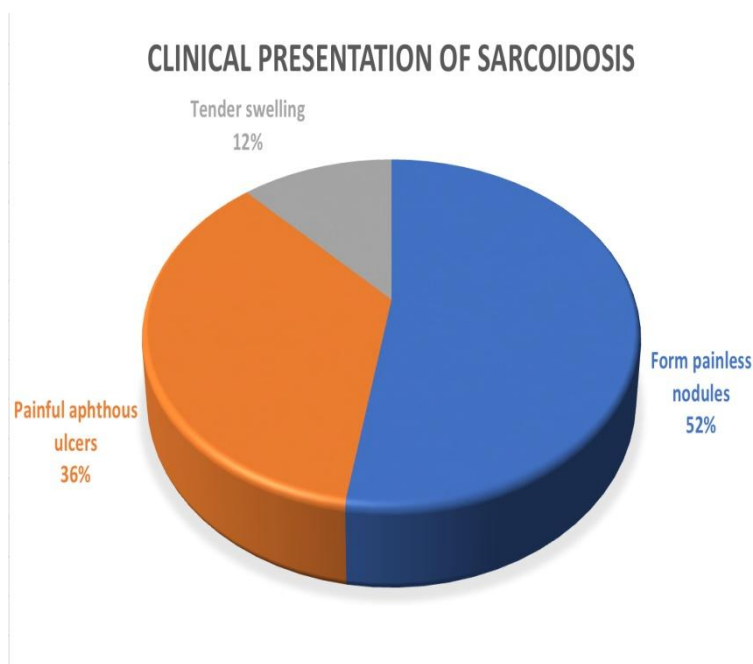


**Graph 4:** The fourth question was “Characteristic feature of Sarcoidosis” and the options given were Granuloma, Mouth ulcers, Bleeding gums. Sarcoidosis indirectly causes tooth mobility by causing vertical bone loss in the jaws. In this study 66% of the participants answered the question right by saying sarcoidosis causes tooth mobility and the rest 34% answered the question wrong. Graph 4 represents the answer for the question regarding clinical feature of sarcoidosis

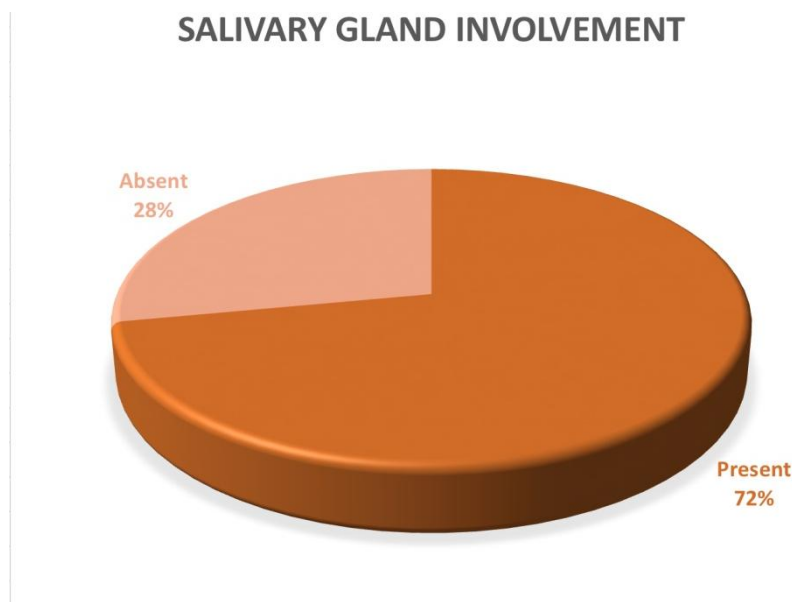
### SARCOIDOSIS CAUSES TOOTH MOBILITY



**Graph 5:** The fifth question was “Sarcoidosis causes tooth mobility”.. Though the exact development of granuloma is not clear. A mix of epithelioid cells and multinucleated giant cells surrounded by lymphocytes can be seen in a well developed granuloma. The surrounding cells mainly consist of CD4 T helper cells, CD8 T helper cells and B cells. In this study 64% of the participants answered granuloma followed by 30% answered mouth ulcers. Graph 5 represents the answer for the question regarding sarcoidosis and tooth mobility

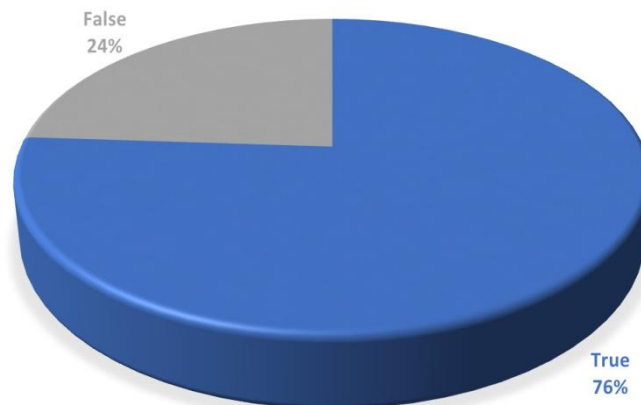


**Graph 6:** The sixth question is “Clinical representation of sarcoidosis” and the options given were Firm painless nodules, Painful nodules, Tender swellings. Granuloma are painless but they disturb the normal functioning and structure of the organ it is present in. Ulcers in oral mucosa is present but not very common, these ulcers can be tender on palpation. Tender swellings are not seen in sarcoidosis. In this study 64% of the participants said the characteristic feature of sarcoidosis is painless nodules and 30% of individuals answered mouth ulcers and the rest said bleeding gums. Graph 6 represents the answer for the question regarding the clinical presentation of sarcoidosis.



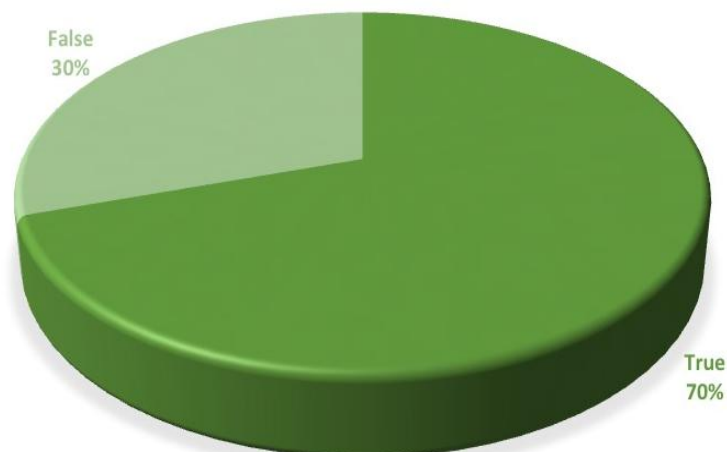
**Graph 7:** Salivary glands are involved in sarcoidosis. Sarcoidosis in salivary glands is present as painless swellings, with the enlargement being persistent and xerostomia. In case of parotid gland involvement there is persistent painless swelling with rise in body temperature indicating fever. In this study 72% of the individuals answered that salivary glands are involved in sarcoidosis. 28% of the participants answered there is no salivary involvement. graph 7 represents the answer for the question regarding salivary gland involvement.

### BUCCAL SARCOIDOSIS IS NOT ASSOCIATED WITH SEVERE CASES




**Graph 8:** The eighth question was “Buccal sarcoidosis is not associated with severe cases”. Buccal sarcoidosis is not associated with severe cases. Buccal sarcoidosis a secondary feature of sarcoidosis. Presence of ulcerative lesions can be seen in the buccal mucosa. In this study 76% of the students said that buccal sarcoidosis is not associated with the severity of the diseases. And the rest 24% said it is associated. The mouth ulcers may look severe and the patient may experience severe pain and discomfort in buccal mucosa during talking or eating but they are not associated with the severe cases.

### ANGULAR CHEILITIS AND LINGUAL PLACITA



**Graph 9:** Nineth question was “Other manifestations of sarcoidosis include angular cheilitis and lingual placita”. Angular cheilitis and lingual placita are other oral manifestations of sarcoidosis. It is cracks and inflammation seen in the one or both the corners of lips. It is mainly caused due to buildup of microorganisms in the corners of the lips. Patients may complain of painful sores in either the corners or any one corner of the lip with burning sensation. Lingual placita are deep grooves on the dorsum of the tongue, sometimes occurring on the sides of the tongue too. In this study 70 % of the students said true, there by saying angular cheilitis and lingual placita are other oral manifestations of sarcoidosis. graph 9 represents the answer regarding oral manifestation of sarcoidosis



**Graph 10: The last question was whether Anti-malarial drugs are used in treating sarcoidosis. The correct answer is Anti-malarial drugs are used in treating sarcoidosis. Anti-malarial drugs include Hydroxychloroquine and Chloroquine is used in treating sarcoidosis. These drugs are used to prevent the release of chemicals that promote the inflammation process. In this study 78% of the participants answered anti-malarial drugs are used in treating sarcoidosis and the rest 22% answered that the anti-malarial drugs are not used to treat sarcoidosis.**