
Modified Gallego's Stain as Differential Stain for The Assessment of Dentin Morphology

CHARANYA SURESH¹, DR. ABILASHA RAMASUBRAMANIAN^{2*}

¹Saveetha Dental College, Saveetha Institute of Medical and Technical Sciences, Saveetha University, Chennai 600077, Tamil Nadu, India

²Reader, Department of oral pathology, Saveetha Dental College, Saveetha Institute of Medical and Technical Sciences, Saveetha University, Chennai 600077, Tamil Nadu, India

*Corresponding Author

Email: 151801072.sdc@saveetha.com¹, abilasha@saveetha.com²

Abstract: Modified Gallego's stain is a variant of Lille's stain that uses basic reagents like hematoxylin, carbol fuchsin and aniline blue. The study aimed at assessing the efficiency of Modified Gallego's stain in differentially staining dentin. To check the efficiency of modified Gallego's stain in differentiating and understanding the histological morphology of dentin, 6 natural teeth (2 posterior teeth and 4 anterior teeth) were chosen using modified Gallego's stain. Unlike the H & E stain that vaguely stains oral tissues, modified gallego's stain specifically and differentially stains hard tissue components, especially dentin, which enables easier assessment of dentin morphology. Modified Gallego's stain is one such stain which not only stains the decalcified sections but also differentially stains the hard tissues of the tooth. When stained with Modified Gallego's stain, these components were stained with different colours. Hence, it was concluded that Modified Gallego's stain can be used as a potential tool to stain the hard tissue components of decalcified and ground sections of teeth and can be considered to be used as one of the differential stains for hard tissues especially dentin and as an adjunct to routine H&E.

Keywords: Dentin; morphology; modified gallego's stain, hard tissues

INTRODUCTION

Histology is the microscopic study of animal and plant cells and tissues through staining and sectioning and examining them under a microscope (electron or light microscope). There are various methods used to study tissue characteristics and microscopic structures of the cells. Histological studies are used in forensic investigations, autopsy, diagnosis and in education. In addition, histology is used extensively in medicine especially in the study of diseased tissues to aid treatment (Avinash *et al.*, 2016).

Histological staining is a series of technique processes undertaken in the preparation of sample tissues by staining using histological stains to aid in the microscope study (Coriglione, 1962). The process of histological staining takes five key stages which involve; fixation, processing, embedding, sectioning and staining (Afroze *et al.*, 2018). Great changes have been done on techniques used for histological staining through chemical, molecular biology assays and immunological techniques collectively and have facilitated greatly in the study of organs and tissues (Avinash *et al.*, 2016). Early histologists used the readily available chemicals to prepare tissues for microscopic studies; these laboratory chemicals were potassium dichromate, alcohol and the mercuric chloride to harden cellular tissues. Staining techniques used were carmine, silver nitrate, Giemsa, Trichrome Stains, Gram Stain and Hematoxylin among others. (Mudhiraj, Vanje and Reddy, 2017)

Modified Gallego's stain is a variant of Lille's stain that uses basic reagents like hematoxylin, carbol fuchsin and aniline blue (Dhouskar *et al.*, 2019). The purpose of the stain is differential staining of the hard tissues in the tooth and other pathological lesions. This study is done to obtain a clearer understanding of the histological picture of the hard tissue, especially dentin. Ground sections, decalcified sections and soft tissues were selected for the staining procedure. The sections were stained with H&E followed by Gallego's stain to compare the staining character of dentin (Satheesan *et al.*, 2016). Our extensive slide collection has enabled us to publish numerous articles in the past 3 years (Krishnan *et al.*, 2018; Padavala and Sukumaran, 2018; Sujatha *et al.*, 2018, 2019; Abitha and Santhanam, 2019; Alexander *et al.*, 2019; Jayaraj *et al.*, 2019; Sridharan *et al.*, 2019). Based on these inspirations, we conducted the present study to evaluate the efficacy of Modified Gallego's stain as differential stain for the assessment of dentin morphology. Our team has rich experience in research and we have collaborated with numerous authors over various topics in the past decade (Deogade, Gupta and Ariga, 2018; Ezhilarasan, 2018; Ezhilarasan, Sokal and Najimi, 2018; Jeevanandan and Govindaraju, 2018; J *et al.*, 2018; Menon *et al.*, 2018; Prabakar *et al.*, 2018; Rajeshkumar *et al.*, 2018, 2019; Vishnu Prasad *et al.*, 2018; Wahab *et al.*, 2018; Dua *et al.*, 2019; Duraisamy *et al.*, 2019; Ezhilarasan, Apoorva and Ashok Vardhan, 2019;

Gheena and Ezhilarasan, 2019; Malli Sureshababu *et al.*, 2019; Mehta *et al.*, 2019; Panchal, Jeevanandan and Subramanian, 2019; Rajendran *et al.*, 2019; Ramakrishnan, Dhanalakshmi and Subramanian, 2019; Sharma *et al.*, 2019; Varghese, Ramesh and Veeraiyan, 2019; Gomathi *et al.*, 2020; Samuel, Acharya and Rao, 2020)

MATERIALS AND METHODS

To check the efficiency of modified Gallego's stain in differentiating and understanding the histological morphology of dentin, 6 natural teeth (2 posterior teeth and 4 anterior teeth) were chosen. The following samples were selected for the study :

1. Ground sections of 20 posterior teeth
 2. Decalcified sections of 20 anterior teeth as shown in figure 1
- 50% of the sample sections (ground section of 10 posterior teeth and decalcified section of 10 anterior teeth) were stained with H&E and the remaining 50% of the sample sections (ground section of 10 posterior teeth and decalcified sections of 10 anterior teeth) were stained with Modified Gallego's by using the following technique as shown figure 2 :
1. Deparaffinize the sections
 2. Stain in hematoxylin for 8-12 minutes
 3. Rinse in distilled water
 4. Stain in mordant for 2 minutes (Mix 200ml of distilled water in 1.5 ml. of concentrated nitric acid with 1 ml. of 40 per cent formaldehyde and 1.5 ml. of U.S.P. iron chloride). Rinse in distilled water.
 5. Stain with 3 ml of carbol fuschin in 50 ml of 0.2 percent acetic acid and rinse in distilled water.
 6. Wash in mordant for 1-2 minutes
 7. Stain with 0.01 per cent aniline blue in saturated picric acid solution for 30 seconds
 8. Dehydrate and clear with xylene, and mount in DPX mounting media.



Fig.1: Figure showing the decalcification procedure




Fig.2: Figure showing staining procedure

RESULTS

All the above samples were subjected to the staining procedure discussed above and the results were studied. Interpretation was done under microscope and following observations were made. The histological morphology of dentin after H&E staining was compared with modified Gallego's staining.

Table 1: Table comparing the modified Gallego's staining of dentin with the standard H& E staining of tooth hard tissues to interpret the histological morphology and parts of dentin

Sample section	Color obtained after staining the with modified Gallego's
Dentin	Dark blue
Dentinal tubule	Dark blue striations
Coronal dentin	Light blue
Interglobular dentin	Violet-blue



Fig.3: Figure showing dark blue color-stained dentin

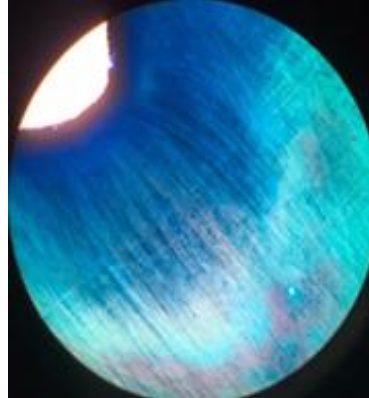


Fig.4: Figure showing dentinal tubules as dark blue color striations

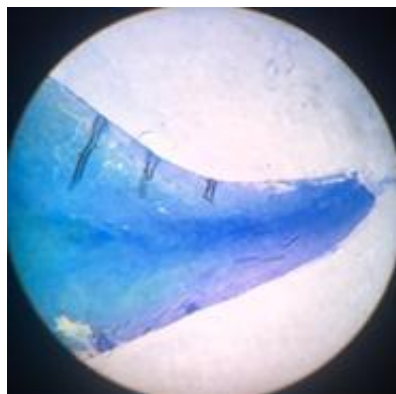


Fig.5: Figure showing light blue color-stained coronal dentin

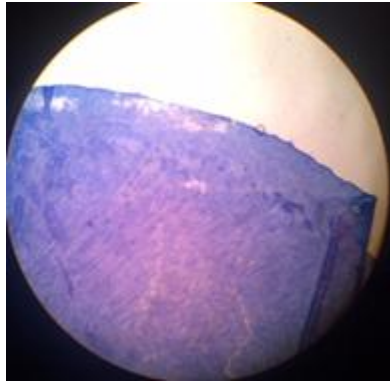


Fig.6: Figure showing violet -blue color stained interglobular dentin

DISCUSSION

The present study was done to differentiate between these hard tissues and enable easier assessment of dentin. Various special stains such as von Kossa, Alizarin red for the bone, picro thionin for dentin, toluidine blue and Alcian blue for cementum are available, but the use of single histochemical stain that differentiates between the hard tissues of tooth is rare.

H&E is the most widely used histological stain. Apart from this routine H&E, there are alternative staining procedures which aid in highlighting the specific features of the tissues that are not appreciated with routine H&E. Therefore these staining techniques can be used as an adjunct for predicting the histopathological diagnosis

As a way of improving these histological staining techniques, several stains have been modified and combined with various other stains to improve their effectiveness (Levey, 1956). Among these techniques, Modified Gallego's stain is one that has been derived from the modification of Lille's stain which uses basic reagents like haematoxylin, carbol fuschin and aniline blue

Unlike the H & E stain that vaguely stains oral tissues, modified gallego's stain specifically and differentially stains hard tissue components, especially dentin, which enables easier assessment of dentin morphology. Modified Gallego's stain is one such stain which not only stains the decalcified sections but also differentially stains the hard tissues of the tooth. When stained with Modified Gallego's stain, these components were stained with different colours as follows (Sandhya *et al.*, 2014).

It stains dentin in dark blue color as shown in figure 4, the dentinal tubules were observed as dark blue striations as shown in figure 4 while the coronal dentin is stained in light blue color as shown in figure 5 and interglobular dentin looks violet blue after staining with modified Gallego's stain as shown in figure 6 (Kunche *et al.*, 2017).

This staining procedure is technique sensitive and the intensity of the colour in the stained sections decreases as the time duration increases and becomes difficult to differentiate between the dentin at different parts (*Comparison of Verdeluz Orange G and Modified Gallego Stains*, 2017).

In the study conducted by Gallego (1954), tooth and bone (decalcified, ground, frozen) sections were stained, the results were as follows, dentine and bone stained green, and cementum stained red. Various stains differentiate between hard tissue components. But the use of histochemical stain that differentiates between various hard tissues components are uncommon in the literature especially in dental literature (Brown and Hopps, 1973). Also usually the special stains are performed in soft tissue and decalcified tissue but the study of staining ground sections of hard tissue have not been reported in histo-pathological literature, hence this study stands significant. Our institution is passionate about high quality evidence based research and has excelled in various fields ((Pc, Marimuthu and Devadoss, 2018; Ramesh *et al.*, 2018; Vijayashree Priyadharsini, Smiline Girija and Paramasivam, 2018; Ezhilarasan, Apoorva and Ashok Vardhan, 2019; Ramadurai *et al.*, 2019; Sridharan *et al.*, 2019; Vijayashree Priyadharsini, 2019; Chandrasekar *et al.*, 2020; Mathew *et al.*, 2020; R *et al.*, 2020; Samuel, 2021)

CONCLUSION

Modified Gallego's stain can be used as a potential tool to stain the hard tissue components of decalcified and ground sections of teeth. Hence, this stain can be used as one of the differential stains for hard tissues of the teeth, especially the dentin and as an adjunct to routine H&E.

ACKNOWLEDGEMENT

The authors are grateful to Saveetha Dental College for providing a platform to express our knowledge.

CONFLICT OF INTEREST

The authors declare no conflict of interest.

REFERENCE

1. Abitha, T. and Santhanam, A. (2019) 'Correlation between bizygomatic and maxillary central incisor width for gender identification', *Brazilian Dental Science*, 22(4), pp. 458–466.
2. Afroze, S. N. et al. (2018) 'Demystifying the nature of hard tissues in odontogenic tumors using Modified Gallego's stain: A preliminary study', *Journal of oral and maxillofacial pathology: JOMFP*, 22(3), p. 448.
3. Alexander, A. J. et al. (2019) 'Quantitative analysis of copper levels in areca nut plantation area - A role in increasing prevalence of oral submucous fibrosis: An study', *Indian journal of dental research: official publication of Indian Society for Dental Research*, 30(2), pp. 261–266.
4. Avinash, T. et al. (2016) 'Juvenile cemento-ossifying fibroma: a case report using modified Gallego's staining', *International Journal of*. Available at: https://www.researchgate.net/profile/Sandhya_Tamgadge/publication/292670770_Juvenile_cemento-ossifying_fibroma_a_case_report_using_modified_Gallego's_staining/links/56e9855b08aec8bc0780fbf6.pdf.
5. Brown, R. C. and Hopps, H. C. (1973) 'Staining of bacteria in tissue sections: a reliable gram stain method', *American journal of clinical pathology*, 60(2), pp. 234–240.
6. Chandrasekar, R. et al. (2020) 'Development and validation of a formula for objective assessment of cervical vertebral bone age', *Progress in orthodontics*, 21(1), p. 38.
7. Comparison of Verdeluz Orange G and Modified Gallego Stains (2017). Taylor & Francis.
8. Coriglione, G. (1962) '[On the value and use in ocular histopathology of the modified Cajal-Gallego method]', *Minerva oftalmologica*, 4, p. 96.
9. Deogade, S., Gupta, P. and Ariga, P. (2018) 'Effect of monopoly-coating agent on the surface roughness of a tissue conditioner subjected to cleansing and disinfection: A Contact Profilometric In vitro study', *Contemporary Clinical Dentistry*, p. 122. doi: 10.4103/ccd.ccd_112_18.
10. Dhouskar, S. et al. (2019) 'Comparison of Hematoxylin and Eosin Stain with Modified Gallego's Stain for Differentiating Mineralized Components in Ossifying Fibroma, Cemento-ossifying Fibroma, and Cementifying Fibroma', *Journal of microscopy and ultrastructure*, 7(3), pp. 124–129.
11. Dua, K. et al. (2019) 'The potential of siRNA based drug delivery in respiratory disorders: Recent advances and progress', *Drug development research*, 80(6), pp. 714–730.
12. Duraisamy, R. et al. (2019) 'Compatibility of Nonoriginal Abutments With Implants: Evaluation of Microgap at the Implant-Abutment Interface, With Original and Nonoriginal Abutments', *Implant dentistry*, 28(3), pp. 289–295.
13. Ezhilarasan, D. (2018) 'Oxidative stress is bane in chronic liver diseases: Clinical and experimental perspective', *Arab journal of gastroenterology: the official publication of the Pan-Arab Association of Gastroenterology*, 19(2), pp. 56–64.
14. Ezhilarasan, D., Apoorva, V. S. and Ashok Vardhan, N. (2019) 'Syzygium cumini extract induced reactive oxygen species-mediated apoptosis in human oral squamous carcinoma cells', *Journal of oral pathology & medicine: official publication of the International Association of Oral Pathologists and the American Academy of Oral Pathology*, 48(2), pp. 115–121.
15. Ezhilarasan, D., Sokal, E. and Najimi, M. (2018) 'Hepatic fibrosis: It is time to go with hepatic stellate cell-specific therapeutic targets', *Hepatobiliary & pancreatic diseases international: HBPD INT*, 17(3), pp. 192–197.
16. Gheena, S. and Ezhilarasan, D. (2019) 'Syringic acid triggers reactive oxygen species-mediated cytotoxicity in HepG2 cells', *Human & experimental toxicology*, 38(6), pp. 694–702.
17. Gomathi, A. C. et al. (2020) 'Anticancer activity of silver nanoparticles synthesized using aqueous fruit shell extract of Tamarindus indica on MCF-7 human breast cancer cell line', *Journal of Drug Delivery Science and Technology*, p. 101376. doi: 10.1016/j.jddst.2019.101376.
18. Jayaraj, G. et al. (2019) 'Malignant Glomus tumour of the head and neck—A review', *Journal of Oral and Maxillofacial Surgery, Medicine, and Pathology*, 31(3), pp. 228–230.
19. Jeevanandan, G. and Govindaraju, L. (2018) 'Clinical comparison of Kedo-S paediatric rotary files vs manual instrumentation for root canal preparation in primary molars: a double blinded randomised clinical trial', *European Archives of Paediatric Dentistry*, pp. 273–278. doi: 10.1007/s40368-018-0356-6.
20. J, P. C. et al. (2018) 'Prevalence and measurement of anterior loop of the mandibular canal using CBCT: A cross sectional study', *Clinical implant dentistry and related research*, 20(4), pp. 531–534.
21. Krishnan, R. P. et al. (2018) 'Surgical Specimen Handover from Operation Theater to Laboratory: A Survey', *Annals of maxillofacial surgery*, 8(2), pp. 234–238.
22. Kunche, A. et al. (2017) 'Comparison of verdeluz orange G and modified Gallego stains', *Biotechnic & histochemistry: official publication of the Biological Stain Commission*, 92(8), pp. 547–551.

23. Levey, R. J. (1956) 'A modified Gallego's iron fuschin stain as a differential stain for cementum', *Journal of dental research*, 35(3), pp. 491–493.
24. Malli Sureshbabu, N. et al. (2019) 'Concentrated Growth Factors as an Ingenious Biomaterial in Regeneration of Bony Defects after Periapical Surgery: A Report of Two Cases', *Case reports in dentistry*, 2019, p. 7046203.
25. Mathew, M. G. et al. (2020) 'Evaluation of adhesion of Streptococcus mutans, plaque accumulation on zirconia and stainless steel crowns, and surrounding gingival inflammation in primary molars: Randomized controlled trial', *Clinical oral investigations*, pp. 1–6.
26. Mehta, M. et al. (2019) 'Oligonucleotide therapy: An emerging focus area for drug delivery in chronic inflammatory respiratory diseases', *Chemico-biological interactions*, 308, pp. 206–215.
27. Menon, S. et al. (2018) 'Selenium nanoparticles: A potent chemotherapeutic agent and an elucidation of its mechanism', *Colloids and Surfaces B: Biointerfaces*, pp. 280–292. doi: 10.1016/j.colsurfb.2018.06.006.
28. Mudhiraj, P. V., Vanje, M. M. and Reddy, B. N. (2017) 'Nature of hard tissues in oral pathological lesions—Using modified Gallego's stain', *Journal of Clinical*. Available at: <https://www.ncbi.nlm.nih.gov/pmc/articles/pmc5449905/>.
29. Padavala, S. and Sukumaran, G. (2018) 'Molar Incisor Hypomineralization and Its Prevalence', *Contemporary clinical dentistry*, 9(Suppl 2), pp. S246–S250.
30. Panchal, V., Jeevanandan, G. and Subramanian, E. M. G. (2019) 'Comparison of post-operative pain after root canal instrumentation with hand K-files, H-files and rotary Kedo-S files in primary teeth: a randomised clinical trial', *European archives of paediatric dentistry: official journal of the European Academy of Paediatric Dentistry*, 20(5), pp. 467–472.
31. Pc, J., Marimuthu, T. and Devadoss, P. (2018) 'Prevalence and measurement of anterior loop of the mandibular canal using CBCT: A cross sectional study', *Clinical implant dentistry and related research*. Available at: <https://europepmc.org/article/med/29624863>.
32. Prabakar, J. et al. (2018) 'Comparative Evaluation of Retention, Cariostatic Effect and Discoloration of Conventional and Hydrophilic Sealants - A Single Blinded Randomized Split Mouth Clinical Trial', *Contemporary clinical dentistry*, 9(Suppl 2), pp. S233–S239.
33. Rajendran, R. et al. (2019) 'Comparative Evaluation of Remineralizing Potential of a Paste Containing Bioactive Glass and a Topical Cream Containing Casein Phosphopeptide-Amorphous Calcium Phosphate: An in Vitro Study', *Pesquisa Brasileira em Odontopediatria e Clínica Integrada*, pp. 1–10. doi: 10.4034/pboci.2019.191.61.
34. Rajeshkumar, S. et al. (2018) 'Biosynthesis of zinc oxide nanoparticles using *Mangifera indica* leaves and evaluation of their antioxidant and cytotoxic properties in lung cancer (A549) cells', *Enzyme and microbial technology*, 117, pp. 91–95.
35. Rajeshkumar, S. et al. (2019) 'Antibacterial and antioxidant potential of biosynthesized copper nanoparticles mediated through *Cissus arotiana* plant extract', *Journal of photochemistry and photobiology. B, Biology*, 197, p. 111531.
36. Ramadurai, N. et al. (2019) 'Effectiveness of 2% Articaine as an anesthetic agent in children: randomized controlled trial', *Clinical oral investigations*, 23(9), pp. 3543–3550.
37. Ramakrishnan, M., Dhanalakshmi, R. and Subramanian, E. M. G. (2019) 'Survival rate of different fixed posterior space maintainers used in Paediatric Dentistry - A systematic review', *The Saudi dental journal*, 31(2), pp. 165–172.
38. Ramesh, A. et al. (2018) 'Comparative estimation of sulfiredoxin levels between chronic periodontitis and healthy patients - A case-control study', *Journal of periodontology*, 89(10), pp. 1241–1248.
39. R, H. et al. (2020) 'CYP2 C9 polymorphism among patients with oral squamous cell carcinoma and its role in altering the metabolism of benzo[a]pyrene', *Oral Surgery, Oral Medicine, Oral Pathology and Oral Radiology*, pp. 306–312. doi: 10.1016/j.oooo.2020.06.021.
40. Samuel, S. R. (2021) 'Can 5-year-olds sensibly self-report the impact of developmental enamel defects on their quality of life?', *International journal of paediatric dentistry / the British Paedodontic Society [and] the International Association of Dentistry for Children*, 31(2), pp. 285–286.
41. Samuel, S. R., Acharya, S. and Rao, J. C. (2020) 'School Interventions-based Prevention of Early-Childhood Caries among 3-5-year-old children from very low socioeconomic status: Two-year randomized trial', *Journal of public health dentistry*, 80(1), pp. 51–60.
42. Sandhya, T. et al. (2014) 'Modified Gallego's stain as differential stain for oral hard tissues in oral pathology: a preliminary report', *Int J Oral Maxillofac Pathol*, 5, pp. 2–6.
43. Satheesan, E. et al. (2016) 'Histopathological and Radiographic Analysis of Dental Follicle of Impacted Teeth Using Modified Gallego's Stain', *Journal of clinical and diagnostic research: JCDR*, 10(5), pp. ZC106–11.
44. Sharma, P. et al. (2019) 'Emerging trends in the novel drug delivery approaches for the treatment of lung cancer', *Chemico-biological interactions*, 309, p. 108720.

45. Sridharan, G. et al. (2019) 'Evaluation of salivary metabolomics in oral leukoplakia and oral squamous cell carcinoma', *Journal of oral pathology & medicine: official publication of the International Association of Oral Pathologists and the American Academy of Oral Pathology*, 48(4), pp. 299–306.
46. Sujatha, G. et al. (2018) 'Knowledge and Attitude among Senior Dental Students on Forensic Dentistry: A Survey', *World Journal of Dentistry*, 9(3), pp. 187–191.
47. Sujatha, G. et al. (2019) 'Determination of reliability and practicality of saliva as a genetic source in forensic investigation by analyzing DNA yield and success rates: A systematic review', *Journal of Oral and Maxillofacial Surgery, Medicine, and Pathology*, 31(3), pp. 218–227.
48. Varghese, S. S., Ramesh, A. and Veeraiyan, D. N. (2019) 'Blended Module-Based Teaching in Biostatistics and Research Methodology: A Retrospective Study with Postgraduate Dental Students', *Journal of dental education*, 83(4), pp. 445–450.
49. Vijayashree Priyadharsini, J. (2019) 'In silico validation of the non-antibiotic drugs acetaminophen and ibuprofen as antibacterial agents against red complex pathogens', *Journal of periodontology*, 90(12), pp. 1441–1448.
50. Vijayashree Priyadharsini, J., Smiline Girija, A. S. and Paramasivam, A. (2018) 'In silico analysis of virulence genes in an emerging dental pathogen *A. baumannii* and related species', *Archives of oral biology*, 94, pp. 93–98.
51. Vishnu Prasad, S. et al. (2018) 'Report on oral health status and treatment needs of 5-15 years old children with sensory deficits in Chennai, India', *Special care in dentistry: official publication of the American Association of Hospital Dentists, the Academy of Dentistry for the Handicapped, and the American Society for Geriatric Dentistry*, 38(1), pp. 58–59.
52. Wahab, P. U. A. et al. (2018) 'Scalpel Versus Diathermy in Wound Healing After Mucosal Incisions: A Split-Mouth Study', *Journal of oral and maxillofacial surgery: official journal of the American Association of Oral and Maxillofacial Surgeons*, 76(6), pp. 1160–1164.