

---

## Immune Mediated Sub-Epithelial Blistering Disorders: Case Series

---

ABHINAYA LM<sup>1</sup>, MUTHUKRISHNAN ARVIND<sup>2\*</sup>

<sup>1</sup>Department of Oral Medicine and Radiology and Special Care Dentistry, Saveetha Dental College, Saveetha Institute of Medical and Technical Sciences, Saveetha University, Chennai-77

<sup>2</sup>Professor and Head, Department of Oral Medicine and Radiology and Special Care Dentistry, Saveetha Dental College, Saveetha Institute of Medical and Technical Sciences, Saveetha University, Chennai-77

\*Corresponding Author

Email: 151910002.sdc@saveetha.com<sup>1</sup>, arvindm@saveetha.com<sup>2</sup>

---

**Abstract:** Subepithelial vesiculobullous conditions are chronic autoimmune disorders that arise from reactions directed against components of the hemidesmosomes or basement membrane zones (BMZ) of stratified squamous epithelium to which the term immune-mediated subepithelial blistering diseases (IMSEBD) has been given. Subepithelial vesiculobullous disorders present as blisters and erosions, and diagnosis are confirmed by biopsy examination with immunostaining. The sub epithelial disorders include Mucous membrane pemphigoid, Angina bullosa haemorrhagica, Linear IgA disease, Bullous pemphigoid, Erythema multiforme. These disorders pose a challenge to the oral physician due to clinical and histological severity in a variety of disorders. Early diagnosis and appropriate treatment for oral lesions can possibly prevent further cutaneous involvement as in 70% of cases oral lesions precede that of cutaneous lesions. Accurate and definitive diagnosis is done by immunofluorescence, direct and indirect. This article comprises of case series of immune mediated subepithelial blistering disorders.

**Keywords:** Erythema multiforme, Mucous membrane pemphigoid, Subepithelial blistering disorders.

---

### INTRODUCTION

Immune-mediated subepithelial blistering diseases includes a variety of subepithelial vesiculobullous disorders such as bullous pemphigoid, pemphigoid gestationis, mucous membrane pemphigoid (MMP), dermatitis herpetiformis, and linear IgA disease. Group of autoimmune vesiculobullous disorders present under a limited manifestation related to a localised immune response, such as contact hypersensitivity while others represent more widespread systemic disease with distinct oral manifestations. The underlying pathobiological mechanisms are varied and involve the innate and acquired immune systems. Oral lesions often precede with that of the other areas in the body or sometimes may present as a sole manifestation of the disease. Bullous pemphigoid is a non scarring subepidermal blistering disease primarily of the skin with occasional mucous membrane involvement. When mucous membrane lesions occur in BP, they are often transient and trivial and usually involve only the oropharynx (Korman, 1993) when comparing to that of cicatricial pemphigoid lesions that predominantly involve the mucous membranes, only occasionally involve the skin, and are very likely to scar (Mutasim, Pelc and Anhalt, 1993). MMP is an autoimmune, chronic inflammatory subepithelial blistering disorder that primarily affects the mucous membranes. It is a rare disease, with an incidence of 2–10 cases out of 100,000 individuals (Dear, Lilitkarntakul and Webb, 2006; Xu *et al.*, 2013). Linear immunoglobulin A (IgA) disease is a rare chronic autoimmune disorder, which presents with vesicles and bullae formation affecting both the skin and the mucous membrane, with a characteristic immunofluorescence finding of homogeneous linear deposits of IgA in the cutaneous basement membrane zone (Angiero *et al.*, 2007; Tsai *et al.*, 2010). Erythema multiforme is defined as an acute, self limiting mucocutaneous hypersensitivity reaction that presents with varied clinical severity and appearance. It is often associated with prodromal symptoms including fever, malaise and sore throat occurring weeks prior to the lesion. The lesions are divided into Major and minor forms and 50% of the cases are often associated with medications or recent infection such as HSV or mycoplasma infection. Benign subepithelial oral mucosal blisters filled with blood that are not related to any systemic disorder or hemostatic effect is termed as Angina bullosa haemorrhagica (ABH). ABH commonly seen in soft palate, buccal mucosa, lip and lateral surface of tongue. One of the chief complaint by the patient would be recurrence and remission of the bullae or pain on consumption of spicy food (Giuliani *et al.*, 2002; Singh *et al.*, 2013).

Diagnosis of subepithelial blistering diseases is based on the presence of the appropriate clinical, histological, immunopathological, and immunochemical features. Management of lesions if not self limiting often include systemic management using corticosteroid therapy starting with topical or intralesional followed by systemic therapy and consecutively tapering of the systemic dosage once the lesion is under control. Since many of these

conditions are chronic in nature and often require a long term therapy. Our team has rich experience in research and we have collaborated with numerous authors over various topics in the past decade (Deogade, Gupta and Ariga, 2018; Ezhilarasan, 2018; Ezhilarasan, Sokal and Najimi, 2018; Jeevanandan and Govindaraju, 2018; J *et al.*, 2018; Menon *et al.*, 2018; Prabakar *et al.*, 2018; Rajeshkumar *et al.*, 2018, 2019; Vishnu Prasad *et al.*, 2018; Wahab *et al.*, 2018; Dua *et al.*, 2019; Duraisamy *et al.*, 2019; Ezhilarasan, Apoorva and Ashok Vardhan, 2019; Gheena and Ezhilarasan, 2019; Malli Sureshbabu *et al.*, 2019; Mehta *et al.*, 2019; Panchal, Jeevanandan and Subramanian, 2019; Rajendran *et al.*, 2019; Ramakrishnan, Dhanalakshmi and Subramanian, 2019; Sharma *et al.*, 2019; Varghese, Ramesh and Veeraiyan, 2019; Gomathi *et al.*, 2020; Samuel, Acharya and Rao, 2020). Our recent research portfolio includes numerous articles in reputed journals (Santosh R. Patil *et al.*, 2018; S. R. Patil *et al.*, 2018; Subramaniam and Muthukrishnan, 2019; Vadivel *et al.*, 2019; Patil *et al.*, 2020). Based on this experience we planned to pursue Immune mediated sub-epithelial blistering disorders: Case series.

Case series of mucous membrane pemphigoid, bullous pemphigoid, Erythema multiforme and Herpes induced erythema multiforme are presented.

### Case 1

A 32 year old female patient reported with a complaint of blisters in mouth which subsequently ruptured into painful ulcers and eye discomfort for the past six months. This was accompanied by pain and burning sensation on consumption of hot and spicy foods. Patient did not present with any previous history of systemic disease and ongoing medications. There was no related family history and personal history which were contributory.

Extra oral examination revealed ocular involvement but absence of cutaneous and genital lesions. Patient presented with erythema in the sclera and discomfort in both her eyes. Intra oral examination revealed generalised gingival erythema. Single localized ulcers with pseudomembranous floor and surrounding area of erythema were seen in the upper labial mucosa in relation to 21,14 and in attached gingiva in relation to 32. Application of lateral pressure caused gingival bleeding and sloughing of the tissues indicating positive Nikolsky's sign. Loss of stippling in the maxillary gingiva was seen till the mucogingival junction. Presence of erythematous areas in the right and left buccal mucosa, right retromolar region, anterior one third of the tongue and palate which interfered with deglutition and speech [Figure 1A].

A perilesional biopsy was performed from the right buccal mucosa and histopathology revealed parakeratinized stratified squamous epithelium with a subepithelial split and basal cell degeneration [Figure 1B]. The underlying connective tissue stroma showed inflammatory cell infiltrate and vascularity. DIF showed deposition of IgG and complement at the basement membrane [Figure 1C]. The clinico-histopathological and immunofluorescence testing favoured a final diagnosis of Mucous Membrane Pemphigoid.

Patient was prescribed topical application of triamcinolone acetonide thrice a day for 2 weeks over the ulcerations. Tablet betamethasone 0.5 mg was powdered mixed with water and used as a mouthwash twice daily for 10 days. The patient was also started on systemic corticosteroids 5mg twice daily for two weeks. The patient showed almost a complete healing post one month and was maintained on topical and systemic steroids and is being routinely followed up.

### Case 2

A 38 years old female reported with a chief complaint of multiple ulcers in her mouth for the past one year. Patient developed vesicles which ruptured to form painful ulcers on buccal mucosa, lips, palate and tongue, which bleed on provocation and interfere with deglutition and speech. Patient also developed a throat block followed by lesions in her right eye, face and scalp before five months. Patient had already undergone biopsy and blood investigations and had been under treatment for the past nine months with no relief of symptoms.

Extra oral examination revealed solitary lesions seen on the scalp and face. Extensive ulceration with bleeding and crustation was seen on upper and lower lips. Presence of erythema in the sclera of her right eye. Intra oral examination revealed multiple large ill defined irregular ulcers with a floor of necrotic tissue were seen. Application of lateral pressure caused gingival bleeding and sloughing of the tissues indicating positive Nikolsky's sign. Areas of erosion seen involving tip of tongue, posterior one-third and ventral tongue. Desquamation and erosions involving marginal gingiva of all teeth. White scrapable patch seen on mid dorsum of tongue. Areas of erosion with mucosal tags seen on the floor of the mouth. On palpation the ulcers were severely tender with bloody discharge from crustations [Figure 2A]. The clinico-histopathological and immunofluorescence testing favoured a final diagnosis of Mucous Membrane Pemphigoid.

The patient was started on systemic corticosteroid 5mg twice daily and topical triamcinolone acetonide 0.1% thrice daily along with 0.5mg betamethasone tablets crushed and used as a mouthwash along with vitamin C once daily. The lesions improved considerably within 4 weeks of starting the treatment with almost a complete resolution of the lesions on face, scalp and eye. The crustations on the upper and lower lip showed good healing with reduction in the erythema in the buccal, labial mucosa and palate regions [Figure 2B]. The patient was quite irregular with her appointments due course which caused exacerbation of the lesions.

### Case 3

A 31 year old male presented with swelling,pain and ulceration on upper and lower lip for the past five days.History of present illness revealed that he had fever, sore throat and body pain two days back, followed by which the ulceration and swelling was seen on the lips.Patient did not present with any cutaneous lesions.Oral lesions were present with severe pain and aggravated on mastication and speech.The patient was not under any drug intake, with no history of any systemic diseases and his family history was non contributory.

Extraoral examination revealed swelling of the upper and lower lip with multiple hemorrhagic crests covering the entire lips which bleed on provocation and was tender to palpation[Figure 3A].

Depending on the history and clinical examination,a provisional diagnosis of erythema multiforme was given.The patient was commenced with topical application of triamcinolone acetonide 0.1% gel along with antihistamine medication once daily for seven days.The oral lesions had healed and consecutively in the next week of medication there was a completed reduction in the lesion[Figure 3B,C].

### Case 4

A 10 year old girl reported with ulcerations on her lip and inner cheek region for the past one week. History revealed the presence of fever and sore throat ten days back followed by vesicles and ulcerations on the lip. Patient also complained of pain and bleeding from her lip on mastication.The patient had no relevant medical and family history.

Extra oral examination presented with multiple ulcerations of upper and lower lips, both right and left cervical lymph nodes were palpable,tender and soft to firm in consistency.On intraoral examination,diffuse ulcerations were seen on the right and left buccal mucosa with a pseudomembranous floor and surrounding erythema.Fissuring of the right and left corners of the mouth were seen.On palpation, the hemorrhagic crests were tender[Figure 4A].

Laboratory investigations revealed normal complete blood count and serology tests confirmed that the patient was positive for HSV infection with a high antibody titre.A diagnosis of Herpes associated erythema multiforme was given and the patient was treated with systemic antiviral medication 400mg twice daily along with topical application of triamcinolone acetonide 0.1% for a week.The lesion had almost completely healed post antiviral therapy[Figure 4B].

### Case 5

A 27 year old male presented with painful ulcers on his lip associated with bleeding on mastication and speech for the past two weeks.History revealed fever and malaise, following which he noted vesicles that ruptured to form ulcerations on his lips. The ulcerated areas were severely painful and consumption of food was difficult.Post few days the patient noted lesions on his upper and lower extremities which were preceded by itching.

General physical examination revealed multiple concentric target-like lesions on the upper and lower extremities[Figure 5B].Extraoral examination showed encrustations that bleed easily on provocation were noticed on the lips, upper and lower labial mucosa[Figure 5A].Poor oral hygiene was noted in the patient and diffuse ulcers with pseudomembranous floor and erythematous halo was noted.Considering the history,prodromal symptoms,hemorrhagic crusts on the lips and target lesions on the extremities, the condition was diagnosed as Erythema multiforme.

The patient was started on systemic corticosteroid 5mg twice daily and antiviral medication 400mg thrice daily along with topical application of triamcinolone acetonide 0.1% and chlorhexidine mouthwash thrice daily for a week. The lesions gradually healed and regressed and systemic corticosteroids were tapered and a maintenance dose was achieved.

### Case 6

A 40-year old male patient present with complaint of wanting replacement of his missing teeth.Patient was a known diabetic for the past 5 years and was under medication for the same.His dental and family history was non contributory.On intraoral examination, a blood filled blister was seen on the soft palate region[Figure 6A].The patient was completely unaware of the lesion and gave no relevant significant history regarding the same. On the basis of clinical appearance a provisional diagnosis of ABH was made.Patient was not willing for a biopsy.The lesion had a spontaneous healing without scarring within a week[Figure 6B].

### Case 7

A 48 year old male reported with burning sensation in her mouth for the past few weeks and aggravated on consumption of hot and spicy foods.The patient had no relevant medical history and was not under any medications.

Intraoral examination revealed generalised erythematous gingiva, desquamative, ulcerated with loss of stippling and scalloping, blunt interdental papilla, soft and edematous in consistency and generalised bleeding on probing was seen [Figure 7A]. On inspection of palatal mucosa, desquamation and ulceration was noted in relation to 16 [Figure 7B] of approximately 1cm with irregular margin representing a ulceration from a possible ruptured bullae. On palpation, it was tender and did not bleed. Perilesional biopsy was performed which revealed hyperparakeratinized stratified squamous epithelium with a sub epithelial split and underlying connective tissue stroma with minimal vascularity. The patient could not afford for an immunofluorescence testing. With the history, clinical presentation a provisional diagnosis of Bullous pemphigoid was arrived.

The patient was started on systemic steroid 5mg twice daily for one week initially and topical application of triamcinolone acetonide 0.1% thrice daily. Upon review the lesion had healed followed by which the drug was tapered and put under maintenance therapy.

## DISCUSSION

The bullous diseases to be first recognised were pemphigus and dermatitis herpetiformis; most vesiculobullous disorders were then grouped under those diagnoses. Studies revealed immune deposits (mainly IgG and C3) in some patients along the epithelial basement membrane zone of stratified squamous epithelium and the term pemphigoid was coined as the disease followed a less severe course than pemphigus. However, it later became evident that pemphigoid consisted of a family of chronic immune-mediated, subepithelial, blistering diseases that included conditions such as bullous pemphigoid, pemphigoid (herpes) gestationis, cicatricial pemphigoid, dermatitis herpetiformis, and linear IgA disease.

The clinical phenotype that is acquired and consists of vesicles, bullae or erosions, or both, and that mainly affects the oral mucosa, is termed as mucous membrane pemphigoid (MMP) (Bagan, Muzio and Scully, 2005). In studies done by Ahmed et al and Silvermann et al, the lesion predominantly affects the women with the age range of 51-62 years similar to our study but contradicting to the age range as our patients represented the 3rd decade of life. (Ahmed, Razzaque Ahmed and Hombal, 1986; Silverman *et al.*, 1986). The pathogenesis of MMP is probably an autoantibody induced, complement-mediated release of cytokines and leukocyte enzymes by neutrophil sequestration and possibly complement mediated cell lysis, responsible for loss of basal cell-basement membrane adhesion, thus leading to vesicle formation under epithelium (Scully and Lo Muzio, 2008). Desquamative gingivitis is one of the main clinical signs in MMP which is similar to our case reports followed by vesicles or bullae in oral mucosa, positive for Nikolsky sign. The vesicles then break to form ulcers leading to pseudo membrane-covered irregular erosions which have yellowish slough surrounded by an inflammatory halo. The hard palate, soft palate, buccal mucosa, alveolar ridge, tongue may be involved which is similar to our case presentation (Schmidt and Zillikens, 2013). The preferred site for biopsy is vesicle or perilesional tissue, which shows subepithelial split with a variable inflammatory cells infiltrate which was consistent to the histopathologic picture of our MMP cases. Direct immunofluorescence (DIF) is essential for confirmatory diagnosis and typically shows linear deposition of IgG, C3, less commonly IgA, along the basement membrane zone which was similar to the DIF presented in our case 1 report (Bruch-Gerharz, Hertl and Ruzicka, 2007). Studies done by Brenard et al and Calabresi et al have also shown that target antigen is achieved with enzyme-linked immunosorbent assay systems for BP180 and laminin 332 in MMP (Calabresi *et al.*, 2007; Bernard *et al.*, 2013). Amongst the numerous immunomodulatory drugs used in treating Oral mucous membrane pemphigoid-Corticosteroids (both topical and systemic) are used predominantly which was also followed in our patients. In case of partial response to systemic steroids, adjuvant therapy with azathioprine, cyclophosphamide, dapson or mycophenolate mofetil has been used effectively in the treatment of MMP along with Rituximab, low-energy laser phototherapy and cryotherapy are also used (Di Zenzo, Carozzo and Chan, 2014).

Medical literature has coupled numerous factors to the development of EM which include infections, use of certain medications, malignancy, autoimmunity, radiation, immunization, and menstruation. 90% of cases are represented by infection and the most common agent is herpes simplex virus (HSV), (Sokumbi and Wetter, 2012) which is in up to 70–80% of the cases. Another study done by Sun et al revealed that the cutaneous lesions of patients with EM were infected higher with HSV-1 than in HSV-2 cases (Sun *et al.*, 2003). Lip is considered to be the most commonest site affected preceding a HSV infection which was similar in our HAEM case (Osterne *et al.*, 2009). Serology testing is one of the confirmatory test for identifying HAEM which was positive in our case 4 report. Management involves topical analgesics and oral antihistamines and topical steroids are used commonly to provide relief. Oral antiviral therapy have also shown effectiveness in preventing recurrent HAEM.

Study done by Rashmitha et al (Rashmitha *et al.*, 2017) states EM usually affects individuals at 20 to 40 years which is concordance to our case. Clinical diagnosis plays a very important role which comprise the presence of target lesions, raised atypical papules or mucosal involvement. Our case presented with target lesions in the upper and lower extremities. Biopsies are proven to be helpful only in early vesicular lesions and not in ulcerations as they appear as non-specific. Management involves changing the drug if its the precipitant and in case of viral etiology similar to our case when HSV infection existed, majority of the cases are treated on antiviral therapy

along with topical or systemic steroids with a tapering protocol. In recalcitrant cases, Azathioprine, cyclophosphamide, dapsone, cyclosporine, levamisole, thalidomide, interferon- $\alpha$ , and cyclosporine are drugs of choice (Simbli, 2013)

ABH is an idiopathic condition and the common causes according to literature have been minor trauma of hot foods, restorative dentistry, periodontal therapy, dental injections of anesthetics (Garlick and Calderon, 1988), steroid inhalers and chlorhexidine gluconate mouthrinse (Yamamoto *et al.*, 2006). In a study done by Rai *et al.*, the blisters spontaneously ruptured, leaving a shallow ulcer that heals without scarring similarly seen in our case. The soft palate is the most commonly affected site which was similar to our case (Rai, Kaur and Goel, 2012). Though the diagnosis is clinical for ABH, histopathological testing done in literature reveals subepithelial bullae filled with blood and an underlying mononuclear inflammatory cell infiltrate often limited to lamina propria (Stephenson *et al.*, 1987).

BP is an autoimmune vesiculobullous disease usually affecting the elderly people; its incidence increases with age (Jung *et al.*, 1999). Our study patient was a middle aged male. Oral involvement is seen prior to skin manifestations with the commonly affected site being palate which is similar to our case. Oral lesions comprise of bullae/vesicle that rupture to form erosions and ultimately leave out ulcerations (Rawther, James and Sreedhar, 2015). Clinical presentation of chronic desquamative gingivitis was evident in our case. Though Direct immunofluorescence is found to be the gold standard test, histopathological report revealed subepithelial split is diagnostic. Treatment includes topical steroid application and gives satisfactory result in case of smaller area of skin involvement, whereas larger area of skin involvement and recurrent cases are treated satisfactorily with systemic steroids and immunosuppressive agents (Joly *et al.*, 2002). Our case presented with only oral lesions and was managed using systemic steroid application. Other drugs for treating BP include new antibody modulators, rituximab 375mg/m<sup>2</sup> weekly over 4 weeks (Cho, Chu and Wang, 2015). A study done by Ahmed *et al.* revealed intravenous IgA dose of 1–2 g/kg for five consecutive day cycles of 0.4 g/kg/day, although a 3-day cycle may be used in cases that are unresponsive to conventional therapy have been proven effective (Ahmed, 2001). Our institution is passionate about high quality evidence based research and has excelled in various fields (Pc, Marimuthu and Devadoss, 2018; Ramesh *et al.*, 2018; Vijayashree Priyadharsini, Smiline Girija and Paramasivam, 2018; Ezhilarasan, Apoorva and Ashok Vardhan, 2019; Ramadurai *et al.*, 2019; Sridharan *et al.*, 2019; Vijayashree Priyadharsini, 2019; Chandrasekar *et al.*, 2020; Mathew *et al.*, 2020; R *et al.*, 2020; Samuel, 2021)

## CONCLUSION

Immune mediated sub - epithelial vesiculobullous disorders are rare in occurrence, with difficulty in early diagnosis due to severity and often camouflage of clinical presentation. Biopsy and immunofluorescence testing remain as gold standard in arriving at a definitive diagnosis. Chronic presentation of the disease is present proper and routine follow up of the patients are mandatory. Management of these lesions often require a interdisciplinary approach among the dentists, dermatologists, ophthalmologists and general practitioners.

## Declaration of Patient Consent

The authors declare that they have obtained consent forms from all the patients which provides their consent in usage of his/her/their images and other clinical information to be reported in a journal. The patients are conveyed that their names and initials will not be published and efforts will be made in concealing their identities, but anonymity cannot be guaranteed.

## AUTHORS CONTRIBUTION

Abhinaya LM has made substantial contributions towards study design, acquiring an analysis of data, drafting the final paper and revising it critically.

M. Arvind has made substantial contributions towards study design, acquiring an analysis of data, drafting the final paper and revising it critically.

## CONFLICT OF INTEREST

NIL

## REFERENCES

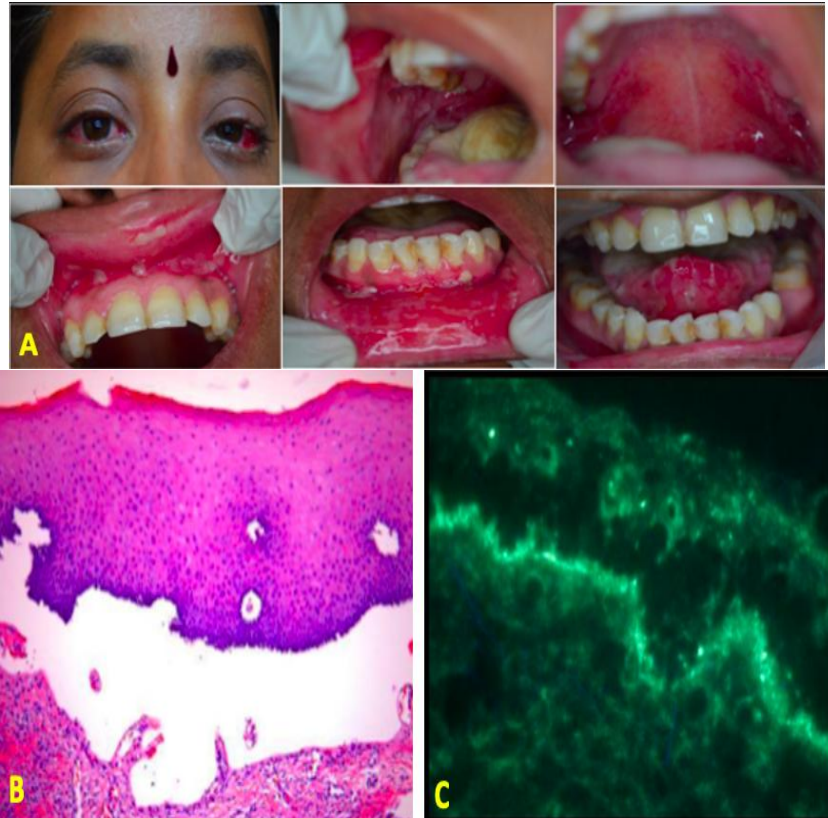1. Ahmed, A. R. (2001) 'Intravenous immunoglobulin therapy for patients with bullous pemphigoid unresponsive to conventional immunosuppressive treatment', *Journal of the American Academy of Dermatology*, 45(6), pp. 825–835.
2. Ahmed, A. R., Razzaque Ahmed, A. and Hombal, S. M. (1986) 'Cicatricial Pemphigoid', *International Journal of Dermatology*, pp. 90–96. doi: 10.1111/j.1365-4362.1986.tb04544.x.
3. Angiero, F. *et al.* (2007) 'A rare case of desquamative gingivitis due to linear IgA disease: morphological and immunofluorescence features', *In vivo*, 21(6), pp. 1093–1098.

4. Bagan, J., Muzio, L. L. and Scully, C. (2005) 'Number III Mucous membrane pemphigoid', *Oral Diseases*, pp. 197–218. doi: 10.1111/j.1601-0825.2005.01140.x.
5. Bernard, P. et al. (2013) 'Prevalence and Clinical Significance of Anti-Laminin 332 Autoantibodies Detected by a Novel Enzyme-Linked Immunosorbent Assay in Mucous Membrane Pemphigoid', *JAMA Dermatology*, p. 533. doi: 10.1001/jamadermatol.2013.1434.
6. Bruch-Gerharz, D., Hertl, M. and Ruzicka, T. (2007) 'Mucous membrane pemphigoid: clinical aspects, immunopathological features and therapy', *European journal of dermatology: EJD*, 17(3), pp. 191–200.
7. Calabresi, V. et al. (2007) 'Oral pemphigoid autoantibodies preferentially target BP180 ectodomain', *Clinical immunology*, 122(2), pp. 207–213.
8. Chandrasekar, R. et al. (2020) 'Development and validation of a formula for objective assessment of cervical vertebral bone age', *Progress in orthodontics*, 21(1), p. 38.
9. Cho, Y. T., Chu, C. Y. and Wang, L. F. (2015) 'First-line combination therapy with rituximab and corticosteroids provides a high complete remission rate in moderate-to-severe bullous pemphigoid', *The British journal of dermatology*, 173(1), pp. 302–304.
10. Dear, J. W., Lilitkarntakul, P. and Webb, D. J. (2006) 'Are rare diseases still orphans or happily adopted? The challenges of developing and using orphan medicinal products', *British journal of clinical pharmacology*, 62(3), pp. 264–271.
11. Deogade, S., Gupta, P. and Ariga, P. (2018) 'Effect of monopoly-coating agent on the surface roughness of a tissue conditioner subjected to cleansing and disinfection: A Contact Profilometric In vitro study', *Contemporary Clinical Dentistry*, p. 122. doi: 10.4103/ccd.ccd\_112\_18.
12. Di Zenzo, G., Carozzo, M. and Chan, L. S. (2014) 'Urban legend series: mucous membrane pemphigoid', *Oral diseases*, 20(1), pp. 35–54.
13. Dua, K. et al. (2019) 'The potential of siRNA based drug delivery in respiratory disorders: Recent advances and progress', *Drug development research*, 80(6), pp. 714–730.
14. Duraisamy, R. et al. (2019) 'Compatibility of Nonoriginal Abutments With Implants: Evaluation of Microgap at the Implant-Abutment Interface, With Original and Nonoriginal Abutments', *Implant dentistry*, 28(3), pp. 289–295.
15. Ezhilarasan, D. (2018) 'Oxidative stress is bane in chronic liver diseases: Clinical and experimental perspective', *Arab journal of gastroenterology: the official publication of the Pan-Arab Association of Gastroenterology*, 19(2), pp. 56–64.
16. Ezhilarasan, D., Apoorva, V. S. and Ashok Vardhan, N. (2019) 'Syzygium cumini extract induced reactive oxygen species-mediated apoptosis in human oral squamous carcinoma cells', *Journal of oral pathology & medicine: official publication of the International Association of Oral Pathologists and the American Academy of Oral Pathology*, 48(2), pp. 115–121.
17. Ezhilarasan, D., Sokal, E. and Najimi, M. (2018) 'Hepatic fibrosis: It is time to go with hepatic stellate cell-specific therapeutic targets', *Hepatobiliary & pancreatic diseases international: HBPD INT*, 17(3), pp. 192–197.
18. Garlick, J. A. and Calderon, S. (1988) 'Oral blood blisters in angina bullosa haemorrhagica secondary to trauma of eating and dental injection', *British Dental Journal*, pp. 286–287. doi: 10.1038/sj.bdj.4806604.
19. Gheena, S. and Ezhilarasan, D. (2019) 'Syringic acid triggers reactive oxygen species-mediated cytotoxicity in HepG2 cells', *Human & experimental toxicology*, 38(6), pp. 694–702.
20. Giuliani, M. et al. (2002) 'Angina bullosa haemorrhagica: presentation of eight new cases and a review of the literature', *Oral diseases*, 8(1), pp. 54–58.
21. Gomathi, A. C. et al. (2020) 'Anticancer activity of silver nanoparticles synthesized using aqueous fruit shell extract of Tamarindus indica on MCF-7 human breast cancer cell line', *Journal of Drug Delivery Science and Technology*, p. 101376. doi: 10.1016/j.jddst.2019.101376.
22. Jeevanandan, G. and Govindaraju, L. (2018) 'Clinical comparison of Kedo-S paediatric rotary files vs manual instrumentation for root canal preparation in primary molars: a double blinded randomised clinical trial', *European Archives of Paediatric Dentistry*, pp. 273–278. doi: 10.1007/s40368-018-0356-6.
23. Joly, P. et al. (2002) 'A comparison of oral and topical corticosteroids in patients with bullous pemphigoid', *The New England journal of medicine*, 346(5), pp. 321–327.
24. J, P. C. et al. (2018) 'Prevalence and measurement of anterior loop of the mandibular canal using CBCT: A cross sectional study', *Clinical implant dentistry and related research*, 20(4), pp. 531–534.
25. Jung, M. et al. (1999) 'Increased risk of bullous pemphigoid in male and very old patients: A population-based study on incidence', *Journal of the American Academy of Dermatology*, 41(2), pp. 266–268.
26. Korman, N. J. (1993) 'Bullous pemphigoid', *Dermatologic clinics*, 11(3), pp. 483–498.
27. Malli Sureshbabu, N. et al. (2019) 'Concentrated Growth Factors as an Ingenious Biomaterial in Regeneration of Bony Defects after Periapical Surgery: A Report of Two Cases', *Case reports in dentistry*, 2019, p. 7046203.
28. Mathew, M. G. et al. (2020) 'Evaluation of adhesion of Streptococcus mutans, plaque accumulation on

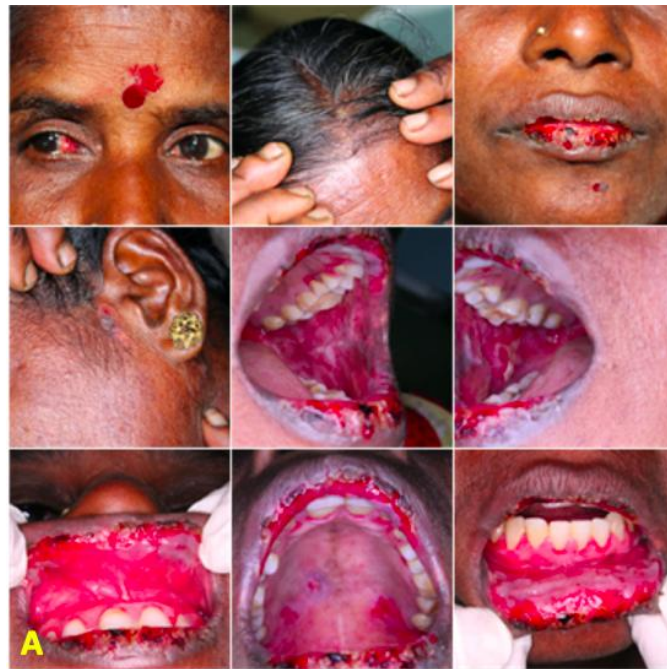- zirconia and stainless steel crowns, and surrounding gingival inflammation in primary molars: Randomized controlled trial', *Clinical oral investigations*, pp. 1–6.
29. Mehta, M. et al. (2019) 'Oligonucleotide therapy: An emerging focus area for drug delivery in chronic inflammatory respiratory diseases', *Chemico-biological interactions*, 308, pp. 206–215.
  30. Menon, S. et al. (2018) 'Selenium nanoparticles: A potent chemotherapeutic agent and an elucidation of its mechanism', *Colloids and Surfaces B: Biointerfaces*, pp. 280–292. doi: 10.1016/j.colsurfb.2018.06.006.
  31. Mutasim, D. F., Pelc, N. J. and Anhalt, G. J. (1993) 'Cicatricial pemphigoid', *Dermatologic clinics*, 11(3), pp. 499–510.
  32. Osterne, R. L. V. et al. (2009) 'Management of erythema multiforme associated with recurrent herpes infection: a case report', *Journal*, 75(8), pp. 597–601.
  33. Panchal, V., Jeevanandan, G. and Subramanian, E. M. G. (2019) 'Comparison of post-operative pain after root canal instrumentation with hand K-files, H-files and rotary Kedo-S files in primary teeth: a randomised clinical trial', *European archives of paediatric dentistry: official journal of the European Academy of Paediatric Dentistry*, 20(5), pp. 467–472.
  34. Patil, S. R. et al. (2018) 'Comparative Study of the Efficacy of Newer Antioxidants Lycopene and Oxitard in the Treatment of Oral Submucous Fibrosis', *Pesquisa brasileira em odontopediatria e clinica integrada*, 18(1), pp. 1–7.
  35. Patil, S. R. et al. (2018) 'Three-Rooted Mandibular First Molars in a Saudi Arabian Population: A CBCT Study', *Pesquisa brasileira em odontopediatria e clinica integrada*, 18(1), p. e4133.
  36. Patil, S. R. et al. (2020) 'Assessment of Maximum Bite Force in Oral Submucous Fibrosis Patients: A Preliminary Study', *Pesquisa brasileira em odontopediatria e clinica integrada*, 20, p. 482.
  37. Pc, J., Marimuthu, T. and Devadoss, P. (2018) 'Prevalence and measurement of anterior loop of the mandibular canal using CBCT: A cross sectional study', *Clinical implant dentistry and related research*. Available at: <https://europepmc.org/article/med/29624863>.
  38. Prabakar, J. et al. (2018) 'Comparative Evaluation of Retention, Cariostatic Effect and Discoloration of Conventional and Hydrophilic Sealants - A Single Blinded Randomized Split Mouth Clinical Trial', *Contemporary clinical dentistry*, 9(Suppl 2), pp. S233–S239.
  39. Rai, S., Kaur, M. and Goel, S. (2012) 'Angina bullosa hemorrhagica: report of two cases', *Indian journal of dermatology*, 57(6), p. 503.
  40. Rajendran, R. et al. (2019) 'Comparative Evaluation of Remineralizing Potential of a Paste Containing Bioactive Glass and a Topical Cream Containing Casein Phosphopeptide-Amorphous Calcium Phosphate: An in Vitro Study', *Pesquisa Brasileira em Odontopediatria e Clínica Integrada*, pp. 1–10. doi: 10.4034/pboci.2019.191.61.
  41. Rajeshkumar, S. et al. (2018) 'Biosynthesis of zinc oxide nanoparticles using *Mangifera indica* leaves and evaluation of their antioxidant and cytotoxic properties in lung cancer (A549) cells', *Enzyme and microbial technology*, 117, pp. 91–95.
  42. Rajeshkumar, S. et al. (2019) 'Antibacterial and antioxidant potential of biosynthesized copper nanoparticles mediated through *Cissus arnotiana* plant extract', *Journal of photochemistry and photobiology. B, Biology*, 197, p. 111531.
  43. Ramadurai, N. et al. (2019) 'Effectiveness of 2% Articaine as an anesthetic agent in children: randomized controlled trial', *Clinical oral investigations*, 23(9), pp. 3543–3550.
  44. Ramakrishnan, M., Dhanalakshmi, R. and Subramanian, E. M. G. (2019) 'Survival rate of different fixed posterior space maintainers used in Paediatric Dentistry - A systematic review', *The Saudi dental journal*, 31(2), pp. 165–172.
  45. Ramesh, A. et al. (2018) 'Comparative estimation of sulfiredoxin levels between chronic periodontitis and healthy patients - A case-control study', *Journal of periodontology*, 89(10), pp. 1241–1248.
  46. Rashmitha, A. et al. (2017) 'Erythema multiforme: A case report', *Journal of Indian Academy of Oral Medicine and Radiology*, 29(2), p. 153.
  47. Rawther, N. N., James, J. and Sreedhar, S. (2015) 'Bullous pemphigoid of the oral cavity-2 case reports with review of literature', *IOSR Journal of Dental and Medical Sciences*, 14(9), pp. 111–114.
  48. R, H. et al. (2020) 'CYP2 C9 polymorphism among patients with oral squamous cell carcinoma and its role in altering the metabolism of benzo[a]pyrene', *Oral Surgery, Oral Medicine, Oral Pathology and Oral Radiology*, pp. 306–312. doi: 10.1016/j.oooo.2020.06.021.
  49. Samuel, S. R. (2021) 'Can 5-year-olds sensibly self-report the impact of developmental enamel defects on their quality of life?', *International journal of paediatric dentistry / the British Paedodontic Society [and] the International Association of Dentistry for Children*, 31(2), pp. 285–286.
  50. Samuel, S. R., Acharya, S. and Rao, J. C. (2020) 'School Interventions-based Prevention of Early-Childhood Caries among 3-5-year-old children from very low socioeconomic status: Two-year randomized trial', *Journal of public health dentistry*, 80(1), pp. 51–60.
  51. Schmidt, E. and Zillikens, D. (2013) 'Pemphigoid diseases', *The Lancet*, 381(9863), pp. 320–332.

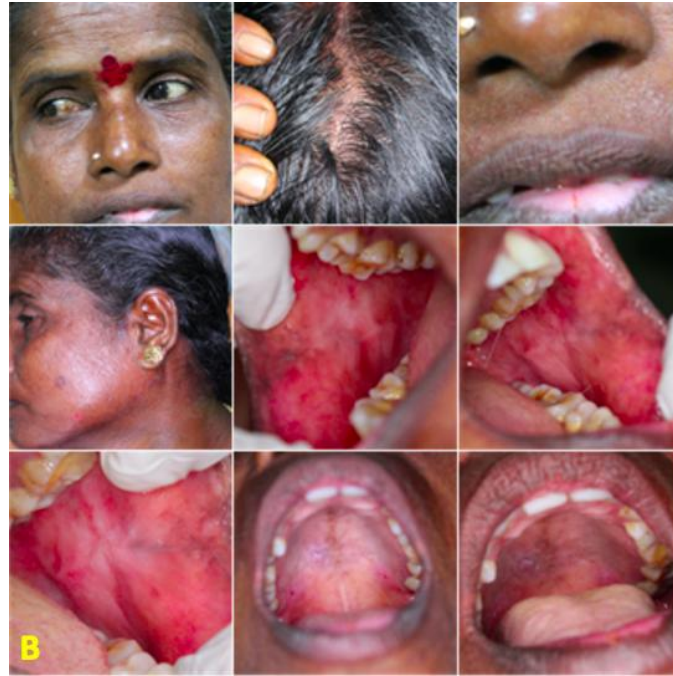52. Scully, C. and Lo Muzio, L. (2008) 'Oral mucosal diseases: mucous membrane pemphigoid', *The British journal of oral & maxillofacial surgery*, 46(5), pp. 358–366.
53. Sharma, P. et al. (2019) 'Emerging trends in the novel drug delivery approaches for the treatment of lung cancer', *Chemico-biological interactions*, 309, p. 108720.
54. Silverman, S., Jr et al. (1986) 'Oral mucous membrane pemphigoid. A study of sixty-five patients', *Oral surgery, oral medicine, and oral pathology*, 61(3), pp. 233–237.
55. Simbli, M. A. (2013) 'Erythema multiforme: Challenging diagnosis for internist', *J Clin Case Rep*, 3(7), pp. 285–288.
56. Singh, D. et al. (2013) 'Angina bullosa haemorrhagica', *BMJ case reports*, 2013. doi: 10.1136/bcr-2012-008505.
57. Sokumbi, O. and Wetter, D. A. (2012) 'Clinical features, diagnosis, and treatment of erythema multiforme: a review for the practicing dermatologist', *International journal of dermatology*, 51(8), pp. 889–902.
58. Sridharan, G. et al. (2019) 'Evaluation of salivary metabolomics in oral leukoplakia and oral squamous cell carcinoma', *Journal of oral pathology & medicine: official publication of the International Association of Oral Pathologists and the American Academy of Oral Pathology*, 48(4), pp. 299–306.
59. Stephenson, P. et al. (1987) 'Angina bullosa haemorrhagica: lesional immunostaining and haematological findings', *The British journal of oral & maxillofacial surgery*, 25(6), pp. 488–491.
60. Subramaniam, N. and Muthukrishnan, A. (2019) 'Oral mucositis and microbial colonization in oral cancer patients undergoing radiotherapy and chemotherapy: A prospective analysis in a tertiary care dental hospital', *Journal of investigative and clinical dentistry*, 10(4), p. e12454.
61. Sun, Y. et al. (2003) 'Detection and genotyping of human herpes simplex viruses in cutaneous lesions of erythema multiforme by nested PCR', *Journal of medical virology*, 71(3), pp. 423–428.
62. Tsai, I.-C. et al. (2010) 'Linear IgA bullous dermatosis: a clinical study of 16 cases at National Taiwan University Hospital', *Dermatologica Sinica*, pp. 21–26. doi: 10.1016/s1027-8117(10)60003-1.
63. Vadivel, J. K. et al. (2019) 'Mast cell expression in oral lichen planus: A systematic review', *Journal of investigative and clinical dentistry*, 10(4), p. e12457.
64. Varghese, S. S., Ramesh, A. and Veeraiyan, D. N. (2019) 'Blended Module-Based Teaching in Biostatistics and Research Methodology: A Retrospective Study with Postgraduate Dental Students', *Journal of dental education*, 83(4), pp. 445–450.
65. Vijayashree Priyadharsini, J. (2019) 'In silico validation of the non-antibiotic drugs acetaminophen and ibuprofen as antibacterial agents against red complex pathogens', *Journal of periodontology*, 90(12), pp. 1441–1448.
66. Vijayashree Priyadharsini, J., Smiline Girija, A. S. and Paramasivam, A. (2018) 'In silico analysis of virulence genes in an emerging dental pathogen *A. baumannii* and related species', *Archives of oral biology*, 94, pp. 93–98.
67. Vishnu Prasad, S. et al. (2018) 'Report on oral health status and treatment needs of 5-15 years old children with sensory deficits in Chennai, India', *Special care in dentistry: official publication of the American Association of Hospital Dentists, the Academy of Dentistry for the Handicapped, and the American Society for Geriatric Dentistry*, 38(1), pp. 58–59.
68. Wahab, P. U. A. et al. (2018) 'Scalpel Versus Diathermy in Wound Healing After Mucosal Incisions: A Split-Mouth Study', *Journal of oral and maxillofacial surgery: official journal of the American Association of Oral and Maxillofacial Surgeons*, 76(6), pp. 1160–1164.
69. Xu, H.-H. et al. (2013) 'Mucous membrane pemphigoid', *Dental clinics of North America*, 57(4), pp. 611–630.
70. Yamamoto, K. et al. (2006) 'Angina bullosa hemorrhagica of the soft palate: report of 11 cases and literature review', *Journal of oral and maxillofacial surgery: official journal of the American Association of Oral and Maxillofacial Surgeons*, 64(9), pp. 1433–1436.



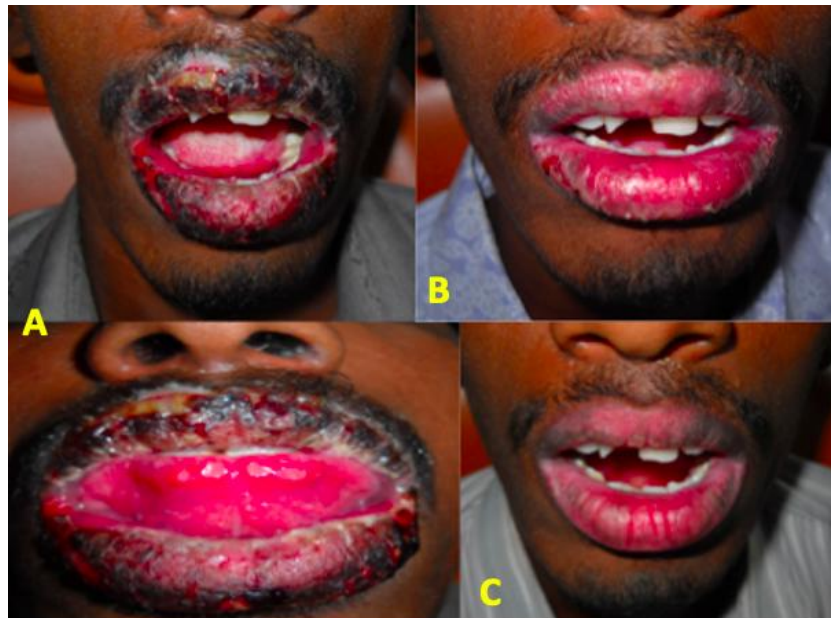

**Fig.1:(A)Erythema in the sclera; Single localized ulcers seen in the upper labial mucosa in relation to 21,14 and in attached gingiva in relation to 32.Erythematous areas in the right and left buccal mucosa,right retromolar region,anterior one third of the tongue and palate.  
(B) Histopathology image showing parakeratinized stratified squamous epithelium with a subepithelial split and basal cell degeneration  
(C) DIF showed deposition of IgG and complement at the basement membrane.**

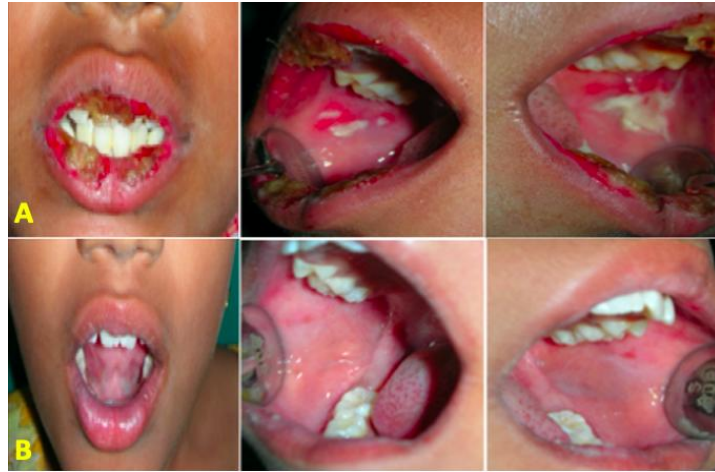



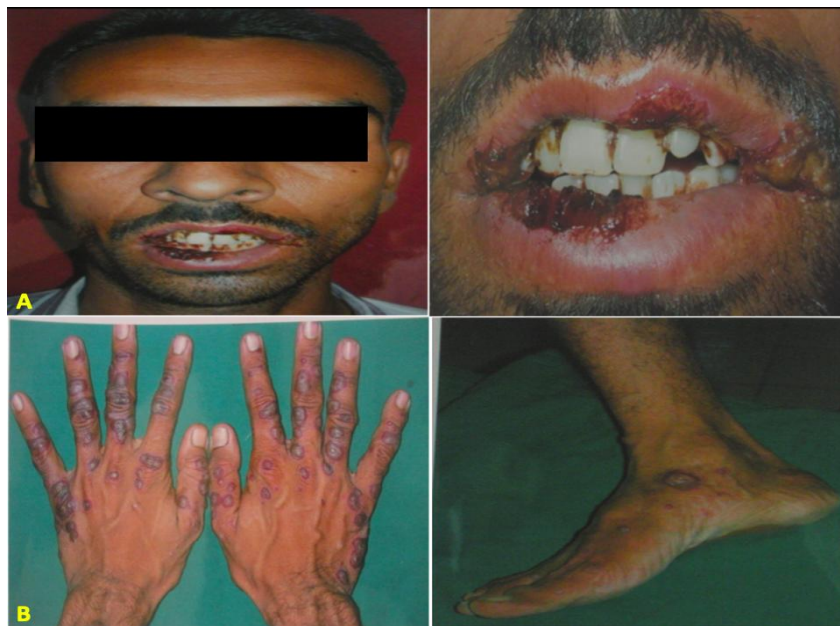**Fig.2: (A) Erythema in the sclera of right eye; solitary lesions seen in the scalp and face; Extensive ulceration with bleeding and crusting was seen on upper and lower lips (B) Post treatment showed almost complete healing of the sclera, cutaneous lesion, buccal mucosa, palate and tongue.**



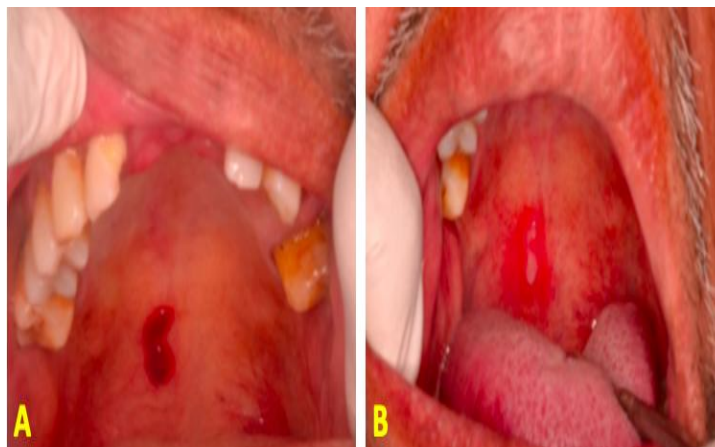
**Fig.3:(A)Swelling of the upper and lower lip with multiple hemorrhagic crusting covering the entire lips which bleed on provocation. (B)and(C) Post treatment, first and second visit showed good healing of the lesion.**



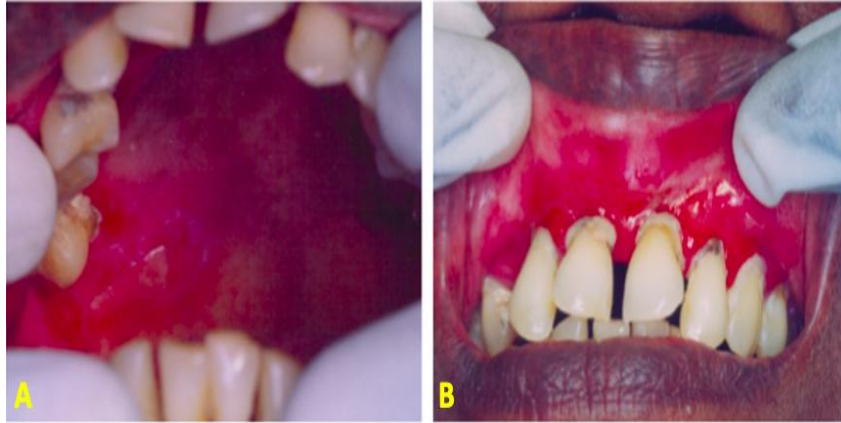
**Fig.4:(A) multiple encrustations seen covering the upper and lower lips; ulcerations with surrounding erythema seen on the right and left buccal mucosa. (B) Follow up visit shows almost complete healing of the ulcers.**



**Fig.5: (A) Ulcerations and hemorrhagic crusts seen on the upper and lower lip (B) Multiple concentric target-like lesions on the upper and lower extremities.**



**Fig.6:(A) Blood filled blister was seen on the soft palate region. (B)Complete resolution of lesion seen without scarring.**



**Fig.7:(A)Desquamation and ulceration was noted in palatal mucosa in relation to 16  
(B)Generalised erythematous gingiva, desquamative,ulcerated with loss of stippling and scalloping and blunt interdental papilla was seen.**