
Age and Gender Predilection of Mesiodens- A Retrospective Study

SWETAA.A¹, DR. GHEENA S^{2*}, DR. JESSY P³

¹Saveetha Dental College , Saveetha Institute of Medical and Technical Sciences, Saveetha University, 62, Poonamallee High Road, Chennai-600077, Tamil Nadu, India

²Associate professor, Department of Oral pathology, Saveetha Dental College, Saveetha Institute of Medical and Technical Sciences, Saveetha University, 62, Poonamallee High Road, Chennai-600077, Tamil Nadu, India

³Senior Lecturer, Department of Pedodontics, Saveetha Dental College, Saveetha Institute of Medical and Technical Sciences, Saveetha University, 62, Poonamallee High Road, Chennai-600077, Tamil Nadu, India

*Corresponding Author

Email: 151701019.sdc@saveetha.com¹, gheens@gmail.com gheena@saveetha.com², jessyp.sdc@saveetha.com³

Abstract: Mesiodens is a supernumerary tooth which is placed in the midline between two central incisors or the position may change according to the individuals. Supernumerary teeth are a developmental disturbance occurring during odontogenesis resulting in the formation of the teeth in the excess of normal numbers. The aim of the study is to assess age and gender predilection of mesiodens among the general population. Retrospective analysis of all cases with a diagnosis of mesiodens. A total of 61 case sheets were reviewed from patient records. Tabulated in excel sheet. Imported to SPSS Version 20.0. Descriptive analyses were reported. The p value is not significant, in spite of the association presence of mesiodens in male population compared to female, hence the study should be done with a larger sample size.

Keywords: Mesiodens; Conical; Gender; Age; Shape.

INTRODUCTION

Mesiodens is a supernumerary tooth which is placed in the midline between two central incisors or the position may change according to each individual. Supernumerary teeth are a developmental disturbance occurring during odontogenesis resulting in the formation of the teeth in excess of the normal number (Thangaraj *et al.*, 2016; 'Dentigerous Cyst in Association with Impacted Mesiodens in Non Syndromic Patient', 2017) Syed Mustansir Ul Hassnain (Thangaraj *et al.*, 2016; 'Dentigerous Cyst in Association with Impacted Mesiodens in Non Syndromic Patient', 2017) (Thangaraj *et al.*, 2016; 'Dentigerous Cyst in Association with Impacted Mesiodens in Non Syndromic Patient', 2017). They occur both in the deciduous and permanent dentition. Supernumerary teeth can be classified based on the time of appearance, according to the position of arch and according to their shape (Primosch, 1981; Gupta and Ramani, 2016) . Supernumerary teeth may be single, multiple unilateral or bilateral, erupted or unerupted and in one or both jaws (C, 2015; Sivaramakrishnan and Ramani, 2015). Among the supernumerary teeth, mesiodens is the most common type. Morphologically mesiodens may have heterogeneous forms. Three common types; namely conical or peg shaped, tuberculate and supplemental (tooth like) have been reported, of which the conical form is the most common type (Rosenzweig and Garbarski, 1965; Hannah *et al.*, 2018). Mesiodens can be diagnosed through clinical and radiographic examination using the maxillary anterior periapical and occlusal radiography. In addition to these, orthopantomograph and lateral cephalogram can also aid in the diagnosis (Kokten, Balcioglu and Buyukertan, 2003; Sridharan, Ramani and Patankar, 2017). Usually, mesiodens is associated with eruption disturbances, midline diastema or other malocclusions (Taylor, 1972; Shree *et al.*, 2019). The premaxillary region such as rotation or axial inclination of permanent central incisors, resorption of roots of adjacent teeth and sometimes even dentigerous cyst formation (Ravn, 1971; Viveka *et al.*, 2016). Hyperactivity of embryonic epithelial cells, tooth germs are equal but some can differentiate into investigations that would result in new dental tissue (Mukhopadhyay, 2011; G. Jayaraj *et al.*, 2015). It can be either from dental lamina being attached to this by the dentis gubernaculum (Lee *et al.*, 2014; Jangid *et al.*, 2015). New tooth buds may originate either by over reactivity of the outer layer sheath of hertwigs or epithelial remains of malassez (Vecchione Gurgel *et al.*, 2013; Gifrina Jayaraj, Ramani, *et al.*, 2015). The split of the dental follicle, the theory of dichotomy and some factors such as trauma, evolutionary mutations, can cause accidental division into two or more fragments (Shekhar, 2012; Sridharan *et al.*, 2019a). According to the theory of atavism it is mesiodens the third incisors primates would be a phylogenetic reversal (Amin *et al.*, 2014; Swathy, Gheena and Varsha, 2015). Supernumerary teeth may be associated with some syndromes such as fabry's syndrome, cherubism, apert syndrome, cleidocranial dysplasia or goazon disease, cleft lip, cleft palate , gardner syndrome and other as hereditary fibromatosis

associated with hearing loss and supernumerary teeth (Choi *et al.*, 2011). The appearance of mesiodens can occur in individuals with no syndrome. Management of supernumerary teeth depends on the type and position of the tooth(Gharote *et al.*, 2011).Immediate removal of mesiodens is usually indicated in the following situation; inhibition or delay of eruption, displacement of the adjacent tooth, interference with orthodontic appliance, presence of pathologic condition or spontaneous eruption of the supernumerary teeth(Sherlin *et al.*, 2015; Zhao *et al.*, 2020)Our team has rich experience in research and we have collaborated with numerous authors over various topics in the past decade (Deogade, Gupta and Ariga, 2018; Ezhilarasan, 2018; Ezhilarasan, Sokal and Najimi, 2018; Jeevanandan and Govindaraju, 2018; J *et al.*, 2018; Menon *et al.*, 2018; Prabakar *et al.*, 2018; Rajeshkumar *et al.*, 2018, 2019; Vishnu Prasad *et al.*, 2018; Wahab *et al.*, 2018; Dua *et al.*, 2019; Duraisamy *et al.*, 2019; Ezhilarasan, Apoorva and Ashok Vardhan, 2019; Gheena and Ezhilarasan, 2019; Malli Sureshababu *et al.*, 2019; Mehta *et al.*, 2019; Panchal, Jeevanandan and Subramanian, 2019; Rajendran *et al.*, 2019; Ramakrishnan, Dhanalakshmi and Subramanian, 2019; Sharma *et al.*, 2019; Varghese, Ramesh and Veeraiyan, 2019; Gomathi *et al.*, 2020; Samuel, Acharya and Rao, 2020)

The aim of the study is to assess age and gender predilection of mesiodens among patients visited saveetha dental college.

MATERIALS AND METHOD

The study comprised a retrospective analysis of all cases with a diagnosis of mesiodens. A total of 61 case sheets were retrieved from Dental Information Achieving Software (DIAS) which contains all the patients records from the initial to final visit. The study was carried out in an institutional setting with the advantage of being a wide range of data availability in digital format and the disadvantage being assessment of patients only in a single institution. The approval was granted by the institutional ethics committee.The study involves one guide and two reviewers .The collected data was subjected to photographic and radiographic cross verification. Data retrieved were chronologically recorded.

Parameters assessed and tabulated were:-

- Age
- Gender
- No.of Mesiodens
- Type/shape of mesiodens
- Position
- Complication

The data is imported and variables were coded and imported to SPSS.Using SPSS version 20.0, descriptive statistics were carried out and chi square test was used for inferential statistics , p-value was calculated and graphs were plotted to arrive at final inference.

RESULTS AND DISCUSSION

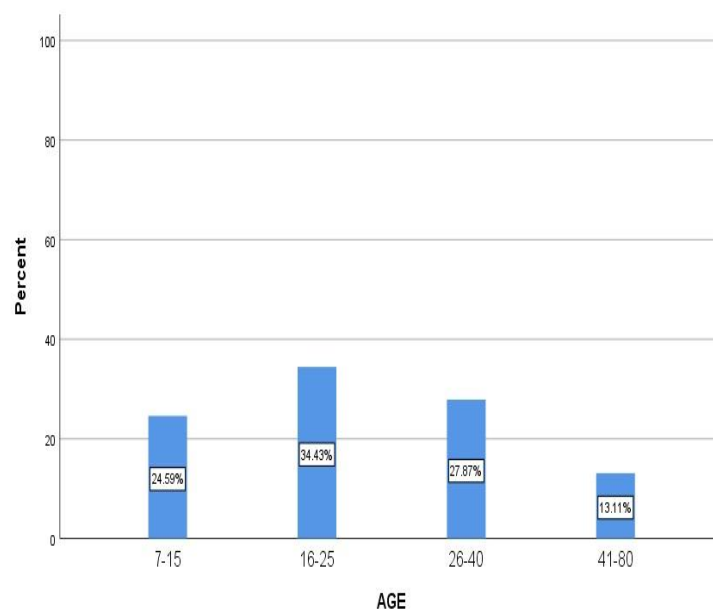


Fig.1: Frequency of patients distributed according to age.

Graph 1- Shows the frequency of patients distributed according to age group from 7-60 years of age for mesiodens. It was seen that 16-25 years of age are highest no. of patients reported with mesiodens.

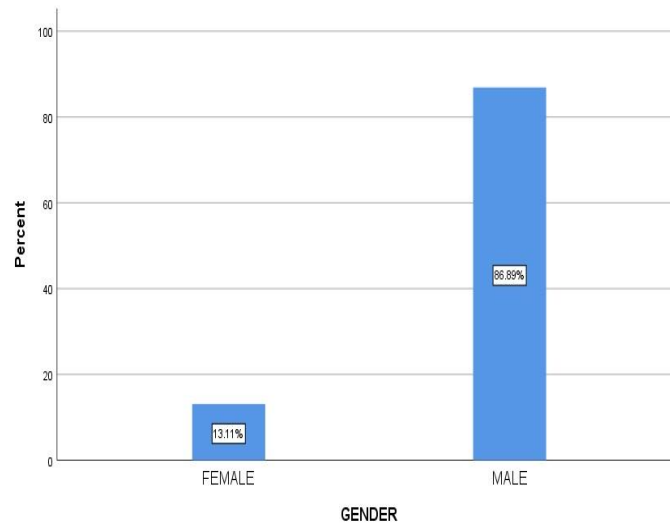


Fig.2: Gender distribution

Figure 2 Shows the frequency of gender distribution of patients visiting the op. It is inferred that males have reported highest in number with presence of mesiodens.

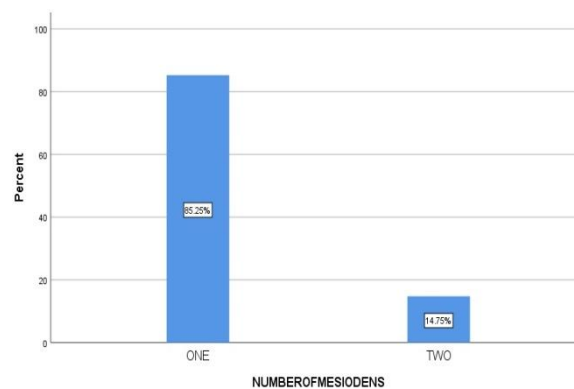


Fig.3: Frequency of number of mesiodens

Figure 3 shows the frequency of no. of mesiodens present in each patient. Most of the patients have reported only with one mesiodens present in the oral cavity.

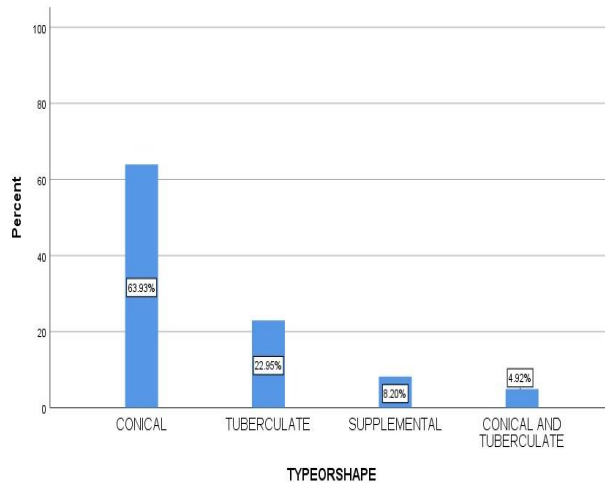


Fig.4: Type/shape of mesiodens

Figure 4 shows the frequency of type and shape of mesiodens. Most of the patients have reported conical shape mesiodens.

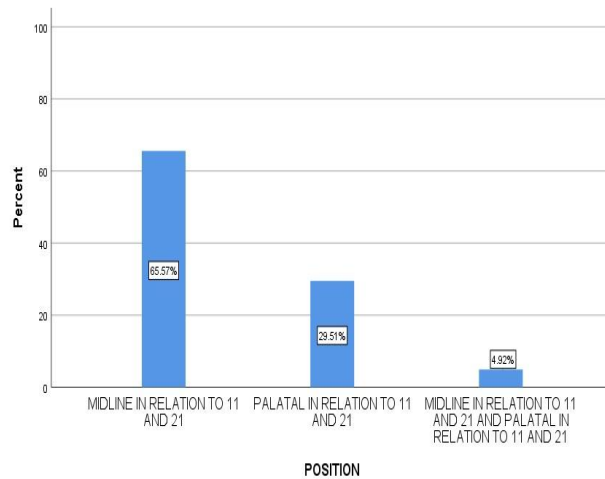


Fig.5: Depicts position of Mesiodens

Figure 5 shows the frequency of position of mesiodens in the oral cavity. Most of the mesiodens are present midline in relation to 11 and 21.

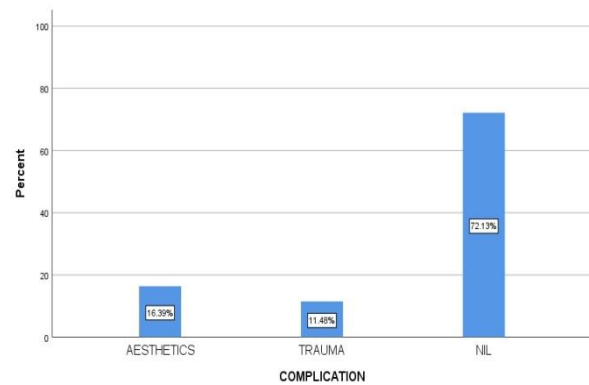
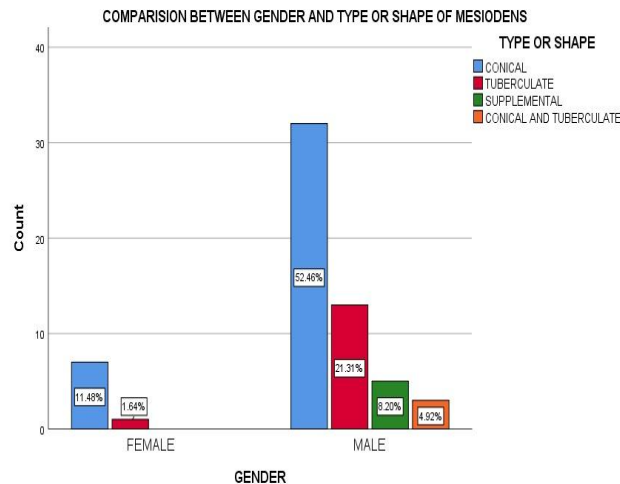


Fig.6: Complication of mesiodens

Figure 6 shows the frequency of complication of the mesiodens. There is no much complication in mesiodens, but there is concern for aesthetics.



Graph 7: Comparison between gender and type or shape mesiodens

Graph 7: Shows the association between the gender and type / shape of mesiodens. It was found to be statistically insignificant, (Chi square test, $P=0.137$)

According to this study, there were a total of 61 patients in the age criteria of 7-80 years of age who reported to the OP during February 2019- March 2020 of Saveetha Dental College. Out of this, almost 34.6% of the patients belong to the age group of 16-25 years. Males have reported highest in number which is about 86.9% who have significant presence of mesiodens. According to Longo et al., (Longo *et al.*, 2020) There was a significant presence of conical shape mesiodens present more common in male population. According to (Maddalone *et al.*, 2018) most of the supernumerary teeth extracted are mesiodens and there were many cases of impaction of mesiodens which also needed surgical removal for better aesthetics. According to Mevlut Celikoglu et al., (Celikoglu, Kamak and Oktay, 2010; Gheena and Ezhilarasan, 2019). There was a significant presence of conical shape mesiodens present in male population than female, it is also proven males are more significant with presence of mesiodens. According to Shubhbrate et al., (Pal *et al.*, 2019) 68% of the patients had conical shape mesiodens out of which 68% of the population is male. According to (Sejdini and Çerkezi, 2018) there was significant cases of mesiodens in children age group of 7-14 years and most of the mesiodens are conical and shape and the most affected populations are males. According to Devi gopakumar et al., (Nair *et al.*, 2014) sex distribution of M:F equal 2:1 which proves that makes have significant prevalence for mesiodens. According to Poornima P et al., (Poornima, Roopa and Shah, 2014; Gifrina Jayaraj, Sherlin, *et al.*, 2015) sex distribution of M:F equal 1:1, in which 61% of the mesiodens are conical in shape. Moreover, to conclude most of the studies compared go to which there is a prevalence of mesiodens in male population significantly higher than the female population and conical shape mesiodens are more prevalent of all other shapes. But still in this study, there is no significant p value to prove that male population is more significant which is due to lack of sample size and minimise sampling bias. Our institution is passionate about high quality evidence based research and has excelled in various fields ((Pc, Marimuthu and Devadoss, 2018; Ramesh *et al.*, 2018; Vijayashree Priyadharsini, Smiline Girija and Paramasivam, 2018; Ezhilarasan, Apoorva and Ashok Vardhan, 2019; Ramadurai *et al.*, 2019; Sridharan *et al.*, 2019b; Vijayashree Priyadharsini, 2019; Chandrasekar *et al.*, 2020; Mathew *et al.*, 2020; R *et al.*, 2020; Samuel, 2021)

CONCLUSION

Within the limitation of the study, the age and gender predilection of mesiodens is more common in males than females. The study should be done on a large scale to get baseline data pertaining to age and gender predilection to the south indian population.

REFERENCES

1. Amin, A. A. et al. (2014) 'Management of impacted permanent maxillary incisors caused by supernumerary tooth: Case report', Sulaimani dental journal, pp. 42–44. doi: 10.17656/sdj.10018.
2. Celikoglu, M., Kamak, H. and Oktay, H. (2010) 'Investigation of transmigrated and impacted maxillary and mandibular canine teeth in an orthodontic patient population', Journal of oral and maxillofacial surgery: official journal of the American Association of Oral and Maxillofacial Surgeons, 68(5), pp. 1001–1006.
3. Chandrasekar, R. et al. (2020) 'Development and validation of a formula for objective assessment of cervical vertebral bone age', Progress in orthodontics, 21(1), p. 38.

4. Choi, H.-M. et al. (2011) 'Quantitative localization of impacted mesiodens using panoramic and periapical radiographs', *Imaging science in dentistry*, 41(2), pp. 63–69.
5. C, P.-A. M. (2015) 'Mesiodens: Etiology, Diagnosis and Treatment: A Literature Review', *BAOJ Dentistry*. doi: 10.24947/baojd/1/1/102.
6. 'Dentigerous Cyst in Association with Impacted Mesiodens in Non Syndromic Patient' (2017) *International Journal of Science and Research (IJSR)*, pp. 1102–1104. doi: 10.21275/art20175510.
7. Deogade, S., Gupta, P. and Ariga, P. (2018) 'Effect of monopoly-coating agent on the surface roughness of a tissue conditioner subjected to cleansing and disinfection: A Contact Profilometric In vitro study', *Contemporary Clinical Dentistry*, p. 122. doi: 10.4103/ccd.ccd_112_18.
8. Dua, K. et al. (2019) 'The potential of siRNA based drug delivery in respiratory disorders: Recent advances and progress', *Drug development research*, 80(6), pp. 714–730.
9. Duraisamy, R. et al. (2019) 'Compatibility of Nonoriginal Abutments With Implants: Evaluation of Microgap at the Implant-Abutment Interface, With Original and Nonoriginal Abutments', *Implant dentistry*, 28(3), pp. 289–295.
10. Ezhilarasan, D. (2018) 'Oxidative stress is bane in chronic liver diseases: Clinical and experimental perspective', *Arab journal of gastroenterology: the official publication of the Pan-Arab Association of Gastroenterology*, 19(2), pp. 56–64.
11. Ezhilarasan, D., Apoorva, V. S. and Ashok Vardhan, N. (2019) 'Syzygium cumini extract induced reactive oxygen species-mediated apoptosis in human oral squamous carcinoma cells', *Journal of oral pathology & medicine: official publication of the International Association of Oral Pathologists and the American Academy of Oral Pathology*, 48(2), pp. 115–121.
12. Ezhilarasan, D., Sokal, E. and Najimi, M. (2018) 'Hepatic fibrosis: It is time to go with hepatic stellate cell-specific therapeutic targets', *Hepatobiliary & pancreatic diseases international: HBPD INT*, 17(3), pp. 192–197.
13. Gharote, H. P. et al. (2011) 'Nonsyndromic double mesiodentes--hidden lambs among normal flock!', *BMJ case reports*, 2011. doi: 10.1136/bcr.07.2011.4420.
14. Gheena, S. and Ezhilarasan, D. (2019) 'Syringic acid triggers reactive oxygen species-mediated cytotoxicity in HepG2 cells', *Human & experimental toxicology*, 38(6), pp. 694–702.
15. Gomathi, A. C. et al. (2020) 'Anticancer activity of silver nanoparticles synthesized using aqueous fruit shell extract of Tamarindus indica on MCF-7 human breast cancer cell line', *Journal of Drug Delivery Science and Technology*, p. 101376. doi: 10.1016/j.jddst.2019.101376.
16. Gupta, V. and Ramani, P. (2016) 'Histologic and immunohistochemical evaluation of mirror image biopsies in oral squamous cell carcinoma', *Journal of oral biology and craniofacial research*, 6(3), pp. 194–197.
17. Hannah, R. et al. (2018) 'Awareness about the use, Ethics and Scope of Dental Photography among Undergraduate Dental Students Dentist Behind the lens', *Research Journal of Pharmacy and Technology*, p. 1012. doi: 10.5958/0974-360x.2018.00189.0.
18. Jangid, K. et al. (2015) 'Ankyloglossia with cleft lip: A rare case report', *Journal of Indian Society of Periodontology*, p. 690. doi: 10.4103/0972-124x.162207.
19. Jayaraj, G., Sherlin, H., et al. (2015) 'Cytomegalovirus and Mucoepidermoid carcinoma: A possible causal relationship? A pilot study', *Journal of Oral and Maxillofacial Pathology*, p. 319. doi: 10.4103/0973-029x.174618.
20. Jayaraj, G., Ramani, P., et al. (2015) 'Inter-observer agreement in grading oral epithelial dysplasia – A systematic review', *Journal of Oral and Maxillofacial Surgery, Medicine, and Pathology*, pp. 112–116. doi: 10.1016/j.ajoms.2014.01.006.
21. Jayaraj, G. et al. (2015) 'Stromal myofibroblasts in oral squamous cell carcinoma and potentially malignant disorders', *Indian journal of cancer*, 52(1), pp. 87–92.
22. Jeevanandan, G. and Govindaraju, L. (2018) 'Clinical comparison of Kedo-S paediatric rotary files vs manual instrumentation for root canal preparation in primary molars: a double blinded randomised clinical trial', *European Archives of Paediatric Dentistry*, pp. 273–278. doi: 10.1007/s40368-018-0356-6.
23. J, P. C. et al. (2018) 'Prevalence and measurement of anterior loop of the mandibular canal using CBCT: A cross sectional study', *Clinical implant dentistry and related research*, 20(4), pp. 531–534.
24. Kokten, G., Balcioglu, H. and Buyukertan, M. (2003) 'Supernumerary fourth and fifth molars: a report of two cases', *The journal of contemporary dental practice*, 4(4), pp. 67–76.
25. Lee, J. et al. (2014) 'The Effect of Early Removal of Mesiodens for the Correction of Central Incisor Rotation', *THE JOURNAL OF THE KOREAN ACADEMY OF PEDTATRIC DENTISTRY*, pp. 64–71. doi: 10.5933/jkapd.2014.41.1.64.
26. Longo, D. L. et al. (2020) 'Factors involved in the treatment sought immediately after traumatic dental injuries in Brazilian children', *Indian journal of dental research: official publication of Indian Society for Dental Research*, 31(1), pp. 109–112.
27. Maddalone, M. et al. (2018) 'Evaluation of Surgical Options for Supernumerary Teeth in the Anterior

- Maxilla', *International journal of clinical pediatric dentistry*, 11(4), pp. 294–298.
28. Malli Sureshbabu, N. et al. (2019) 'Concentrated Growth Factors as an Ingenious Biomaterial in Regeneration of Bony Defects after Periapical Surgery: A Report of Two Cases', *Case reports in dentistry*, 2019, p. 7046203.
 29. Mathew, M. G. et al. (2020) 'Evaluation of adhesion of Streptococcus mutans, plaque accumulation on zirconia and stainless steel crowns, and surrounding gingival inflammation in primary molars: Randomized controlled trial', *Clinical oral investigations*, pp. 1–6.
 30. Mehta, M. et al. (2019) 'Oligonucleotide therapy: An emerging focus area for drug delivery in chronic inflammatory respiratory diseases', *Chemico-biological interactions*, 308, pp. 206–215.
 31. Menon, S. et al. (2018) 'Selenium nanoparticles: A potent chemotherapeutic agent and an elucidation of its mechanism', *Colloids and Surfaces B: Biointerfaces*, pp. 280–292. doi: 10.1016/j.colsurfb.2018.06.006.
 32. Mukhopadhyay, S. (2011) 'Mesiodens: a clinical and radiographic study in children', *Journal of the Indian Society of Pedodontics and Preventive Dentistry*, 29(1), pp. 34–38.
 33. Nair, V. et al. (2014) 'Prevalence of supernumerary teeth in permanent dentition among patients attending a dental college in South Kerala: A pilot study', *Journal of Indian Academy of Oral Medicine and Radiology*, p. 42. doi: 10.4103/0972-1363.141854.
 34. Pal, S. et al. (2019) 'Prevalence and type of mesiodens among 3–14-year-old children in West Bengal: An institutional study', *International Journal of Pedodontic Rehabilitation*, p. 9. doi: 10.4103/ijpr.ijpr_33_18.
 35. Panchal, V., Jeevanandan, G. and Subramanian, E. M. G. (2019) 'Comparison of post-operative pain after root canal instrumentation with hand K-files, H-files and rotary Kedo-S files in primary teeth: a randomised clinical trial', *European archives of paediatric dentistry: official journal of the European Academy of Paediatric Dentistry*, 20(5), pp. 467–472.
 36. Pc, J., Marimuthu, T. and Devadoss, P. (2018) 'Prevalence and measurement of anterior loop of the mandibular canal using CBCT: A cross sectional study', *Clinical implant dentistry and related research*. Available at: <https://europepmc.org/article/med/29624863>.
 37. Poornima, P., Roopa, K. B. and Shah, R. (2014) 'Composite Mesiodens with Impacted Conical Mesiodens: A Case Report', *Journal of Dental Panacea*, p. 1. doi: 10.15636/jdp/2014/v1i2/58425.
 38. Prabakar, J. et al. (2018) 'Comparative Evaluation of Retention, Cariostatic Effect and Discoloration of Conventional and Hydrophilic Sealants - A Single Blinded Randomized Split Mouth Clinical Trial', *Contemporary clinical dentistry*, 9(Suppl 2), pp. S233–S239.
 39. Primosch, R. E. (1981) 'Anterior supernumerary teeth--assessment and surgical intervention in children', *Pediatric dentistry*, 3(2), pp. 204–215.
 40. Rajendran, R. et al. (2019) 'Comparative Evaluation of Remineralizing Potential of a Paste Containing Bioactive Glass and a Topical Cream Containing Casein Phosphopeptide-Amorphous Calcium Phosphate: An in Vitro Study', *Pesquisa Brasileira em Odontopediatria e Clínica Integrada*, pp. 1–10. doi: 10.4034/pboci.2019.191.61.
 41. Rajeshkumar, S. et al. (2018) 'Biosynthesis of zinc oxide nanoparticles using *Mangifera indica* leaves and evaluation of their antioxidant and cytotoxic properties in lung cancer (A549) cells', *Enzyme and microbial technology*, 117, pp. 91–95.
 42. Rajeshkumar, S. et al. (2019) 'Antibacterial and antioxidant potential of biosynthesized copper nanoparticles mediated through *Cissus arnotiana* plant extract', *Journal of photochemistry and photobiology. B, Biology*, 197, p. 111531.
 43. Ramadurai, N. et al. (2019) 'Effectiveness of 2% Articaine as an anesthetic agent in children: randomized controlled trial', *Clinical oral investigations*, 23(9), pp. 3543–3550.
 44. Ramakrishnan, M., Dhanalakshmi, R. and Subramanian, E. M. G. (2019) 'Survival rate of different fixed posterior space maintainers used in Paediatric Dentistry - A systematic review', *The Saudi dental journal*, 31(2), pp. 165–172.
 45. Ramesh, A. et al. (2018) 'Comparative estimation of sulfiredoxin levels between chronic periodontitis and healthy patients - A case-control study', *Journal of periodontology*, 89(10), pp. 1241–1248.
 46. Ravn, J. J. (1971) 'Aplasia, supernumerary teeth and fused teeth in the primary dentition. An epidemiologic study', *Scandinavian journal of dental research*, 79(1), pp. 1–6.
 47. R, H. et al. (2020) 'CYP2 C9 polymorphism among patients with oral squamous cell carcinoma and its role in altering the metabolism of benzo[a]pyrene', *Oral Surgery, Oral Medicine, Oral Pathology and Oral Radiology*, pp. 306–312. doi: 10.1016/j.oooo.2020.06.021.
 48. Rosenzweig, K. A. and Garbarski, D. (1965) 'Numerical aberrations in the permanent teeth of grade school children in Jerusalem', *American Journal of Physical Anthropology*, pp. 277–283. doi: 10.1002/ajpa.1330230315.
 49. Samuel, S. R. (2021) 'Can 5-year-olds sensibly self-report the impact of developmental enamel defects on their quality of life?', *International journal of paediatric dentistry / the British Paedodontic Society [and] the International Association of Dentistry for Children*, 31(2), pp. 285–286.

50. Samuel, S. R., Acharya, S. and Rao, J. C. (2020) 'School Interventions-based Prevention of Early-Childhood Caries among 3-5-year-old children from very low socioeconomic status: Two-year randomized trial', *Journal of public health dentistry*, 80(1), pp. 51–60.
51. Sejdini, M. and Çerkezi, S. (2018) 'Dental Number Anomalies and Their Prevalence According To Gender and Jaw in School Children 7 To 14 Years', *Open access Macedonian journal of medical sciences*, 6(5), pp. 867–873.
52. Sharma, P. et al. (2019) 'Emerging trends in the novel drug delivery approaches for the treatment of lung cancer', *Chemico-biological interactions*, 309, p. 108720.
53. Shekhar, M. G. (2012) 'Characteristics of premaxillary supernumerary teeth in primary and mixed dentitions: a retrospective analysis of 212 cases', *Journal of Investigative and Clinical Dentistry*, pp. 221–224. doi: 10.1111/j.2041-1626.2012.00118.x.
54. Sherlin, H. et al. (2015) 'Expression of CD 68, CD 45 and human leukocyte antigen-DR in central and peripheral giant cell granuloma, giant cell tumor of long bones, and tuberculous granuloma: An immunohistochemical study', *Indian Journal of Dental Research*, p. 295. doi: 10.4103/0970-9290.162872.
55. Shree, K. H. et al. (2019) 'Saliva as a Diagnostic Tool in Oral Squamous Cell Carcinoma – a Systematic Review with Meta Analysis', *Pathology & Oncology Research*, pp. 447–453. doi: 10.1007/s12253-019-00588-2.
56. Sivaramakrishnan, S. M. and Ramani, P. (2015) 'Study on the Prevalence of Eruption Status of Third Molars in South Indian Population', *Biology and Medicine*. doi: 10.4172/0974-8369.1000245.
57. Sridharan, G. et al. (2019a) 'Evaluation of salivary metabolomics in oral leukoplakia and oral squamous cell carcinoma', *Journal of Oral Pathology & Medicine*, pp. 299–306. doi: 10.1111/jop.12835.
58. Sridharan, G. et al. (2019b) 'Evaluation of salivary metabolomics in oral leukoplakia and oral squamous cell carcinoma', *Journal of oral pathology & medicine: official publication of the International Association of Oral Pathologists and the American Academy of Oral Pathology*, 48(4), pp. 299–306.
59. Sridharan, G., Ramani, P. and Patankar, S. (2017) 'Serum metabolomics in oral leukoplakia and oral squamous cell carcinoma', *Journal of cancer research and therapeutics*, 13(3), pp. 556–561.
60. Swathy, S., Gheena, S. and Varsha, S. L. (2015) 'Prevalence of pulp stones in patients with history of cardiac diseases', *Research Journal of Pharmacy and Technology*, p. 1625. doi: 10.5958/0974-360x.2015.00291.7.
61. Taylor, G. S. (1972) 'Characteristics of supernumerary teeth in the primary and permanent dentition', *The Dental practitioner and dental record*, 22(5), pp. 203–208.
62. Thangaraj, S. V. et al. (2016) 'Molecular Portrait of Oral Tongue Squamous Cell Carcinoma Shown by Integrative Meta-Analysis of Expression Profiles with Validations', *PloS one*, 11(6), p. e0156582.
63. Varghese, S. S., Ramesh, A. and Veeraiyan, D. N. (2019) 'Blended Module-Based Teaching in Biostatistics and Research Methodology: A Retrospective Study with Postgraduate Dental Students', *Journal of dental education*, 83(4), pp. 445–450.
64. Vecchione Gurgel, C. et al. (2013) 'Bilateral Mesiodens in Monozygotic Twins: 3D Diagnostic and Management', *Case reports in dentistry*, 2013, p. 193614.
65. Vijayashree Priyadharsini, J. (2019) 'In silico validation of the non-antibiotic drugs acetaminophen and ibuprofen as antibacterial agents against red complex pathogens', *Journal of periodontology*, 90(12), pp. 1441–1448.
66. Vijayashree Priyadharsini, J., Smiline Girija, A. S. and Paramasivam, A. (2018) 'In silico analysis of virulence genes in an emerging dental pathogen *A. baumannii* and related species', *Archives of oral biology*, 94, pp. 93–98.
67. Vishnu Prasad, S. et al. (2018) 'Report on oral health status and treatment needs of 5-15 years old children with sensory deficits in Chennai, India', *Special care in dentistry: official publication of the American Association of Hospital Dentists, the Academy of Dentistry for the Handicapped, and the American Society for Geriatric Dentistry*, 38(1), pp. 58–59.
68. Viveka, T. S. et al. (2016) 'p53 Expression Helps Identify High Risk Oral Tongue Premalignant Lesions and Correlates with Patterns of Invasive Tumour Front and Tumour Depth in Oral Tongue Squamous Cell Carcinoma Cases', *Asian Pacific Journal of Cancer Prevention*, pp. 189–195. doi: 10.7314/apjcp.2016.17.1.189.
69. Wahab, P. U. A. et al. (2018) 'Scalpel Versus Diathermy in Wound Healing After Mucosal Incisions: A Split-Mouth Study', *Journal of oral and maxillofacial surgery: official journal of the American Association of Oral and Maxillofacial Surgeons*, 76(6), pp. 1160–1164.
70. Zhao, L. et al. (2020) 'Analysis of the distribution of supernumerary teeth and the characteristics of mesiodens in Bengbu, China: a retrospective study', *Oral radiology*. doi: 10.1007/s11282-020-00432-3.