

---

## Estimation of prevalence of gingival enlargement - a population-based study

---

KALAIVANI N.<sup>1</sup>, DR. N.D. JAYAKUMAR<sup>2\*</sup>, MAHESH RAMAKRISHNAN.<sup>3</sup>

<sup>1</sup>Saveetha Dental College and Hospitals, Saveetha Institute of Medical and Technical Sciences, Saveetha University., Chennai - 77.

<sup>2</sup>Dean of faculty, Professor and Head, Department of Periodontics, Saveetha Dental College and Hospitals, Saveetha Institute of Medical and Technical Sciences, Saveetha University, Chennai - 77.

<sup>3</sup>Reader, Department of Pediatric and Preventive Dentistry, Saveetha Dental College and Hospitals, Saveetha Institute of Medical and Technical Sciences, Saveetha University, Chennai - 77

\*Corresponding Author

Email ID: jayakumarnd@saveetha.com

---

**Abstract:** Gingival enlargement is an increase in the size of the gingiva. It is also known as the gingival hyperplasia or hypertrophy. They can be categorised based on their etiology, pathogenesis, location, size and extent. Inflammatory gingival enlargement is a most common form and clinically present as soft and discolored gingiva. Drug induced gingival enlargement is a well recognised adverse effect of certain systemic medications. Calcium channel blockers, Anticonvulsants and Immunosuppressants are frequently implicated drugs in the etiology of drug induced enlargement. The aim of the study is to assess the prevalence of gingival enlargement and its distribution.

**Objective:**

- To assess the prevalence of inflammatory and drug induced enlargement.
- To compare the prevalence of gingival enlargement in different age groups.
- To compare the prevalence of gingival enlargement in male and female.
- To compare the prevalence of gingival enlargement in response to different types of drugs.

The study was a retrospective, University based study. Case sheets of patients visiting the dental outpatient ward June 2019 to March 2020 were collected. Patients diagnosed with gingival enlargement were sorted and tabulated in Microsoft excel sheet and analysed using SPSS software. In the present study, out of 40,000 patients, the prevalence of inflammatory enlargement was found to be 0.1% and the drug induced enlargement was 0.03%. Drug induced enlargement was more prevalent in males than in females, whereas inflammatory enlargement was more prevalent in females than males, there was no statistically significant difference in the prevalence rate between age groups ( $p= 0.362$ ) and gender ( $p= 0.210$ ). On comparing the drugs, phenytoin was consumed by one third of the population (43%) but had a higher prevalence rate of 65% than antihypertensive drugs (28% )and immunosuppressants (7% ).

**Keywords:** anticonvulsants, chronic and acute enlargement, calcium channel blocker, gingival enlargement, immunosuppressants, inflammation, Innovation

---

### INTRODUCTION

Gingival enlargement or gingival overgrowth - a common form of gingival disease is characterized by an increase in the size of gingiva. Gingival enlargement can be classified into various forms, based on their etiology, they can be classified as inflammatory, drug induced, those that are associated with systemic disease, neoplastic or false enlargement. Based on the location, they can be marginal, papillary or diffuse. Based on distribution it can be localised or generalized.(Agrawal, 2015)

Inflammatory gingival enlargement may be categorised as acute or chronic, whereas chronic changes are more common. Drug induced gingival enlargement remains a significant problem for the dentist in general and periodontologist. It may interfere with aesthetics, mastication, and even speech. An increasing number of medications are associated with gingival overgrowth. Currently more than 20 prescription medications are associated with gingival enlargement.

Drugs that are associated with gingival enlargement can be broadly classified into three categories - anticonvulsants, calcium channel blockers, immunosuppressants. The first case of phenytoin induced gingival enlargement was reported by Hassel et al.(Hassell, 1981) Other anticonvulsants like sodium valproate, phenobarbitone, have also been associated with gingival enlargement but have been rarely reported.(Hallmon and Rossmann, 1999) Calcium channel blockers induced gingival enlargement was first reported in 1984 by Hederman

in patients treated with nifedipine.(Barclay et al., 1992; Ellis et al., 1999) Amlodipine induced gingival enlargement was first reported by Seymour in 1994.(Ellis et al., 2006) Cyclosporine induced gingival enlargement was first reported by Rateitschak in 1983.(Rateitschak-Plüss and Hefti, 1983) . Although the pharmacological effect of each of these drugs is different towards their primary target site, all of them seem to act similarly on their secondary target site that is the gingival connective tissue. Clinical manifestation of drug induced enlargement usually appears within 1 to 3 months, after initiation of these medications. Gingival overgrowth normally begins in the interdental papilla and is more frequently found in the anterior segment of the labial surface.

The distribution of inflammatory enlargement is usually generalised or localised. Inflammatory enlargement can be plaque induced and non plaque induced. Plaque induced can be generalised and non plaque induced is localised to the contributing etiological factors like restoration that is impinging on the gingiva, prosthesis confined to a specific tooth. Whereas, drug induced enlargement is usually generalised.The gingival lobulations are formed gradually that may appear inflamed or fibrotic in nature. The presence of enlargement makes plaque control difficult, resulting in a secondary inflammatory process, this is known as combined gingival disease. The difficulty in maintaining oral hygiene leads to further plaque accumulation and inflammation, the presence of previous inflammatory factors like cytokines, TNF - alpha, endothelins and IL-21 favours the action of drugs on the gingival connective tissue, perpetuating this cycle.(Agrawal et al., 2017; Khalid et al., 2016, 2017; Mootha et al., 2016; Varghese et al., 2015)

Besides gingival enlargement being an entity in periodontal disease, it may appear as a clinical feature in periodontitis. Periodontitis is a multifactorial disease with primary etiological factors being plaque and microflora. The treatment of periodontitis is a multidisciplinary approach, starting from synthetic drugs like antibiotics to regenerative methods(Ravi et al., 2017) like PRF,(Panda et al., 2014; Thamaraiselvan et al., 2015) growth factors and stem cells.(Avinash et al., 2017) Disadvantages of these methods have lead to plant based studies, where herbs are used as antimicrobials agents. Effectiveness of various herbal mouthwashes are being tested against periodontal disease.(Ramamurthy and Mg, 2018; Ramesh, Sheeja Saji Varghese, et al., 2016)

The prevalence rate of gingival enlargement in school children in Karnataka was assessed and found that it was predominantly inflammatory and was caused due to improper oral hygiene practices (Krishna et al., 2014). However, this findings may vary in individuals with different age groups and genders due to factors like hormones, stress etc. Our department is passionate about research we have published numerous high quality articles in this domain over the past years (Abraham et al., 2005; Arja et al., 2013; Devaki et al., 2009; Ezhilarasan, 2018; Ezhilarasan et al., 2018; J et al., 2018; Krishnaswamy et al., 2020; Malli Sureshbabu et al., 2019; Manivannan et al., 2017; Mehta et al., 2019; Neelakantan et al., 2010, 2015; Ramamoorthi et al., 2015; Ramshankar et al., 2014; Ravindiran and Praveenkumar, 2018; Samuel et al., 2020; Sathish and Karthick, 2020; Sumathi et al., 2014; Surapaneni et al., 2014; Surapaneni and Jainu, 2014)Hence, it is essential to assess the prevalence of gingival disease and its distribution in different populations and to assess the various etiological factors that caused enlargement.

## MATERIALS AND METHODS

**Study setting:** This is a retrospective, university based study. Case sheets of 40,000 patients who reported to the dental outpatient ward from June 2019 to March 2020 were evaluated. Patients diagnosed with gingival enlargement were sorted. Ethical clearance was obtained from the Institutional Ethical Committee - Saveetha Dental College (SDC/SIHEC/2020/DIASDATA/0619-0320).

**Sampling:** Patients diagnosed with gingival enlargement and those with under medication of anticonvulsants, antihypertensives and immunosuppressants were collected. Case sheets with incomplete data and repeated cases were excluded from the study. Further sorting was done with respect to age groups, gender distribution, drug used and type of enlargement. The data were cross verified by another reviewer to minimise the sampling bias.

**Data Collection:** Data's collected were tabulated in Microsoft Excel sheet.

**Statistical Analysis:** The Excel sheet was transferred to the host computer and processed in SPSS. Chi-square test was done to analyse the association and correlation with age and gender as independent variables and type of enlargement, clinical site as dependent variables.

## RESULTS AND DISCUSSION

Out of 40,000 patients, the prevalence rate was calculated to be 0.1025%. The inflammatory enlargement was further categorised as generalised and localised, in which less than 40% had generalized gingival enlargement. This shows inflammatory enlargement is confined to a localised region.

On analysing the drug induced enlargement, 332 patients were under medication of anticonvulsant, calcium channel blockers and immunosuppressants. 33% patients were under phenytoin, 65% patients were under amlodipine, 0.6% patients under nifedipine and 0.3% patients under cyclosporine. The prevalence rate was calculated to be 0.035%.

The prevalence of inflammatory enlargement is higher compared to drug induced enlargement because, out of 40,000 patients 0.83% of the patients consumed either of the listed drugs. Inflammatory enlargement may be due

to a long standing bacterial plaque that produces constant irritation leading to continuous infiltration of neutrophils and their sequelae.

In the present, out of 332 patients, about one third (33%) consumed phenytoin and about 66% of the patients consumed antihypertensive drugs. In contrast, the gingival enlargement was prevalent in patients who consumed phenytoin with 65% frequency rate. Whereas enlargement induced by antihypertensive drugs is 28% (graph 1). Several theories have been put forward to explain the action of phenytoin on the gingiva that include, decreased collagen degradation. Generally, the mechanism of collagen degradation occurs in two pathways : By secretion of collagenase, Drugs like phenytoin reduces calcium influx into the cell ,leading to the reduction in the uptake of folic acid, ultimately limiting the production of collagenases. 2. Intercellular pathway , where the alpha-2 beta-1 integrin acts as a specific receptor for the adhesion of fibroblast and collagen. Phenytoin is proved to diminish the expression of alpha-2 beta-1 integrin. Hence, there is increased deposition of collagen leading to enlargement of the gingiva. In addition to the activity of phenytoin, most of the epileptic patients are not capable of maintaining proper oral hygiene. There will be increased deposition of plaque leading to a combined disease. (Corrêa et al., 2011)

In a study conducted by Jogersen et al, (Jorgensen, 1997) prevalence of amlodipine induced gingival enlargement was 3.3%. In another study conducted by Soumya et al, (Gopal et al., 2015) the frequency of occurrence of gingival enlargement in patients under medication of antihypertensive drugs was 27.1 %. In a study conducted by Ellios et al, the prevalence of amlodipine induced gingival overgrowth was 1.7%. The prevalence of hypertension is higher (29.8%) in India. Hence the patients under medication for hypertension is also higher. However not all patients under medication for hypertension have gingival enlargement and may attribute to the vulnerability of an individual's gingival tissue. (Kavarthapu and Thamaraiselvan, 2018; Ramesh et al., 2017) The action of antihypertensive drugs on gingiva is similar to that of phenytoin. It has also been proposed that gingival fibroblast enhances the synthesis of collagenous proteins when exposed to antihypertensive drugs and other pro inflammatory cytokines like interleukin 1- beta. Moreover, periodontal disease as such is a risk factor for cardiac disease. Microflora Research has shown that the periodontal microflora is similar to that found in the atheromatous plaque. Hence, it is important to manage periodontal disease effectively. (Ramesh, Sheeja S. Varghese, et al., 2016) The association between the age groups and type of enlargement was assessed (graph 2). There is no statistically significant association between the age groups and enlargement. However, in drug induced enlargement phenytoin induced enlargement was prevalent in younger and calcium channel blockers induced enlargement was common in older age groups. In a study conducted by George et al (Goyal, 2017) it is stated that phenytoin induced gingival overgrowth was more susceptible to children and adults younger than 30 years of age. Another study conducted by Means et al states that phenytoin induced enlargement was more common in children and young adults. These are similar to our present study. In a study conducted by Jayanti et al about amlodipine induced gingival enlargement, it was reported that amlodipine induced gingival enlargement was more prevalent in elderly people, which is also similar to our study. (Ramesh et al., 2019)

The association of the type of enlargement and gender groups was assessed (graph 3). There is no statistically significant association between the gender and type of enlargement. The prevalence of drug induced enlargement was more common in males whereas inflammatory enlargement was increased in females. George et al stated that the drug induced enlargement was more common in males than in females. Other studies conducted by Soumya et al, Barack et al (Barak et al., 1987), Thomson et al (Thomason et al., 1995) shows that males have increased prevalence and drug induced gingival enlargement. An animal study done in rats have also stated the prevalence of nifedipine induced gingival enlargement is more common in males. However puberty associated gingival enlargement is more common in females than males. Conditioned enlargement like enlargement in puberty and pregnancy are confined to the female population due to the influence of female sex hormones on the gingival connective tissue. Estrogen is mainly responsible for alterations in blood vessels and progesterone stimulates the production of inflammatory mediators. The hormones increase the vascular permeability leading to gingival edema, an increased inflammatory response to dental plaque. The subgingival microbiota may also undergo changes, which include an increase in the *Prevotella intermedia*. It is believed that *Prevotella intermedia* uses female sex hormones as a source of nutrients. (Khosla et al., 2012; Markou et al., 2009)

The oral hygiene status of patients with enlargement was assessed (graph 4). There was no statistically significant association between the oral hygiene status and the type of enlargement. However, we could see most of them had fair and poor oral hygiene status. Plaque and calculus is one of the main etiological factors for inflammatory enlargement, however on assessing the drug induced enlargement it can be a secondary factor. Inabilities of an individual to maintain proper oral hygiene can lead to plaque accumulation, studies have proved that epileptic patients have poor oral hygiene due to improper maintenance. In these cases, the inability of the patients, gingival contour, gingival bleeding, pain can lead to poor oral hygiene status (Joshi et al., 2017).

## CONCLUSION

From the present study, we can conclude that the prevalence of inflammatory enlargement is higher than drug-induced enlargement. Among the drugs included in our study, Gingival enlargement was more prevalent in

individuals under medication of anticonvulsants. However there is no statistically significant difference in the prevalence rate of gingival enlargement with different age groups and gender.

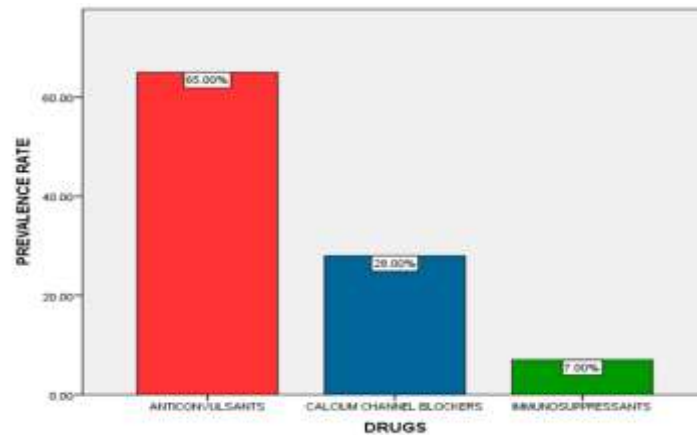
## REFERENCES

1. Abraham S, Kumar MS, Sehgal PK, et al. (2005) Evaluation of the inhibitory effect of triphala on PMN-type matrix metalloproteinase (MMP-9). *Journal of periodontology* 76(4): 497–502.
2. Agrawal AA (2015) Gingival enlargements: Differential diagnosis and review of literature. *World journal of clinical cases* 3(9): 779–788.
3. Agrawal C, Pudakalakatti P, Shah MP, et al. (2017) Detection and Assessment of Human Cytomegalo Virus, Epstein -Barr Virus -1 and Herpes Simplex Virus in Patients with Chronic Periodontitis of Varying Pocket Depths. *RUHS Journal of Health Science*. DOI: 10.37821/ruhsjhs.2.4.2017.174-180.
4. Arja C, Surapaneni KM, Raya P, et al. (2013) Oxidative stress and antioxidant enzyme activity in South Indian male smokers with chronic obstructive pulmonary disease. *Respirology* 18(7): 1069–1075.
5. Avinash K, Malaippan S and Dooraiswamy JN (2017) Methods of Isolation and Characterization of Stem Cells from Different Regions of Oral Cavity Using Markers: A Systematic Review. *International journal of stem cells* 10(1): 12–20.
6. Barak S, Engelberg IS and Hiss J (1987) Gingival hyperplasia caused by nifedipine. *Histopathologic findings*. *Journal of periodontology* 58(9): 639–642.
7. Barclay S, Thomason JM, Idle JR, et al. (1992) The incidence and severity of nifedipine-induced gingival overgrowth. *Journal of Clinical Periodontology*. DOI: 10.1111/j.1600-051x.1992.tb00650.x.
8. Corrêa JD, Queiroz-Junior CM, Costa JE, et al. (2011) Phenytoin-induced gingival overgrowth: a review of the molecular, immune, and inflammatory features. *ISRN dentistry* 2011: 497850.
9. Devaki T, Sathivel A and BalajiRaghavendran HR (2009) Stabilization of mitochondrial and microsomal function by polysaccharide of *Ulva lactuca* on D-Galactosamine induced hepatitis in rats. *Chemico-biological interactions* 177(2): 83–88.
10. Ellis JS, Seymour RA, Steele JG, et al. (1999) Prevalence of gingival overgrowth induced by calcium channel blockers: a community-based study. *Journal of periodontology* 70(1): 63–67.
11. Ellis JS, Thomason JM and Seymour RA (2006) The management of drug-induced gingival overgrowth. *Journal of clinical*. Wiley Online Library. Available at: <https://onlinelibrary.wiley.com/doi/abs/10.1111/j.1600-051X.2006.00930.x>.
12. Ezhilarasan D (2018) Oxidative stress is bane in chronic liver diseases: Clinical and experimental perspective. *Arab journal of gastroenterology: the official publication of the Pan-Arab Association of Gastroenterology* 19(2): 56–64.
13. Ezhilarasan D, Sokal E and Najimi M (2018) Hepatic fibrosis: It is time to go with hepatic stellate cell-specific therapeutic targets. *Hepatobiliary & pancreatic diseases international: HBPD INT* 17(3): 192–197.
14. Gopal S, Joseph R, Santhosh VC, et al. (2015) Prevalence of gingival overgrowth induced by antihypertensive drugs: A hospital-based study. *Journal of Indian Society of Periodontology* 19(3): 308–311.
15. Goyal L (2017) Periodontal Management of Phenytoin Induced Gingival Enlargement: A Case Report. *Journal of Dental Health, Oral Disorders & Therapy*. DOI: 10.15406/jdhodt.2017.08.00271.
16. Hallmon WW and Rossmann JA (1999) The role of drugs in the pathogenesis of gingival overgrowth. A collective review of current concepts. *Periodontology* 2000 21: 176–196.
17. Hassell TM (1981) Epilepsy and the oral manifestations of phenytoin therapy. *Monographs in oral science* 9: 1–205.
18. Jorgensen MG (1997) Prevalence of amlodipine-related gingival hyperplasia. *Journal of periodontology*. Wiley Online Library. Available at: <https://aap.onlinelibrary.wiley.com/doi/abs/10.1902/jop.1997.68.7.676>.
19. Joshi NH, Deshpande AN, Deshpande NC, et al. (2017) Comparative evaluation of oral hygiene status and gingival enlargement among epileptic and healthy children as related to various antiepileptic drugs. *Journal of Indian Society of Periodontology* 21(2): 125–129.
20. J PC, Marimuthu T, C K, et al. (2018) Prevalence and measurement of anterior loop of the mandibular canal using CBCT: A cross sectional study. *Clinical implant dentistry and related research* 20(4): 531–534.
21. Kavarthapu A and Thamaraiselvan M (2018) Assessing the variation in course and position of inferior alveolar nerve among south Indian population: A cone beam computed tomographic study. *Indian journal of dental research: official publication of Indian Society for Dental Research* 29(4): 405–409.
22. Khalid W, Vargheese SS, Lakshmanan R, et al. (2016) Role of endothelin-1 in periodontal diseases: A structured review. *Indian journal of dental research: official publication of Indian Society for Dental Research* 27(3): 323–333.
23. Khalid W, Vargheese SS, Sankari M, et al. (2017) Comparison of Serum Levels of Endothelin-1 in Chronic Periodontitis Patients Before and After Treatment. *Journal of clinical and diagnostic research: JCDR* 11(4): ZC78–ZC81.
24. Khosla S, Oursler MJ and Monroe DG (2012) Estrogen and the skeleton. *Trends in endocrinology and*

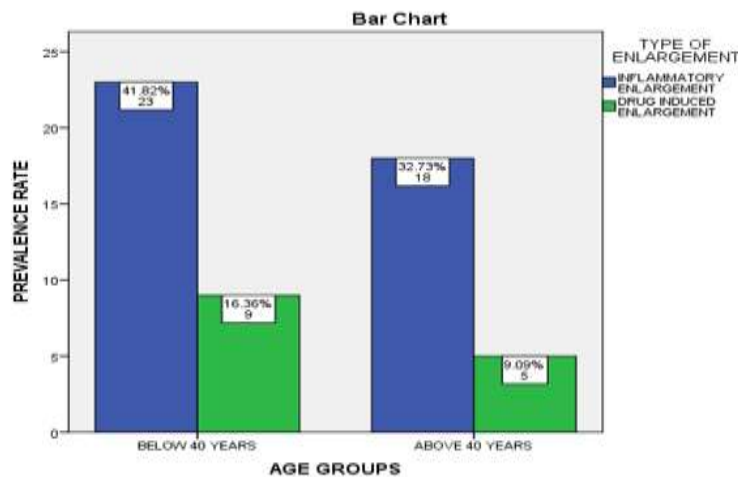
- metabolism: TEM 23(11): 576–581.
25. Krishna KB, Raju PK, Chitturi RR, et al. (2014) Prevalence of gingival enlargement in Karnataka school going children. *Journal of international oral health : JIOH* 6(1): 106–110.
  26. Krishnaswamy H, Muthukrishnan S, Thanikodi S, et al. (2020) Investigation of air conditioning temperature variation by modifying the structure of passenger car using computational fluid dynamics. *Thermal Science* 24(1 Part B): 495–498.
  27. Malli Sureshbabu N, Selvarasu K, V JK, et al. (2019) Concentrated Growth Factors as an Ingenious Biomaterial in Regeneration of Bony Defects after Periapical Surgery: A Report of Two Cases. *Case reports in dentistry* 2019: 7046203.
  28. Manivannan I, Ranganathan S, Gopalakannan S, et al. (2017) Tribological and surface behavior of silicon carbide reinforced aluminum matrix nanocomposite. *Surfaces and Interfaces* 8. Elsevier: 127–136.
  29. Markou E, Eleana B, Lazaros T, et al. (2009) The influence of sex steroid hormones on gingiva of women. *The open dentistry journal* 3: 114–119.
  30. Mehta M, Deeksha, Tewari D, et al. (2019) Oligonucleotide therapy: An emerging focus area for drug delivery in chronic inflammatory respiratory diseases. *Chemico-biological interactions* 308: 206–215.
  31. Mootha A, Malaiappan S, Jayakumar ND, et al. (2016) The Effect of Periodontitis on Expression of Interleukin-21: A Systematic Review. *International journal of inflammation* 2016: 3507503.
  32. Neelakantan P, ChandanaSubbarao, VenkataSubbarao C, et al. (2010) Root and Canal Morphology of Mandibular Second Molars in an Indian Population. *Journal of endodontics* 36(8). Elsevier: 1319–1322.
  33. Neelakantan P, Cheng CQ, Ravichandran V, et al. (2015) Photoactivation of curcumin and sodium hypochlorite to enhance antibiofilm efficacy in root canal dentin. *Photodiagnosis and photodynamic therapy* 12(1): 108–114.
  34. Panda S, Jayakumar ND, Sankari M, et al. (2014) Platelet rich fibrin and xenograft in treatment of intrabony defect. *Contemporary clinical dentistry* 5(4): 550–554.
  35. Ramamoorthi S, Nivedhitha MS and Divyanand MJ (2015) Comparative evaluation of postoperative pain after using endodontic needle and EndoActivator during root canal irrigation: A randomised controlled trial. *Australian endodontic journal: the journal of the Australian Society of Endodontology Inc* 41(2): 78–87.
  36. Ramamurthy J and Mg V (2018) COMPARISON OF EFFECT OF HIORA MOUTHWASH VERSUS CHLORHEXIDINE MOUTHWASH IN GINGIVITIS PATIENTS: A CLINICAL TRIAL. *Asian J Pharm Clin Res* 11(7): 84–88.
  37. Ramesh A, Varghese Sheeja S., Jayakumar ND, et al. (2016) Chronic obstructive pulmonary disease and periodontitis – unwinding their linking mechanisms. *Journal of Oral Biosciences*. DOI: 10.1016/j.job.2015.09.001.
  38. Ramesh A, Varghese Sheeja Saji, Doraiswamy JN, et al. (2016) Herbs as an antioxidant arsenal for periodontal diseases. *Journal of intercultural ethnopharmacology* 5(1): 92–96.
  39. Ramesh A, Ravi S and Kaarthikeyan G (2017) Comprehensive rehabilitation using dental implants in generalized aggressive periodontitis. *Journal of Indian Society of Periodontology* 21(2): 160–163.
  40. Ramesh A, Vellayappan R, Ravi S, et al. (2019) Esthetic lip repositioning: A cosmetic approach for correction of gummy smile - A case series. *Journal of Indian Society of Periodontology* 23(3): 290–294.
  41. Ramshankar V, Soundara VT, Shyamsundar V, et al. (2014) Risk stratification of early stage oral tongue cancers based on HPV status and p16 immunoexpression. *Asian Pacific journal of cancer prevention: APJCP* 15(19): 8351–8359.
  42. Rateitschak-Plüss EM and Hefti A (1983) Initial observation that cyclosporin-A induces gingival enlargement in man. *Journal of clinical*. Wiley Online Library. Available at: <https://onlinelibrary.wiley.com/doi/abs/10.1111/j.1600-051X.1983.tb01272.x>.
  43. Ravindiran M and Praveenkumar C (2018) Status review and the future prospects of CZTS based solar cell – A novel approach on the device structure and material modeling for CZTS based photovoltaic device. *Renewable and Sustainable Energy Reviews* 94. Pergamon: 317–329.
  44. Ravi S, Malaiappan S and Varghese S (2017) Additive Effect of Plasma Rich in Growth Factors With Guided Tissue Regeneration in Treatment of Intrabony Defects in Patients With Chronic Periodontitis: A Split .... *Journal of*. Wiley Online Library. Available at: <https://aap.onlinelibrary.wiley.com/doi/abs/10.1902/jop.2017.160824>.
  45. Samuel SR, Acharya S and Rao JC (2020) School Interventions-based Prevention of Early-Childhood Caries among 3-5-year-old children from very low socioeconomic status: Two-year randomized trial. *Journal of public health dentistry* 80(1): 51–60.
  46. Sathish T and Karthick S (2020) Wear behaviour analysis on aluminium alloy 7050 with reinforced SiC through taguchi approach. *Journal of Materials Research and Technology* 9(3). Elsevier: 3481–3487.
  47. Sumathi C, MohanaPriya D, Swarnalatha S, et al. (2014) Production of prodigiosin using tannery fleshing and evaluating its pharmacological effects. *TheScientificWorldJournal* 2014: 290327.
  48. Surapaneni KM and Jainu M (2014) Comparative effect of pioglitazone, quercetin and hydroxy citric acid on

the status of lipid peroxidation and antioxidants in experimental non-alcoholic steatohepatitis. *Journal of physiology and pharmacology: an official journal of the Polish Physiological Society* 65(1): 67–74.

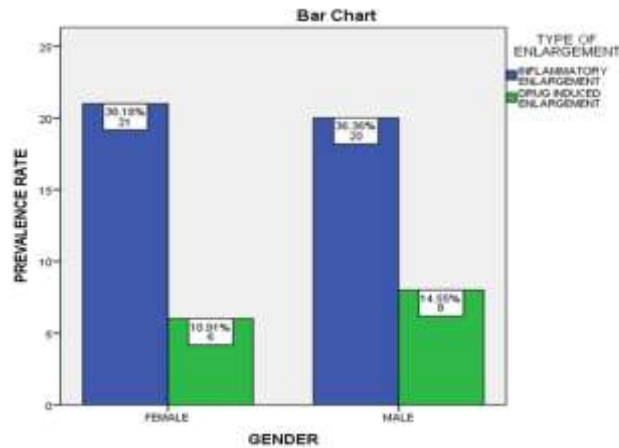
49. Surapaneni KM, Priya VV and Mallika J (2014) Pioglitazone, quercetin and hydroxy citric acid effect on cytochrome P450 2E1 (CYP2E1) enzyme levels in experimentally induced non alcoholic steatohepatitis (NASH). *European review for medical and pharmacological sciences* 18(18): 2736–2741.
50. Thamaraiselvan M, Elavarasu S, Thangakumaran S, et al. (2015) Comparative clinical evaluation of coronally advanced flap with or without platelet rich fibrin membrane in the treatment of isolated gingival recession. *Journal of Indian Society of Periodontology* 19(1): 66–71.
51. Thomason JM, Seymour RA, Ellis JS, et al. (1995) Iatrogenic gingival overgrowth in cardiac transplantation. *Journal of periodontology* 66(8): 742–746.
52. Varghese SS, Thomas H, Jayakumar ND, et al. (2015) Estimation of salivary tumor necrosis factor-alpha in chronic and aggressive periodontitis patients. *Contemporary clinical dentistry* 6(Suppl 1): S152–6.



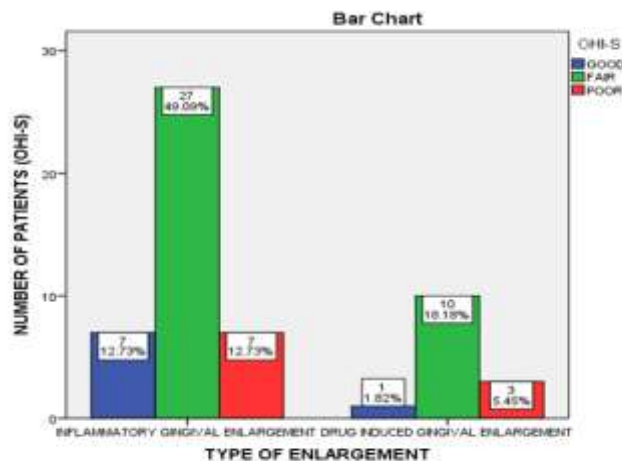
**Graph 1:** Bar chart shows the frequency rate of each drug that induced gingival enlargement. X axis represents the type of drug and Y axis represents the prevalence rate. From the above graph it is inferred that anticonvulsants induced gingival enlargement is more common.



**Graph 2:** Bar chart represents the association of age group with type of enlargement. X axis represents the type of enlargement and Y axis represents the frequency rate, drug induced enlargement was more common in patients above 40 years whereas, inflammatory enlargement was more common in patients below 40 years. Chi square test - Linear by linear association \*p value = 0.362 (>0.05), it can be inferred that the association of age groups with type of enlargement is statistically not significant.



**Graph 3: Bar chart represents the association of gender distribution with type of enlargement. X axis represents the type of enlargement and Y axis represents the frequency rate. The drug induced enlargement was more common in males patients, whereas inflammatory enlargement was more common in female patients. Chi square test Linear by linear association \*p value = 0.210 (>0.05) it can be inferred that the association of age groups with type of enlargement is statistically not significant.**



**Graph 4: Bar chart shows the association between the type of enlargement and Oral hygiene index. X axis represents the type of enlargement and Y axis represents the number of patients. Most of the patients had fair oral hygiene status (green) in both the type of enlargement. Chi square test - linear by linear association p value = 0.649 (>0.05) , it can be inferred that the association between type of enlargement and oral hygiene status is statistically not significant.**