
Prevalence of pericoronitis in impacted mandibular third molar: A Retrospective analysis of 86,000 patient records over nine months

FATHIMA BAREERA REZVI¹, ARTHI BALASUBRAMANIAM^{2*}, MANJARI CHAUDHARY³

¹Saveetha Dental College and Hospitals, Saveetha Institute of Medical and Technical Sciences, Saveetha University, Chennai, India

²Senior lecturer, Department of Public Health Dentistry, Saveetha Dental College and Hospitals, Saveetha Institute of Medical and Technical Sciences, Saveetha University, Chennai, India

³Senior lecturer, Department of Oral Medicine and Radiology, Saveetha Dental College and Hospitals, Saveetha Institute of Medical and Technical Sciences, Saveetha University, Chennai, India

*Corresponding Author

Email ID: 151501061.sdc@saveetha.com¹, arthib.sdc@saveetha.com, manjaric.sdc@saveetha.com

Abstract: Third molar impaction has become an important clinical issue. The impacted teeth may have many pathologies such as pericoronitis, periodontitis, root resorption, space infection and coronal and root caries. The study was aimed to find the prevalence of pericoronitis in impacted mandibular third molars. This retrospective study was conducted using records of patients visited private dental college. A total of 102 case records with information on impacted mandibular third molar and pericoronitis were retrieved. Data collected from their records were entered and subjected to statistical analysis. Descriptive statistics and Chi-square association was done to find the prevalence and association between impacted mandibular third molars and pericoronitis. Out of 102 subjects, 87.3% of patients with impacted mandibular third molars had pericoronitis and it was more in males (47.1%) when compared to females (40.2%). It was more prevalent in the age group of 21-30 (57.8%) and in the left mandibular third molar, 38 (51.0%) when compared to the right, 48 (36.3%). There was no significant association of pericoronitis with age, gender, tooth number ($p > 0.05$). Within the limits of the study majority of patients with impacted mandibular third molars had pericoronitis and it was more prevalent in males and in the age group of 17-26 years. Prevalence of pericoronitis was high in the impacted left mandibular third molar compared to the impacted right mandibular third molar.

Keywords: mandibular third molar; impaction; pericoronitis; prevalence innovative technique

INTRODUCTION

Teeth tend to be impacted when they experience failure to erupt or develop in their functional location. Mandibular third molars are the most frequently impacted teeth (Sheppard, 1997). The tooth fails to erupt completely or partially into its proper position in the dental arch. This tooth will not assume a normal arch relationship with the other teeth of the arch and the tissues. Theories have been proposed for the cause of impaction. One of them being the Phylogenetic theory which states that the human jaw has become smaller due to evolution, causing a lack of space for the third molar to erupt (Malik, 2016). The other theory talks about the insufficient development of the retromolar space (Bishara and Andreasen, 1983) (Grover and Lorton, 1985) in which the mandibular ramus growth is related to resorption in its anterior region and deposition in its posterior region, but during an imbalance, the mandibular third molars do not get adequate space for eruption (Björk, 1969). Impaction of mandibular third molar has become an important clinical problem, as the impacted teeth are predisposed to periodontal problems such as pericoronitis, periodontitis, root resorption leading to pain and discomfort (Odusanya and Abayomi, 1991). Pericoronitis is defined as an inflammation of the oral soft tissues which surrounds the crown of an erupted or partially erupted tooth. The word, pericoronitis is often used in relation to inflammation of the operculum associated with the mandibular third molars and it is rarely diagnosed elsewhere (Kay, 1966) (Bean and King, 1971) (Piironen and Ylipaavalniemi, 1981). Pericoronitis is often associated with impaction of the affected tooth and it is frequently associated with impacted third molars that arise due to tooth tissue discrepancy (Nitzan *et al.*, 1985). Difficulty in tooth brushing is experienced in relation to third molars because of their position thereby increasing the possibility of food impaction under the operculum, causing pain, discomfort and leading to infection. Pericoronitis has been reported to be one of the reasons for extraction of impacted third molars (Chestnutt, Binnie and Taylor, 2000) (Costa *et al.*, 2013) (Mohan *et al.*, 2017). Acute serous, acute suppurative, chronic are some forms of pericoronitis. Pain is predominant in the acute stage whereas in the chronic form very few symptoms are displayed, but exudate is present in both forms. The infection is multibacterial, caused by beta-

lactamase producing anaerobic microorganisms (Gutiérrez Pérez *et al.*, 2004). The most prevalent type of is chronic pericoronitis and it is diagnosed based on a history of temporary dull aching low grade pain that typically lasts for 1-2 days (Folayan *et al.*, 2014).

The prevalence of third molar impaction in humans ranges between 27-68.6% (Reddy and Venu Gopal Reddy, 2012) (Quek *et al.*, 2003) (Hassan, 2010). The peak age occurrence of pericoronitis is from 21-25 years (Bataneh and Al, 2003). The soft tissues adjacent to partially erupted mandibular third molars which are vertically inclined are more often affected by pericoronitis than teeth that are soft tissue impacted or erupted (Bataneh, Hazza'a and Odat, 2009)

Pericoronitis in young patients is often associated with vertically positioned third molars that have erupted to the occlusal plane, in the absence of clinically detrimental alveolar bone loss (Leone and Edenfield, 1987) (Halverson and Hart Anderson, 1992) (Ash, Costich and Hayward, 1962). Also pericoronitis is also seen in a high percentage of orthodontically treated cases with mesioangular position of the lower third molars (Güngörmüş, 2002). In some cases, pericoronitis may be chronic and painless (Laine *et al.*, 2003) with symptoms being intermittent, but is often recurrent in a specific individual. Operculectomy, although sometimes effective in reducing symptoms in the short term, does not appear to provide long-term benefit for most patients (Peterson, 1992). In such cases where pericoronitis is assumed to be a chronic inflammatory condition, the only viable treatment is to alter or eliminate the associated biofilm with its resident pathogens by extraction of third molars.

Previously our team had conducted numerous clinical studies (Prabakar, John and Srisakthi, 2016) (Prabakar, John, I. M. Arumugham, *et al.*, 2018) (Prabakar, John, I. Arumugham, Kumar and Srisakthi, 2018) (Kumar, Pradeep Kumar and Vijayalakshmi, 2017) (Kumar, Pradeep Kumar and Preethi, 2017) (Samuel, Acharya and Rao, 2020a) (Mathew *et al.*, 2020) (Khatra *et al.*, 2019) (Pavithra, Preethi Pavithra and Jayashri, 2019) (Neralla *et al.*, 2019) (Prabakar, John, I. Arumugham, Kumar and Sakthi, 2018) (Mohapatra *et al.*, 2019) (Harini and Leelavathi, 2019) (Pratha, Ashwatha Pratha and Prabakar, 2019) and systematic review (Kannan *et al.*, 2017) over the past 5 years. Now we are focusing on epidemiological study.

Our department is passionate about research we have published numerous high quality articles in this domain over the past years (Abraham *et al.*, 2005; Devaki, Sathivel and BalajiRaghavendran, 2009; Neelakantan *et al.*, 2010, 2015; Arja *et al.*, 2013; Ramshankar *et al.*, 2014; Sumathi *et al.*, 2014; Surapaneni and Jainu, 2014; Surapaneni, Priya and Mallika, 2014; Ramamoorthi, Nivedhitha and Divyanand, 2015; Manivannan *et al.*, 2017; Ezhilarasan, 2018; Ezhilarasan, Sokal and Najimi, 2018; J *et al.*, 2018; Ravindiran and Praveenkumar, 2018; Malli Sureshbabu *et al.*, 2019; Mehta *et al.*, 2019; Krishnaswamy *et al.*, 2020; Samuel, Acharya and Rao, 2020b; Sathish and Karthick, 2020)

Hence this study aims to determine the prevalence of pericoronitis in impacted mandibular third molars

MATERIALS AND METHODS

Study design and Study setting: This retrospective descriptive study was conducted using Case records of patients visiting the authors University hospital. The study was conducted to evaluate the prevalence of pericoronitis in impacted mandibular third molars in patients visiting the University hospital from June 2019 to March 2020. The study was initiated after approval from the institutional review board - SDC/SIHEC/2020/DIASDATA/0619-0320

Study population and sampling: Among the 86,000 patient records, a total of 4378 records with information on impacted teeth were sorted. Of which 3243 records containing information about impacted third molars were filtered. About 102 case records of patients with impacted mandibular third molars were retrieved. An effort was taken to remove the incomplete case records and duplicates with the help of an external reviewer.

Data collection: Information on patients' age, gender, impacted third molar tooth number and its associated pathology pericoronitis present or absent were collected and entered in a spreadsheet. Age of the patients was categorized into 17-26 years, 27-36 years, 37-46 years, 47-56 years for statistical convenience.

Statistical Analysis: The collected data was tabulated and analysed with Statistical Package for Social Sciences for Windows, version 20.0 (SPSS Inc., Chicago, IL, USA). Descriptive statistics was done to find the prevalence and Chi-square association test was done to find the association of age, gender and tooth number with pericoronitis in impacted mandibular third molar. P value <0.05 was considered statistically significant.

RESULTS AND DISCUSSION

Out of 102 subjects, 87.3% of patients with impacted mandibular third molars had pericoronitis and 12.7% of patients did not have pericoronitis. Majority of patients with impacted mandibular third molars had pericoronitis (Figure 1). Pericoronitis in patients with impacted mandibular third molars was more in age group 17-26 years (48.0%), followed by the age group 27-36 years (30.4%) and 37-46 years (6.9%) and lastly by 47-56 years (2.0%).

However the results are statistically not significant [Pearson's Chi Square value =2.010^a, df = 3, p value = 0.570 (>0.05)] (Figure 2). Pericoronitis in patients with impacted mandibular third molars was more in males (47.1%) when compared to females (40.2%) which shows the results are statistically not significant [Pearson's Chi Square value =0.275^a, df = 1, p value = 0.600 (>0.05)] (Figure 3). Prevalence of pericoronitis in patients with impacted mandibular third molars was more in the left mandibular third molar (51.0%) when compared to the right mandibular third molar (36.3%) which shows the results are statistically not significant [Pearson's Chi Square value =0.551^a, df = 1, p value = 0.458 (>0.05)] (Figure 4).

According to our study, it was seen that the prevalence of pericoronitis in patients with impacted mandibular third molars was 87.3%. This is similar to the studies done by Ahmed et al. (Al-Naaimi *et al.*, 2011), Halverson et al. (Halverson and Hart Anderson, 1992), Singh et al. (Singh *et al.*, 2018) also study Braimah et al (Braimah *et al.*, 2018) states that pericoronitis is the most common cause for third molar removal, as they are the last to erupt, causing inadequate space, leading to pain due to pericoronitis. Similarly, Halverson et al (Halverson and Hart Anderson, 1992) states that the majority of pericoronitis was seen in vertically oriented mandibular third molars, as the risk of pericoronitis appears to increase with greater vertical orientation and height of eruption. Singh et al (Singh *et al.*, 2018) reported that there was an increased prevalence of impinging mandibular molars on pericoronitis. Braimah et al. (Braimah *et al.*, 2018) disagrees with our study and stated that caries and pathological pockets were the highly associated pathologies with impacted third molar. He stated that third molar teeth were associated with periodontal probing depths, harbour pathological bacteria, leading to caries and periodontal disease.

We observed in our study that prevalence of pericoronitis in impacted mandibular third molar patients was more in males than females. While most studies including R.Singh et al. (Singh *et al.*, 2020), Akarslan et al. (Akarslan and Kocabay, 2009) contradict our study results, few studies by Yilmaz et al. (Yilmaz *et al.*, 2016) and Shahid et al. (Shahid Ali *et al.*, 2014) support the results of our study. R.Singh et al. (Singh *et al.*, 2020) reported a female predilection in his study while Akarslan et al. (Akarslan and Kocabay, 2009) reports no association between gender. The prevalence could be high in females when compared to males, as male jaws continue to grow and develop during the period of eruption of third molars, creating more space for the eruption of third molars while female jaws cease to grow and develop during the period of third molar eruption (Patel *et al.*, 2017). Our study would have had a male predilection as a combination of genetic and dietary factors also have an effect on impacted third molars in males (Osunde and Bassey, 2016).

Our study had a higher prevalence within the age group 17-26 years. Third molars begin to erupt at the end of first decade and beginning of second decade, which leads to impaction and associated symptoms in the upcoming years. Knutsson et al (Knutsson *et al.*, 1996) and Galvao et al (Galvão *et al.*, 2019) support our study by stating that prevalence of pericoronitis in impaction patients was higher in the 2nd and 3rd decades. Nitzan et al. (Nitzan *et al.*, 1985) stated that the highest incidence of pericoronitis was found in the 20-29 year age group (81%) and it was rarely seen before 20 or after 40. Katsarou et al. (Katsarou *et al.*, 2019) also supports our study by stating that the group of patients between 20 and 25 years old dominated, with a percentage of 72.4%. The left mandibular third molar had a higher prevalence than the right mandibular third molar in our results. Katsarou et al. (Katsarou *et al.*, 2019) reports similar results stating that the lower left third molar had a higher prevalence (51.7%) and was associated with pericoronitis than the lower right third molar (24.1%). Ayanbadejo et al. (Ayanbadejo and Umesikoleoso, 2007) also agrees with our results and reports that lower left third molars (45.3%) were more affected than lower right third molars (37.1%). Al-Shamahy et al. (Al-Shamahy, 2019) reported results that are in disagreement with our study. He reported that there was no significance between the prevalence of pericoronitis in the impacted right and left mandibular third molars.

The limitations of the study is that only impacted mandibular third molars were considered. Also the study failed to assess the ethnicity and race which plays a major role in physical anthropology showing evolutionary changes in tooth size and jaw size. Further longitudinal studies with analysis of ethnicity and race that may contribute to impaction and pericoronitis should be taken into consideration for better outcome.

CONCLUSION

Within the limits of the study majority of patients with impacted mandibular third molars had pericoronitis and it was more prevalent in males of the age group 17-26 years. Prevalence of pericoronitis is high for the impacted left mandibular third molar compared to right mandibular molar. The biological plausibility behind this high prevalence needs to be investigated.

Acknowledgment: We would like to thank Saveetha Dental College for providing us with the opportunity to review the case sheets.

AUTHOR'S CONTRIBUTION

First author (Fathima Bareera Rezvi) performed the analysis, and interpretation and wrote the manuscript. Second author (Arthi Balasubramaniam) contributed to conception, data design analysis, interpretation and critically

revised the manuscript. Third author (Manjary Chaudhary) participated in the study and revised the manuscript. All the authors have discussed the results and contributed to the final manuscript.

Conflict of interest: Nil

REFERENCES

1. Abraham, S. *et al.* (2005) 'Evaluation of the inhibitory effect of triphala on PMN-type matrix metalloproteinase (MMP-9)', *Journal of periodontology*, 76(4), pp. 497–502.
2. Akarslan, Z. Z. and Kocabay, C. (2009) 'Assessment of the associated symptoms, pathologies, positions and angulations of bilateral occurring mandibular third molars: is there any similarity?', *Oral surgery, oral medicine, oral pathology, oral radiology, and endodontics*, 108(3), pp. e26–32.
3. Al-Naaimi, A. S. *et al.* (2011) 'Factors associated with pericoronitis among subjects with impacted third molars teeth', *MUSTANSIRIA DENTAL JOURNAL*, 8(2), pp. 193–201.
4. Al-Shamahy, H. A. (2019) 'Prevalence and Pattern of Third Molar Impaction in Sample of Yemeni Adults', *Online Journal of Dentistry & Oral Health*. doi: 10.33552/ojdoh.2019.01.000523.
5. Arja, C. *et al.* (2013) 'Oxidative stress and antioxidant enzyme activity in South Indian male smokers with chronic obstructive pulmonary disease', *Respirology*, 18(7), pp. 1069–1075.
6. Ash, M. M., Costich, E. R. and Hayward, J. R. (1962) 'A Study of Periodontal Hazards of Third Molars', *Journal of Periodontology*, pp. 209–219. doi: 10.1902/jop.1962.33.3.209.
7. Ayanbadejo, P. O. and Umesi-Koleoso, D. C. (2007) 'A retrospective study of some socio-demographic factors associated with pericoronitis in Nigerians', *West African journal of medicine*, 26(4), pp. 302–305.
8. Bataineh, A. B. and Al, Q. M. A. (2003) 'The predisposing factors of pericoronitis of mandibular third molars in a Jordanian population', *Quintessence international*, 34(3), pp. 227–231.
9. Bataineh, A., Hazza'a, A. and Odat, A.-A. (2009) 'Angulation of Mandibular Third Molars as a Predictive Factor for Pericoronitis', *The Journal of Contemporary Dental Practice*, pp. 51–58. doi: 10.5005/jcdp-10-3-51.
10. Bean, L. R. and King, D. R. (1971) 'Pericoronitis: its nature and etiology', *Journal of the American Dental Association*, 83(5), pp. 1074–1077.
11. Bishara, S. E. and Andreasen, G. (1983) 'Third molars: A review', *American Journal of Orthodontics*, pp. 131–137. doi: 10.1016/s0002-9416(83)90298-1.
12. Björk, A. (1969) 'Prediction of mandibular growth rotation', *American journal of orthodontics*, 55(6), pp. 585–599.
13. Braimah, R. *et al.* (2018) 'Pathologies associated with impacted mandibular third molars in sub-saharan africans', *Dentistry and Medical Research*, p. 2. doi: 10.4103/dmr.dmr_20_17.
14. Chestnutt, I. G., Binnie, V. I. and Taylor, M. M. (2000) 'Reasons for tooth extraction in Scotland', *Journal of dentistry*, 28(4), pp. 295–297.
15. Costa, M. G. da *et al.* (2013) 'Is there justification for prophylactic extraction of third molars? A systematic review', *Brazilian Oral Research*, pp. 183–188. doi: 10.1590/s1806-83242013000100024.
16. Devaki, T., Sathivel, A. and BalajiRaghavendran, H. R. (2009) 'Stabilization of mitochondrial and microsomal function by polysaccharide of *Ulva lactuca* on D-Galactosamine induced hepatitis in rats', *Chemico-biological interactions*, 177(2), pp. 83–88.
17. Ezhilarasan, D. (2018) 'Oxidative stress is bane in chronic liver diseases: Clinical and experimental perspective', *Arab journal of gastroenterology: the official publication of the Pan-Arab Association of Gastroenterology*, 19(2), pp. 56–64.
18. Ezhilarasan, D., Sokal, E. and Najimi, M. (2018) 'Hepatic fibrosis: It is time to go with hepatic stellate cell-specific therapeutic targets', *Hepatobiliary & pancreatic diseases international: HBPDI*, 17(3), pp. 192–197.
19. Folayan, M. O. *et al.* (2014) 'Non-third molar related pericoronitis in a sub-urban Nigeria population of children', *Nigerian journal of clinical practice*, 17(1), pp. 18–22.
20. Galvão, E. L. *et al.* (2019) 'Association between mandibular third molar position and the occurrence of pericoronitis: A systematic review and meta-analysis', *Archives of Oral Biology*, p. 104486. doi: 10.1016/j.archoralbio.2019.104486.
21. Grover, P. S. and Lorton, L. (1985) 'The incidence of unerupted permanent teeth and related clinical cases', *Oral Surgery, Oral Medicine, Oral Pathology*, pp. 420–425. doi: 10.1016/0030-4220(85)90070-2.
22. Güngörmüs, M. (2002) 'Pathologic status and changes in mandibular third molar position during orthodontic treatment', *The journal of contemporary dental practice*, 3(2), pp. 11–22.
23. Gutiérrez Pérez, J. L. *et al.* (2004) 'Infecciones orofaciales de origen odontogénico', *Medicina oral, patología oral y cirugía bucal*, 9(4), pp. 280–287.
24. Halverson, B. A. and Hart Anderson, W. (1992) 'The Mandibular Third Molar Position as a Predictive Criteria for Risk for Pericoronitis: A Retrospective Study', *Military Medicine*, pp. 142–145. doi:

- 10.1093/milmed/157.3.142.
25. Harini, G. and Leelavathi, L. (2019) 'Nicotine Replacement Therapy for Smoking Cessation-An Overview', *Indian Journal of Public Health Research & Development*, p. 3588. doi: 10.5958/0976-5506.2019.04144.5.
 26. Hassan, A. (2010) 'Pattern of third molar impaction in a Saudi population', *Clinical, Cosmetic and Investigational Dentistry*, p. 109. doi: 10.2147/cciden.s12394.
 27. J, P. C. et al. (2018) 'Prevalence and measurement of anterior loop of the mandibular canal using CBCT: A cross sectional study', *Clinical implant dentistry and related research*, 20(4), pp. 531–534.
 28. Kannan, S. S. D. et al. (2017) 'AWARENESS AND ATTITUDE TOWARDS MASS DISASTER AND ITS MANAGEMENT AMONG HOUSE SURGEONS IN A DENTAL COLLEGE AND HOSPITAL IN CHENNAI, INDIA', *Disaster Management and Human Health Risk V*. doi: 10.2495/dman170121.
 29. Katsarou, T. et al. (2019) 'Pericoronitis: A clinical and epidemiological study in greek military recruits', *Journal of Clinical and Experimental Dentistry*, pp. e133–e137. doi: 10.4317/jced.55383.
 30. Kay, L. W. (1966) 'Investigations into the nature of pericoronitis', *The British journal of oral surgery*, 3(3), pp. 188–205 contd.
 31. Khatri, S. G. et al. (2019) 'Retention of moisture-tolerant fluoride-releasing sealant and amorphous calcium phosphate-containing sealant in 6-9-year-old children: A randomized controlled trial', *Journal of the Indian Society of Pedodontics and Preventive Dentistry*, 37(1), pp. 92–98.
 32. Knutsson, K. et al. (1996) 'Pathoses associated with mandibular third molars subjected to removal', *Oral surgery, oral medicine, oral pathology, oral radiology, and endodontics*, 82(1), pp. 10–17.
 33. Krishnaswamy, H. et al. (2020) 'Investigation of air conditioning temperature variation by modifying the structure of passenger car using computational fluid dynamics', *Thermal Science*, 24(1 Part B), pp. 495–498.
 34. Kumar, R. P., Pradeep Kumar, R. and Preethi, R. (2017) 'Assessment of Water Quality and Pollution of Porur, Chembarambakkam and Puzhal Lake', *Research Journal of Pharmacy and Technology*, p. 2157. doi: 10.5958/0974-360x.2017.00380.8.
 35. Kumar, R. P., Pradeep Kumar, R. and Vijayalakshmi, B. (2017) 'Assessment of Fluoride Concentration in Ground Water in Madurai District, Tamil Nadu, India', *Research Journal of Pharmacy and Technology*, p. 309. doi: 10.5958/0974-360x.2017.00063.4.
 36. Laine, M. et al. (2003) 'Chronic inflammation around painless partially erupted third molars', *Oral surgery, oral medicine, oral pathology, oral radiology, and endodontics*, 95(3), pp. 277–282.
 37. Leone, S. A. and Edenfield, M. J. (1987) 'Third molars and acute pericoronitis: a military problem', *Military medicine*, 152(3), pp. 146–149.
 38. Malik, N. (2016) 'Surgical Management of Impacted Teeth', *Textbook of Oral and Maxillofacial Surgery*, pp. 293–293. doi: 10.5005/jp/books/12910_21.
 39. Malli Sureshbabu, N. et al. (2019) 'Concentrated Growth Factors as an Ingenious Biomaterial in Regeneration of Bony Defects after Periapical Surgery: A Report of Two Cases', *Case reports in dentistry*, 2019, p. 7046203.
 40. Manivannan, I. et al. (2017) 'Tribological and surface behavior of silicon carbide reinforced aluminum matrix nanocomposite', *Surfaces and Interfaces*, 8, pp. 127–136.
 41. Mathew, M. G. et al. (2020) 'Evaluation of adhesion of Streptococcus mutans, plaque accumulation on zirconia and stainless steel crowns, and surrounding gingival inflammation in primary molars: randomized controlled trial', *Clinical oral investigations*. doi: 10.1007/s00784-020-03204-9.
 42. Mehta, M. et al. (2019) 'Oligonucleotide therapy: An emerging focus area for drug delivery in chronic inflammatory respiratory diseases', *Chemico-biological interactions*, 308, pp. 206–215.
 43. Mohan, A. et al. (2017) 'Inflammatory paradental cyst on the distobuccal aspect of an impacted mandibular third molar: A case report', *International Journal of Case Reports and Images*, p. 592. doi: 10.5348/ijcri-201789-cr-10828.
 44. Mohapatra, S. et al. (2019) 'Assessment of Microhardness of Enamel Carious Like Lesions After Treatment with Nova Min, Bio Min and Remin Pro Containing Toothpastes: An in Vitro Study', *Indian Journal of Public Health Research & Development*, p. 375. doi: 10.5958/0976-5506.2019.02832.8.
 45. Neelakantan, P. et al. (2010) 'Root and Canal Morphology of Mandibular Second Molars in an Indian Population', *Journal of endodontics*, 36(8), pp. 1319–1322.
 46. Neelakantan, P. et al. (2015) 'Photoactivation of curcumin and sodium hypochlorite to enhance antibiofilm efficacy in root canal dentin', *Photodiagnosis and photodynamic therapy*, 12(1), pp. 108–114.
 47. Neralla, M. et al. (2019) 'Role of nutrition in rehabilitation of patients following surgery for oral squamous cell carcinoma', *International Journal of Research in Pharmaceutical Sciences*, pp. 3197–3203. doi: 10.26452/ijrps.v10i4.1622.
 48. Nitzan, D. W. et al. (1985) 'Pericoronitis: a reappraisal of its clinical and microbiologic aspects', *Journal of oral and maxillofacial surgery: official journal of the American Association of Oral and Maxillofacial Surgeons*, 43(7), pp. 510–516.
 49. Odusanya, S. A. and Abayomi, I. O. (1991) 'Third molar eruption among rural Nigerians', *Oral surgery*,

- oral medicine, and oral pathology*, 71(2), pp. 151–154.
50. Osunde, O. D. and Basse, G. O. (2016) 'Pattern of impacted mandibular third molars in Calabar, Nigeria', *African Journal of Medical and Health Sciences*, 15(1), p. 14.
 51. Patel, S. et al. (2017) 'Impacted Mandibular Third Molars: A Retrospective Study of 1198 Cases to Assess Indications for Surgical Removal, and Correlation with Age, Sex and Type of Impaction-A Single Institutional Experience', *Journal of maxillofacial and oral surgery*, 16(1), pp. 79–84.
 52. Pavithra, R. P., Preethi Pavithra, R. and Jayashri, P. (2019) 'Influence of Naturally Occurring Phytochemicals on Oral Health', *Research Journal of Pharmacy and Technology*, p. 3979. doi: 10.5958/0974-360x.2019.00685.1.
 53. Peterson, L. J. (1992) *Principles of Oral and Maxillofacial Surgery*. Lippincott.
 54. Piironen, J. and Ylipaavalniemi, P. (1981) 'Local predisposing factors and clinical symptoms in pericoronitis', *Proceedings of the Finnish Dental Society. Suomen Hammaslaakariseuran toimituksia*, 77(5), pp. 278–282.
 55. Prabakar, J., John, J., Arumugham, I., Kumar, R. and Srisakthi, D. (2018) 'Comparative evaluation of retention, cariostatic effect and discoloration of conventional and hydrophilic sealants - A single blinded randomized split mouth clinical trial', *Contemporary Clinical Dentistry*, p. 233. doi: 10.4103/ccd.ccd_132_18.
 56. Prabakar, J., John, J., Arumugham, I. M., et al. (2018) 'Comparative Evaluation of the Viscosity and Length of Resin Tags of Conventional and Hydrophilic Pit and Fissure Sealants on Permanent Molars: An In vitro Study', *Contemporary clinical dentistry*, 9(3), pp. 388–394.
 57. Prabakar, J., John, J., Arumugham, I., Kumar, R. and Sakthi, D. (2018) 'Comparing the effectiveness of probiotic, green tea, and chlorhexidine- and fluoride-containing dentifrices on oral microbial flora: A double-blind, randomized clinical trial', *Contemporary Clinical Dentistry*, p. 560. doi: 10.4103/ccd.ccd_659_18.
 58. Prabakar, J., John, J. and Srisakthi, D. (2016) 'Prevalence of dental caries and treatment needs among school going children of Chandigarh', *Indian journal of dental research: official publication of Indian Society for Dental Research*, 27(5), pp. 547–552.
 59. Pratha, A. A., Ashwatha Pratha, A. and Prabakar, J. (2019) 'Comparing the effect of Carbonated and energy drinks on salivary pH- In Vivo Randomized Controlled Trial', *Research Journal of Pharmacy and Technology*, p. 4699. doi: 10.5958/0974-360x.2019.00809.6.
 60. Quek, S. L. et al. (2003) 'Pattern of third molar impaction in a Singapore Chinese population: a retrospective radiographic survey', *International journal of oral and maxillofacial surgery*, 32(5), pp. 548–552.
 61. Ramamoorthi, S., Nivedhitha, M. S. and Divyanand, M. J. (2015) 'Comparative evaluation of postoperative pain after using endodontic needle and EndoActivator during root canal irrigation: A randomised controlled trial', *Australian endodontic journal: the journal of the Australian Society of Endodontology Inc*, 41(2), pp. 78–87.
 62. Ramshankar, V. et al. (2014) 'Risk stratification of early stage oral tongue cancers based on HPV status and p16 immunoreexpression', *Asian Pacific journal of cancer prevention: APJCP*, 15(19), pp. 8351–8359.
 63. Ravindran, M. and Praveenkumar, C. (2018) 'Status review and the future prospects of CZTS based solar cell – A novel approach on the device structure and material modeling for CZTS based photovoltaic device', *Renewable and Sustainable Energy Reviews*, 94, pp. 317–329.
 64. Reddy, K. V. G. and Venu Gopal Reddy, K. (2012) 'Distribution of Third Molar Impactions Among Rural and Urban Dwellers in the Age Group of 22–30 years in South India: A Comparative Study', *Journal of Maxillofacial and Oral Surgery*, pp. 271–275. doi: 10.1007/s12663-011-0320-z.
 65. Samuel, S. R., Acharya, S. and Rao, J. C. (2020a) 'School Interventions–based Prevention of Early-Childhood Caries among 3–5-year-old children from very low socioeconomic status: Two-year randomized trial', *Journal of Public Health Dentistry*, pp. 51–60. doi: 10.1111/jphd.12348.
 66. Samuel, S. R., Acharya, S. and Rao, J. C. (2020b) 'School Interventions-based Prevention of Early-Childhood Caries among 3-5-year-old children from very low socioeconomic status: Two-year randomized trial', *Journal of public health dentistry*, 80(1), pp. 51–60.
 67. Sathish, T. and Karthick, S. (2020) 'Wear behaviour analysis on aluminium alloy 7050 with reinforced SiC through taguchi approach', *Journal of Materials Research and Technology*, 9(3), pp. 3481–3487.
 68. Shahid Ali et al. (2014) 'Dental caries and pericoronitis associated with impacted mandibular third molars - a clinical and radiographic study', *Pakistan Oral and Dental Journal*, 34, p. 268+.
 69. Sheppard, P. (1997) 'A Synopsis of Minor Oral Surgery (1997). George Dimitroulis. Publisher: Wright (Butterworth-Heinemann), Oxford. Price: 19.99. ISBN: 0-7236-1094-0', *The European Journal of Orthodontics*, pp. 337–337. doi: 10.1093/ejo/19.3.337.
 70. Singh, P. et al. (2018) 'The predictivity of mandibular third molar position as a risk indicator for pericoronitis: A prospective study', *National journal of maxillofacial surgery*, 9(2), pp. 215–221.
 71. Singh, R. et al. (2020) 'Evaluation of mandibular third molar position as a risk factor for pericoronitis: A CBCT study', *Journal of family medicine and primary care*, 9(3), pp. 1599–1602.

72. Sumathi, C. *et al.* (2014) ‘Production of prodigiosin using tannery fleshing and evaluating its pharmacological effects’, *TheScientificWorldJournal*, 2014, p. 290327.
73. Surapaneni, K. M. and Jainu, M. (2014) ‘Comparative effect of pioglitazone, quercetin and hydroxy citric acid on the status of lipid peroxidation and antioxidants in experimental non-alcoholic steatohepatitis’, *Journal of physiology and pharmacology: an official journal of the Polish Physiological Society*, 65(1), pp. 67–74.
74. Surapaneni, K. M., Priya, V. V. and Mallika, J. (2014) ‘Pioglitazone, quercetin and hydroxy citric acid effect on cytochrome P450 2E1 (CYP2E1) enzyme levels in experimentally induced non alcoholic steatohepatitis (NASH)’, *European review for medical and pharmacological sciences*, 18(18), pp. 2736–2741.
75. Yilmaz, S. *et al.* (2016) ‘Assessment of Third Molar Impaction Pattern and Associated Clinical Symptoms in a Central Anatolian Turkish Population’, *Medical principles and practice: international journal of the Kuwait University, Health Science Centre*, 25(2), pp. 169–175.

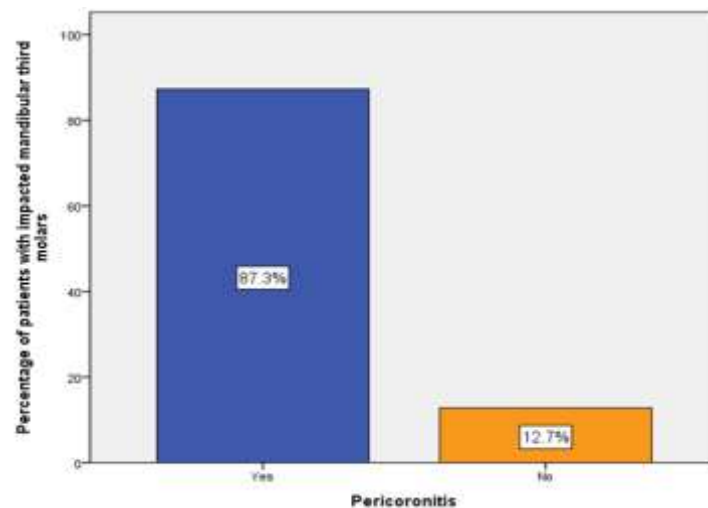


Fig.1: Bar chart represents the prevalence of pericoronitis in patients with impacted mandibular third molars. X axis represents the presence and absence of pericoronitis and Y axis represents the percentage of patients with impacted mandibular third molars. 87.3% of patients with impacted mandibular third molars had pericoronitis and 12.7% of patients had no pericoronitis. Majority of patients with impacted mandibular third molars had pericoronitis.

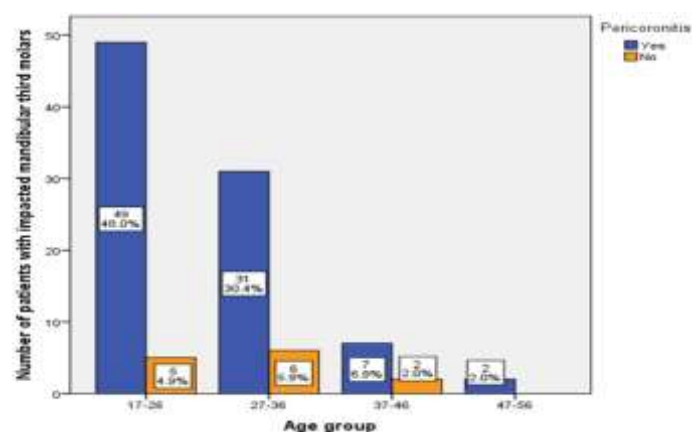


Fig.2: Bar chart represents the association between age and pericoronitis in impacted mandibular third molars. X axis represents the age group and Y axis represents the number of patients with impacted mandibular third molars. [Pearson’s Chi Square value = 2.010a, df = 3, p value = 0.570 (>0.05), hence statistically not significant]. Pericoronitis in patients with impacted mandibular third molars was more in age group 17-26 years (48%) compared to other age groups.

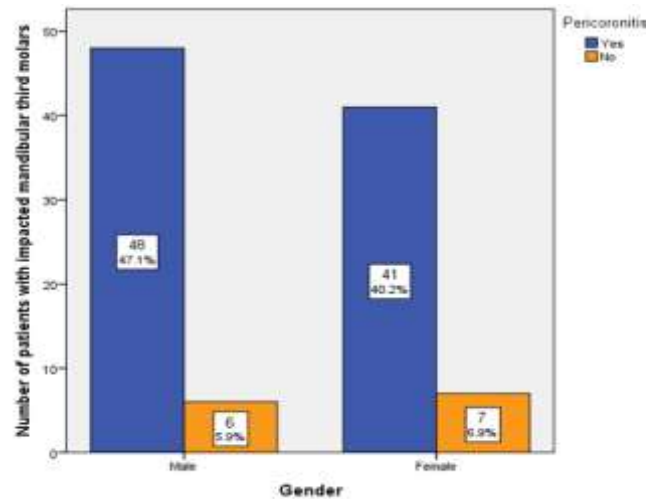


Fig.3: Bar chart represents the association between gender and pericoronitis in patients with impacted mandibular third molars. X axis represents the gender and Y axis represents the patients with impacted mandibular third molars. [Pearson's Chi Square value = 0.275a , df = 1, p value = 0.600 (>0.05), hence statistically not significant]. Pericoronitis in patients with impacted mandibular third molars was seen more in males (47.1%) compared to females (40.2%).

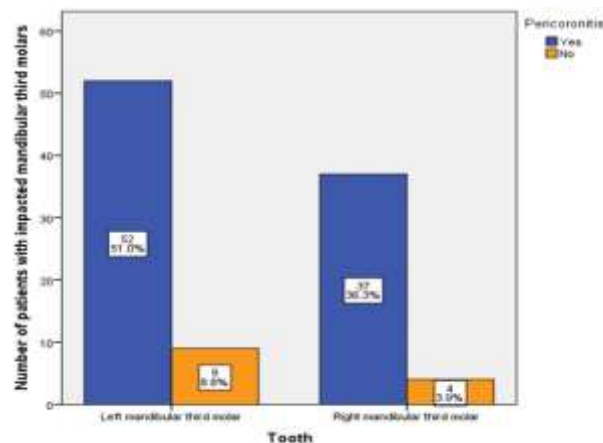


Fig.4: Bar chart represents the association between tooth number and pericoronitis in impacted mandibular third molars. X axis represents the left and right mandibular third molars and Y axis represents the number of patients. [Pearson's Chi Square value = 0.551a , df = 1, p value = 0.458 (>0.05), hence statistically not significant]. Pericoronitis in patients with impacted mandibular third molars was more on the left side (51.0%) when compared to the right side (36.3%).