

---

## Assessment of disease progression in patients with RMT carcinoma - A retrospective analysis of the associated factor.

---

SINDHU PRIYA KUPPUSAMY SUNDARA MURTHY<sup>1</sup>, DR. MAHATHI. N<sup>2\*</sup>, DR. SURESH<sup>3</sup>

<sup>1</sup>Saveetha Dental College and Hospitals, Saveetha Institute of Medical and Technical sciences (SIMATS), Saveetha University, Chennai - 77, India.

<sup>2</sup>Reader, Department of Oral and Maxillofacial surgery, Saveetha Dental College and Hospitals, Saveetha Institute of Medical and Technical sciences (SIMATS), Saveetha University, Chennai - 77, India.

<sup>3</sup>Reader, Department of Prosthodontics, Saveetha Dental College and Hospitals, Saveetha Institute of Medical and Technical sciences (SIMATS), Saveetha University, Chennai - 77, India.

\*Corresponding Author

Email ID: 151501024.sdc@saveetha.com<sup>1</sup>, mahathin.sdc@saveetha.com, suresh@saveetha.com

---

**Abstract:** Retromolar trigone is a subsite of oral cavity. It is a triangular mucosal area between the ascending ramus of the mandible attached to the muscles of mastication. Only at advanced stages after it involves the mandible or masticatory muscle does it result in severe pain or trismus. Data samples required for study were taken from hospital records. All the collected data were cross verified and compiled together in an excel sheet. Compiled data were statistically analysed in SPSS software. In this study of 27 patients, before treatment about 50% (14) had symptoms of trismus, after treatment out of the 50% of patients with trismus, 35.71% had 2 finger breadth mouth opening (trismus) and the rest of the patients (64.29%) had 3 finger breadth mouth opening.

**Keywords:** Retromolar trigone, Mastication, Trismus, Pain innovative technique

---

### INTRODUCTION

The RMT begins at the third molar and extends cranially to the maxillary tuberosity. It is a small mucosal area continuous with buccal mucosa, upper and lower gingiva, soft palate, and floor of the mouth (Petruzzelli *et al.*, 2003). In a study by Byers, It showed that the tumour extends to the following adjacent sites: soft palate, 65 patients (59%); buccal mucosa, 47 patients (43%); anterior tonsillar pillar, 93 patients (85%); and mandibular gingiva, 67 patients (61%). Radiographic evidence of bone invasion was present in 17 patients (15%). Involvement of the regional lymphatics is less often observed than it is for tonsillar or tongue base carcinomas.

SCC of RMT is uncommon and has a high incidence of bone invasion and poor prognosis. Patients are diagnosed at advanced stages because tumour is benign for a long time until it involves the mandible or masticatory muscles, results in severe pain and trismus (Edge *et al.*, 2010), (Byers *et al.* 1984).

Most common treatment is surgery and post-operative radiation or chemotherapy. Some use a limited approach such as, posterior marginal mandibulectomy. The treatment of squamous cell carcinoma of the retromolar trigone is controversial. Determining the optimal management strategy is very difficult because it is a relatively uncommon tumor. The natural history and response to surgery and/or RT for head and neck cancers vary significantly depending on primary site and extent of disease. The choice of therapy is dependent on the extent of the tumor, nodal metastasis, and the medical status of the patient and comorbid conditions (Hao and Cheng, 2004).

The 5-year survival rate of stage I is 100%, stage II is 74.1%, stage III is 75%, stage IV is 43.6% and stage N is 60.6%. The incidence of SCC occurring in RMT site is 7% (Mendenhall *et al.*, 2005)

The purpose of this study was to identify any trends in the number of cases or incidence rates at specific anatomic sites, in this case in RMT, and how it affects prognosis.

Previously our team had conducted numerous clinical trials<sup>7-11</sup> and lab animal studies<sup>12-19</sup> and in-vitro studies<sup>20-21</sup> over the past 5 years. Now we are focussing on epidemiological surveys.

Our department is passionate about research we have published numerous high quality articles in this domain over the past years (Abraham *et al.*, 2005; Devaki, Sathivel and BalajiRaghavendran, 2009; Neelakantan *et al.*, 2010, 2015; Arja *et al.*, 2013; Ramshankar *et al.*, 2014; Sumathi *et al.*, 2014; Surapaneni and Jainu, 2014; Surapaneni, Priya and Mallika, 2014; Ramamoorthi, Nivedhitha and Divyanand, 2015; Manivannan *et al.*, 2017; Ezhilarasan, 2018; Ezhilarasan, Sokal and Najimi, 2018; J *et al.*, 2018; Ravindiran and Praveenkumar, 2018; Malli Sureshbabu *et al.*, 2019; Mehta *et al.*, 2019; Krishnaswamy *et al.*, 2020; Samuel, Acharya and Rao, 2020; Sathish and Karthick, 2020)

The idea for this study stemmed from the current interest in our community.

## MATERIALS AND METHODS

**Study Setting:** This retrospective study was conducted under a hospital based university setting.

**Ethical approval:** Ethical permission and approval for the project was obtained from the Institutional Review Board of Saveetha Institute of Medical and Technical Sciences, Chennai, India on 25/04/2020. Ethical approval number is SDC/SIHEC/2020/DIASDATA/0619-0320.

**Inclusion Criteria:** All the data of the patients in this study recorded were patients diagnosed with RMT carcinoma and had undergone treatment.

**Exclusion Criteria:** Exclusion criteria was case sheets with incomplete data, patients with other types of cancer and those patients who did not come for follow up visits when called.

**Data collection:** Data was collected from case sheets of patients who reported during the months of October 2019 and March 2020 from the hospital record management system where all the records of patients regarding their medical and dental history and treatment done are stored. All the data will be covered by the following. Cross verification was done to avoid bias by another examiner. To avoid missing any data, photographic evaluation was done. All the relevant data were retrieved and tabulated in excel sheet. Later, it was statistically analysed by IBM SPSS statistics.

**Statistical Analysis:** The descriptive statistics were used to determine the frequencies and percentages of the patients with RMT carcinoma. Chi square test was used to assess the association of RMT carcinoma with age and gender. The outcome data was represented in the form of a bar graph.

## RESULTS AND DISCUSSION

The study consists of 27 patients, among which 18 were males and 9 were females. All 27 patients were diagnosed with RMT carcinoma. Before treatment, 50% (14) of patients had trismus (finger breadth) (Fig.1) and after treatment out of the 50% of patients with trismus, 35.71% had 2 finger breadth mouth opening and the rest of the patients (64.29%) had resolved mouth opening with 3 finger breadth mouth opening (Fig.3). Out of the 14 patients with trismus, 35.71% had 1 finger breadth mouth opening and 64.29% had 2 finger breadth (Fig.2). 17.86% from 30-45, 14.29% from 46-60, 17.86% from >60 age groups had no trismus. 14.29% from 46-60, 35.71% from >60 had trismus with a p value of 0.045 (<0.05) (Fig.5). 28.57% of males had trismus and the rest 39.29% had no trismus. 21.43% of females had trismus and the rest 10.71% had no trismus, with a p value of 0.045 (<0.05) (Fig.4). After treatment, there was 14.29% with recurrence and 85.71% without recurrence (previous trismus) (Fig.6). After treatment, there was 21.43% with recurrence and 78.57% without recurrence (no previous trismus) (Fig.7).

RMT cancer commonly spreads along the pterygomandibular raphae and moves upwards to the maxillary sinus through its lateral wall. It is more commonly involved in maxillary bone (22.1%) than mandible (18%) (Wang *et al.*, 2013). If RMT cancer invaded the mandible, the tumour penetrates through the teeth or the socket and not through the mandible cortex.

In case of superior extension of cancer to the masticatory space, segmental mandibulectomy is indicated for tumour resection (Antoniades *et al.*, 2003). Combination of anterior mandibulectomy and posterior marginal mandibulectomy results in damage to the mandible's blood supply, resulting in osteoradionecrosis. So, it's mostly indicated for soft tissue involvement (Antoniades *et al.*, 2003).

RMT carcinoma are heterogeneous tumours by different tumour biology and local extension.

In a study 22 patients underwent inferior maxillectomy of the posterior alveolar process of the upper jaw for cancer involving maxillary antrum. But, the incidence in mandibular bone was lower (91%) (Kowalski, Hashimoto and Magrin, 1993), (Genden *et al.*, 2003).

In another study by Goldie *et al.*, with masticatory space involvement 3 had local recurrences, 8 died of the disease. Patients with masticator space involvement and mandible involvement had poor prognosis (Goldie, Soutar and Shaw-Dunn, 2006).

The adjuvant radiation therapy is reserved for patients with stage III and IV diseases. Madenhall *et al.* had 99 patients with irradiation alone or combined treatment of irradiation and surgery. 52% for irradiation and 69% for combination therapy where the survival rates (Skolnik, Campbell and Meyers, 1972).

Byers *et al.* suggested conservation of extent of mandible bone resections. But they had a 5-year-old survival rate of 20% (Byers *et al.*, 1984).

This study could be further improved by increasing sample size and checking the various factors affecting the spread and prognosis of treatment of RMT carcinoma with trismus.

## CONCLUSION

Oral squamous cell carcinoma is a commonly occurring oral cancer and it is associated with significant mortality and morbidity. The main disadvantage in RMT carcinoma is reduced mouth opening which occurs at advanced stages of the disease, which makes it difficult to provide acceptable cure and prognosis. To conclude, in this study, the majority of the patients had improved mouth opening after surgery and those with severe restriction of mouth

opening also had a moderate increase in mouth opening after the surgery. The recurrence of disease in patients with carcinoma of RMT was less in both groups (with trismus and without trismus) after a 6 months follow up.

#### **AUTHORS CONTRIBUTION**

First author, Sindhupriya performed the data collection by reviewing patient details, filtering required data, analysing and interpreting statistics and contributed to manuscript writing.

Second author, Dr. Mahathi contributed to conception of study title, study design, analysed the collected data, statistics and interpretation and also critically revised the manuscript.

Third author, Dr. Suresh.V participated in the study and revised the manuscript. All the three authors have discussed the results and contributed to the final manuscript.

#### **ACKNOWLEDGMENT**

This research was supported by Saveetha Dental College and Hospital. We thank the department of Oral Medicine, Saveetha Dental College for providing insight and expertise that greatly assisted this research.

**Conflict of interest:** The authors declare that there is no conflict of interests.

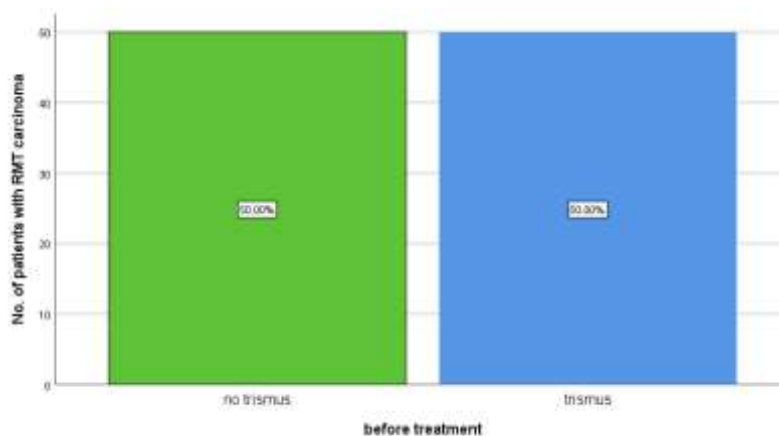
#### **REFERENCES**

1. Petruzzelli, GT Knight. Posterior marginal mandibulectomy in the management of cancer of oral cavity and oropharynx. 2003;129:713-719(Petruzzelli *et al.*, 2003)
2. AJCC manual for staging of cancer. 2002(Edge *et al.*, 2010)
3. Hao SP, Cheng MH cancer of buccal mucosa and trigone area. 2004;15; 239-251(Hao and Cheng, 2004)
4. Byers RM, Anderson B. treatment of squamous carcinoma of retromolar trigone. 1954;7;647-652(Byers *et al.*, 1984)
5. Medenhall WM, Morris CG. Retromolar trigone squamous cell carcinoma treated with radiotherapy or combined with surgery. 2005; 11:2320-2325(Mendenhall *et al.*, 2005)
6. Hashimoto L, Margin L. extended commando operations for retromolar trigone carcinoma. 1993;166;374-379 (Kowalski, Hashimoto and Magrin, 1993)
7. Jesudasan JS, Wahab PA, Sekhar MM. Effectiveness of 0.2% chlorhexidine gel and a eugenol-based paste on postoperative alveolar osteitis in patients having third molars extracted: a randomised controlled clinical trial. British Journal of Oral and Maxillofacial Surgery. 2015 Nov 1;53(9):826-30.
8. Santhosh Kumar, M.P., RAHMAN R. Knowledge, awareness, and practices regarding biomedical waste management among undergraduate dental students. Asian J Pharm Clin Res. 2017;10(8):341- 5.
9. Christabel A, Anantanarayanan P, Subash P, Soh CL, Ramanathan M, Muthusekhar MR, Narayanan V. Comparison of pterygomaxillary dysjunction with tuberosity separation in isolated Le Fort I osteotomies: A prospective, multi-centre, triple-blind, randomized controlled trial. International journal of oral and maxillofacial surgery. 2016 Feb 1;45(2): 180-5.
10. Marimuthu M, Andiappan M, Wahab A, Muthusekhar MR, Balakrishnan A, Shanmugam S. Canonical Wnt pathway gene expression and their clinical correlation in oral squamous cell carcinoma. Indian Journal of Dental Research. 2018 May 1;29(3):291.
11. Packiri S, Gurunathan D, Selvarasu K. Management of paediatric oral ranula: a systematic review. Journal of clinical and diagnostic research: JCDR. 2017 Sep;11 (9):ZE06
12. Santhosh Kumar, M.P. Relationship between dental anxiety and pain experience during dental extractions. Asian J Pharm Clin Res. 2017;10(3):458- 61.
13. Patil SB, Durairaj D, Kumar GS, Karthikeyan D, Pradeep D. Comparison of extended nasolabial flap versus buccal fat pad graft in the surgical management of oral submucous fibrosis: a prospective pilot study. Journal of maxillofacial and oral surgery. 2017 Sep 1;16(3):312-21.
14. Rao TD, Santhosh Kumar, M.P. Analgesic Efficacy of Paracetamol Vs Ketorolac after Dental Extractions. Research Journal of Pharmacy and Technology. 2018;11(8): 3375-9.
15. Abhinav RP, Selvarasu K, Maheswari GU, Taltia AA. The patterns and etiology of maxillofacial trauma in South India. Annals of maxillofacial surgery. 2019 Jan;9(1): 114.
16. Santhosh Kumar, M.P., Snea S. Knowledge and awareness regarding antibiotic prophylaxis for infective endocarditis among undergraduate dental students. Asian J Pharm Clin Res. 2016;9: 154-9.
17. Santhosh Kumar, M.P. The emerging role of botulinum toxin in the treatment of orofacial disorders: Literature update. Asian J Pharm Clin Res. 2017;10(9):21-9.
18. Rahman R, Santhosh Kumar, M.P. Knowledge, attitude, and awareness of dental undergraduate students regarding human immunodeficiency virus/acquired immunodeficiency syndrome patients. Asian J Pharm Clin Res. 2017;10(5):175- 80.
19. Santhosh Kumar, M.P., Sneha S. Knowledge and awareness regarding antibiotic prophylaxis for infective endocarditis among undergraduate dental students. Asian J Pharm Clin Res. 2016;9: 154-9.
20. Patturaja K, Pradeep D. Awareness of Basic Dental Procedure among General Population. Research Journal

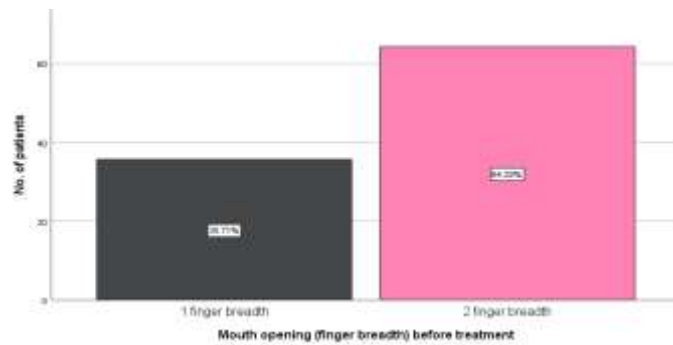
- of Pharmacy and Technology. 2016;9(9): 1349-51.
21. Jain SV, Muthusekhar MR, Baig MF, Senthilnathan P, Loganathan S, Wahab PA, Madhulakshmi M, Vohra Y. Evaluation of three-dimensional changes in pharyngeal airway following isolated lefort one osteotomy for the correction of vertical maxillary excess: a prospective study. *Journal of maxillofacial and oral surgery*. 2019 Mar 8;18(1):139-46.
  22. Wang CC, Hao SP. Cancer of buccal mucosa and retromolar trigone. 2004;15;239-251(De Vries, Van Der Waal and Snow, 1986)
  23. Lazardis, antoniades V. treatment of squamous cell carcinoma treatment anterior faucial pillar- retromolar trigone. 2009;39;680-686(Antoniades *et al.*, 2003)
  24. Treatment of squamous cell carcinoma of the anterior faucial pillar-retromolar trigone. Antoniades K, Lazardidis N, Vahtsevanos K, et al. *Oral Oncol.* (Antoniades *et al.*, 2003)2003;39:680-686
  25. End results of 114 extended “commando” operation for the retromolar trigone carcinoma. Kowalski L, Hashimoto I, Magrin J. *Am J Surg.* 1993;166:374-379.(Kowalski, Hashimoto and Magrin, 1993)
  26. Treatment of squamous carcinoma of the retromolar trigone. Byers R, Anderson B, Schwars E, et al. *Am J Clin Oncol.* 1984;7:647-652.(Byers *et al.*, 1984)
  27. Management of cancer of the retromolar trigone. Genden E, Ferlito A, Shaha A, et al. *Oral Oncol.* 2003;39:633-637.(Genden *et al.*, 2003)
  28. The effect of surgical resection in the region of the retromolar trigone. Goldie SJ, Soutar DS, Shaw-Dunn J. *J Plast Reconstr Aesthet Surg.* 2006;59:1263-1268.(Goldie, Soutar and Shaw-Dunn, 2006)
  29. Carcinoma of the buccal mucosa and retromolar area. Skolnik EM, Campbell JM, Meyers RM. *Otolaryngol Clin North Am.* 1972;5:327-331.(Skolnik, Campbell and Meyers, 1972)
  30. Abraham, S. *et al.* (2005) ‘Evaluation of the inhibitory effect of triphala on PMN-type matrix metalloproteinase (MMP-9)’, *Journal of periodontology*, 76(4), pp. 497-502.
  31. Antoniades, K. *et al.* (2003) ‘Treatment of squamous cell carcinoma of the anterior faucial pillar-retromolar trigone’, *Oral oncology*, 39(7), pp. 680-686.
  32. Arja, C. *et al.* (2013) ‘Oxidative stress and antioxidant enzyme activity in South Indian male smokers with chronic obstructive pulmonary disease’, *Respirology*, 18(7), pp. 1069-1075.
  33. Byers, R. M. *et al.* (1984) ‘Treatment of squamous carcinoma of the retromolar trigone’, *American journal of clinical oncology*, 7(6), pp. 647-652.
  34. Devaki, T., Sathivel, A. and BalajiRaghavendran, H. R. (2009) ‘Stabilization of mitochondrial and microsomal function by polysaccharide of *Ulva lactuca* on D-Galactosamine induced hepatitis in rats’, *Chemico-biological interactions*, 177(2), pp. 83-88.
  35. De Vries, N., Van Der Waal, I. and Snow, G. B. (1986) ‘Multiple primary tumours in oral cancer’, *International journal of oral and maxillofacial surgery*, 15(1), pp. 85-87.
  36. Edge, S. B. *et al.* (2010) *AJCC cancer staging manual*. Springer New York.
  37. Ezhilarasan, D. (2018) ‘Oxidative stress is bane in chronic liver diseases: Clinical and experimental perspective’, *Arab journal of gastroenterology: the official publication of the Pan-Arab Association of Gastroenterology*, 19(2), pp. 56-64.
  38. Ezhilarasan, D., Sokal, E. and Najimi, M. (2018) ‘Hepatic fibrosis: It is time to go with hepatic stellate cell-specific therapeutic targets’, *Hepatobiliary & pancreatic diseases international: HBPD INT*, 17(3), pp. 192-197.
  39. Genden, E. M. *et al.* (2003) ‘Management of cancer of the retromolar trigone’, *Oral oncology*, 39(7), pp. 633-637.
  40. Goldie, S. J., Soutar, D. S. and Shaw-Dunn, J. (2006) ‘The effect of surgical resection in the region of the retromolar trigone’, *Journal of plastic, reconstructive & aesthetic surgery: JPRAS*, 59(12), pp. 1263-1268.
  41. Hao, S.-P. and Cheng, M. H. (2004) ‘Cancer of the buccal mucosa and retromolar trigone’, *Operative Techniques in Otolaryngology-Head and Neck Surgery*, 15(4), pp. 239-251.
  42. J, P. C. *et al.* (2018) ‘Prevalence and measurement of anterior loop of the mandibular canal using CBCT: A cross sectional study’, *Clinical implant dentistry and related research*, 20(4), pp. 531-534.
  43. Kowalski, L. P., Hashimoto, I. and Magrin, J. (1993) ‘End results of 114 extended “commando” operations for retromolar trigone carcinoma’, *American journal of surgery*, 166(4), pp. 374-379.
  44. Krishnaswamy, H. *et al.* (2020) ‘Investigation of air conditioning temperature variation by modifying the structure of passenger car using computational fluid dynamics’, *Thermal Science*, 24(1 Part B), pp. 495-498.
  45. Malli Sureshbabu, N. *et al.* (2019) ‘Concentrated Growth Factors as an Ingenious Biomaterial in Regeneration of Bony Defects after Periapical Surgery: A Report of Two Cases’, *Case reports in dentistry*, 2019, p. 7046203.
  46. Manivannan, I. *et al.* (2017) ‘Tribological and surface behavior of silicon carbide reinforced aluminum matrix nanocomposite’, *Surfaces and Interfaces*, 8, pp. 127-136.
  47. Mehta, M. *et al.* (2019) ‘Oligonucleotide therapy: An emerging focus area for drug delivery in chronic inflammatory respiratory diseases’, *Chemico-biological interactions*, 308, pp. 206-215.

48. Mendenhall, W. M. *et al.* (2005) 'Retromolar trigone squamous cell carcinoma treated with radiotherapy alone or combined with surgery', *Cancer*, 103(11), pp. 2320–2325.
49. Neelakantan, P. *et al.* (2010) 'Root and Canal Morphology of Mandibular Second Molars in an Indian Population', *Journal of endodontics*, 36(8), pp. 1319–1322.
50. Neelakantan, P. *et al.* (2015) 'Photoactivation of curcumin and sodium hypochlorite to enhance antibiofilm efficacy in root canal dentin', *Photodiagnosis and photodynamic therapy*, 12(1), pp. 108–114.
51. Petruzzelli, G. J. *et al.* (2003) 'Posterior marginal mandibulectomy in the management of cancer of the oral cavity and oropharynx', *Otolaryngology--head and neck surgery: official journal of American Academy of Otolaryngology-Head and Neck Surgery*, 129(6), pp. 713–719.
52. Ramamoorthi, S., Nivedhitha, M. S. and Divyanand, M. J. (2015) 'Comparative evaluation of postoperative pain after using endodontic needle and EndoActivator during root canal irrigation: A randomised controlled trial', *Australian endodontic journal: the journal of the Australian Society of Endodontology Inc*, 41(2), pp. 78–87.
53. Ramshankar, V. *et al.* (2014) 'Risk stratification of early stage oral tongue cancers based on HPV status and p16 immunoeexpression', *Asian Pacific journal of cancer prevention: APJCP*, 15(19), pp. 8351–8359.
54. Ravindiran, M. and Praveenkumar, C. (2018) 'Status review and the future prospects of CZTS based solar cell – A novel approach on the device structure and material modeling for CZTS based photovoltaic device', *Renewable and Sustainable Energy Reviews*, 94, pp. 317–329.
55. Samuel, S. R., Acharya, S. and Rao, J. C. (2020) 'School Interventions-based Prevention of Early-Childhood Caries among 3-5-year-old children from very low socioeconomic status: Two-year randomized trial', *Journal of public health dentistry*, 80(1), pp. 51–60.
56. Sathish, T. and Karthick, S. (2020) 'Wear behaviour analysis on aluminium alloy 7050 with reinforced SiC through taguchi approach', *Journal of Materials Research and Technology*, 9(3), pp. 3481–3487.
57. Skolnik, E. M., Campbell, J. M. and Meyers, R. M. (1972) 'Carcinoma of the buccal mucosa and retromolar area', *Otolaryngologic clinics of North America*, 5(2), pp. 327–331.
58. Sumathi, C. *et al.* (2014) 'Production of prodigiosin using tannery fleshing and evaluating its pharmacological effects', *TheScientificWorldJournal*, 2014, p. 290327.
59. Surapaneni, K. M. and Jainu, M. (2014) 'Comparative effect of pioglitazone, quercetin and hydroxy citric acid on the status of lipid peroxidation and antioxidants in experimental non-alcoholic steatohepatitis', *Journal of physiology and pharmacology: an official journal of the Polish Physiological Society*, 65(1), pp. 67–74.
60. Surapaneni, K. M., Priya, V. V. and Mallika, J. (2014) 'Pioglitazone, quercetin and hydroxy citric acid effect on cytochrome P450 2E1 (CYP2E1) enzyme levels in experimentally induced non alcoholic steatohepatitis (NASH)', *European review for medical and pharmacological sciences*, 18(18), pp. 2736–2741.
61. Wang, B. *et al.* (2013) 'The recurrence and survival of oral squamous cell carcinoma: a report of 275 cases', *Chinese journal of cancer*, 32(11), pp. 614–618.

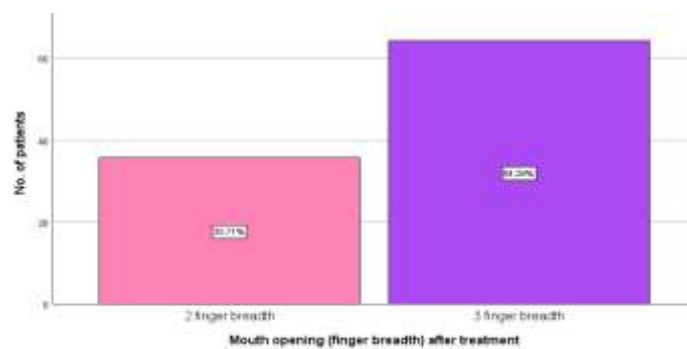
## GRAPHS



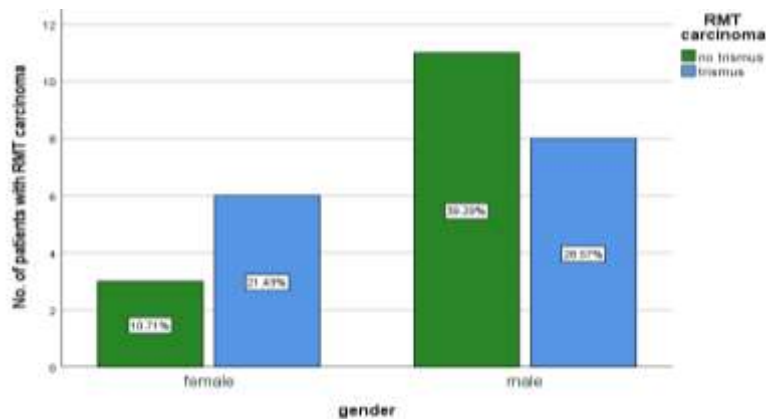
**Fig.1:** Bar graph represents the percentage of patients with and without trismus before treatment. X-axis represents the patients with and without trismus before treatment. Y-axis represents the percentage of patients. From the graph it is evident that before treatment of RMT cancer there was 50% without trismus (green bar) and 50% with trismus (blue bar).



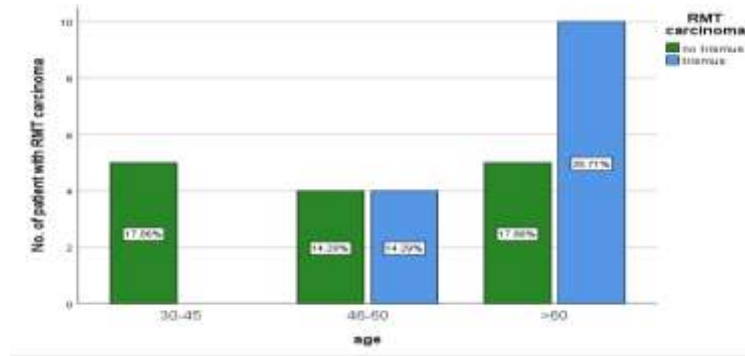
**Fig.2:** Bar graph represents the amount of mouth opening of patients with trismus before treatment for RMT carcinoma. X-axis represents the patients with the amount of mouth opening. Y-axis represents the number of patients. From the graph it is evident that before treatment out of the 14 patients with trismus, 35.71% (grey) had 1 finger breadth mouth opening and 64.29% had 2 finger breadth (pink).



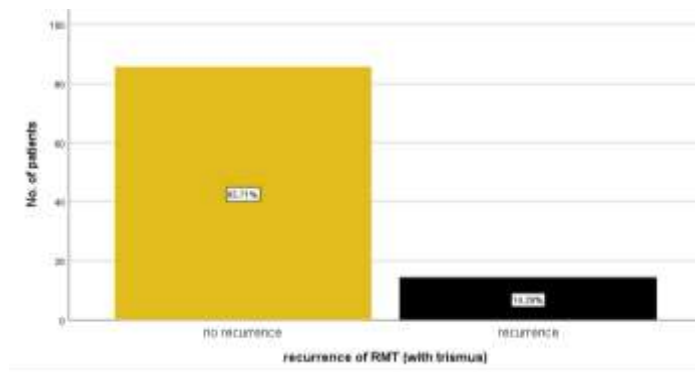
**Fig.3:** Bar graph represents the amount of mouth opening of patients with trismus after treatment for RMT carcinoma. X-axis represents the patients with the amount of mouth opening. Y-axis represents the number of patients. From the graph it is evident that after treatment out of the 14 patients with trismus, 35.71% (pink) had 2 finger breadth mouth opening and the rest of the patients (64.29%) had mouth opening of 3 finger breadth (purple).



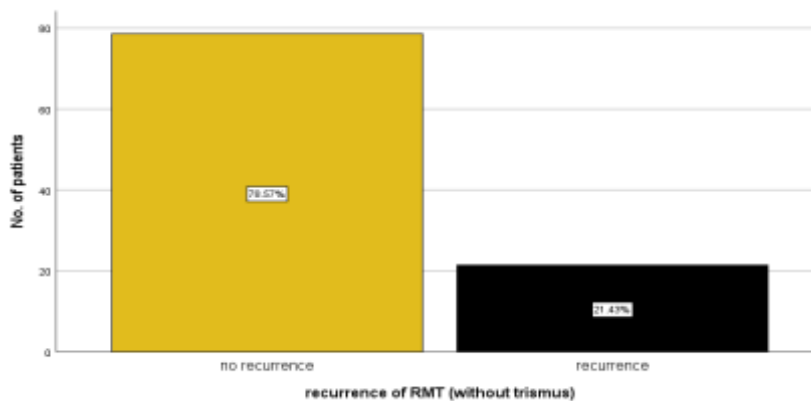
**Fig.4:** Bar graphs represent the association between gender and RMT carcinoma. X-axis represents the gender of patients. Y-axis represents the percentage of RMT patients with trismus and no trismus. Males (28.57%) had a higher percentage of trismus than females (21.43%) (blue bar). Chi-square test was done and the association was found to be statistically significant. Pearson's Chi-square value: 0.291, DF:2, p value: 0.045 (<0.05) hence statistically significant, proving that more males than females represented trismus.



**Fig.5:** Bar graphs represent the association of age and RMT Carcinoma. X-axis represents the age of patients. Y-axis represents the percentage of RMT patients with trismus and no trismus. Majority of patients who had trismus (35.71%) (blue) were above 60 years of age. Chi-square test was done and the association was found to be statistically significant. Pearson's Chi-square value: 0.434, DF:2, p value: 0.045 (<0.05) hence statistically significant, proving that older the patients the higher the percentage of trismus.



**Fig.6:** Bar graph represents the number of patients with and without recurrence (with trismus). X-axis represents the patients with and without recurrence. Y-axis represents the number of patients. From the graph it is evident that after treatment, there was 14.29% with recurrence and 85.71% without recurrence (previous trismus).



**Fig.7:** Bar graph represents the number of patients with and without recurrence (without trismus). X-axis represents the patients with and without recurrence. Y-axis represents the number of patients. From the graph it is evident that after treatment, there was 21.43% with recurrence and 78.57% without recurrence (no previous trismus).