

---

## En Masse Distalization As A Treatment Option In Correction Of Skeletal Class II Malocclusion.

---

AKSHAY MOHAN<sup>1</sup>, HARISH BABU<sup>2\*</sup>, NIVETHIGAA BALAKRISHNAN<sup>3</sup>

<sup>1</sup>Department of Orthodontics and Dentofacial Orthopaedics, Saveetha Dental College, Saveetha Institute of Medical and Technical Sciences, Saveetha University, 162, Poonamallee High Road, Chennai-600077, Tamil Nadu, India

<sup>2</sup>Professor, Department of Orthodontics and Dentofacial Orthopaedics, Saveetha Dental College, Saveetha Institute of Medical and Technical Sciences, Saveetha University, 162, Poonamallee High Road, Chennai-600077, Tamil Nadu, India

<sup>3</sup>Senior Lecturer, Department of Orthodontics and Dentofacial Orthopaedics, Saveetha Dental College, Saveetha Institute of Medical and Technical Sciences, Saveetha University, 162, Poonamallee High Road, Chennai-600077, Tamil Nadu, India

\*Corresponding Author:

Email : 151808005.sdc@saveetha.com<sup>1</sup>, harish.ortho@gmail.com<sup>2</sup>, nivethigaab.sdc@saveetha.com<sup>3</sup>

---

**Abstract:** Treatment of skeletal Class II malocclusion in a growing patient will involve growth modification therapy using myofunctional appliances. In case of some patients non compliance Class II correctors may be used to correct discrepancies. Skeletal Class II malocclusion due to prognathic maxilla may require headgears for correction. The introduction of infra zygomatic screws and buccal shelf screws have broadened the scope of Class II correction in late adolescence and adults. Invariably patients with skeletal Class II malocclusions do not report to the orthodontists at a time when growth can be harnessed for correction of the skeletal malocclusion. In most of these cases camouflage treatment or orthognathic surgery were the options. Bone screws have now changed the scenario providing patients with the option of en masse distalisation not involving extractions or surgery. This study aims to evaluate the treatment options not involving growth modification chosen for patients with skeletal Class II malocclusion. Patient records were screened for skeletal Class II malocclusion, patients from the age group of 14 to 35 were chosen for the study. Patients undergoing treatment with myofunctional appliances and non compliance Class II correctors were eliminated from the study. A total of 80 patient records were obtained. Data on age, gender and treatment plan were tabulated. Samples were divided into three groups based on treatment plan. Group A (N= 50) represented camouflage treatment, Group B (N= 16) represented en masse distalisation and Group C (N= 14) represented orthognathic surgery. The association between age, gender and treatment plan was tested using Pearson's test of independence. Results of the study showed that 62.5% of all patients in the study had undergone camouflage treatment with only 20% undergoing en masse distalisation. 17.5% of patients had undergone orthognathic surgery. It was observed that the age group of 20-24 years contributed to the maximum number of patients reporting for correction of Class II skeletal malocclusions. Pearson Chi-Square value of 2.843 and p-value of 0.241 (p-value < 0.05 significant) showed that there was no association between gender and treatment plan chosen. Pearson's Chi Square value of 18.09 and p value of 0.021 (p value < 0.05, statistically significant) showed an association between age and treatment plan chosen for the patient. From the results of the study it can be concluded that there was an association between age and treatment plan in correction of Class II malocclusion. En masse distalisation as a treatment option was predominantly chosen in late adolescence and young adults.

**Keywords:** class II malocclusion; camouflage; orthognathic surgery; en masse distalization.

---

### INTRODUCTION

Class II malocclusion is characterised by disto occlusion, which reflects on adjacent elements such as soft tissue and other teeth. This malocclusion is common in orthodontic practice and its correction can be attained by several treatment protocols, such as en masse distalization, camouflage and orthognathic surgery. Class II malocclusion is considered the most frequent problem presenting in the orthodontic practice affecting 37% of school children in Europe and occurring in 33% of all orthodontic patients in the USA. Class II malocclusion may also involve craniofacial variances which can be adjusted when patients are adolescent. The regular treatment options in growing patients include extraoral headgears, functional appliances and full fixed

appliances with intermaxillary or teeth extractions. In adults, moderate class II malocclusion can be corrected with fixed orthodontic appliance in conjunction with extractions, severe malocclusions with fixed appliances and orthognathic surgery while the efficiency of these conventional treatment modalities has improved, particularly in growing patients, most require patient cooperation in order to be effective which is often a primary problem. Where there is a mild or moderate class II malocclusion is an adult or an adolescent who is too old for growth modification, camouflage by tooth movement can be used by distalizing maxillary molars, followed by the entire maxillary arch; or extraction of premolars and retraction of maxillary anterior teeth into extraction space; or combination of maxillary arch and forward movement of mandibular. Individual variation in dental and soft tissue morphology treatment plans must be tailored to each patient's diagnosis, needs and goals, including treatment approach, choice and biomechanics.

The majority of Class II molar relationships tend to be accompanied with an underlying anteroposterior skeletal discrepancy, Class II canine relationship, and excessive overjet. With molar distalization being a prerequisite for nonextraction treatment of Class II patients, various intraoral appliances and techniques such as distalizing arches (Muse et al., 1993) distal jet appliances (Carano and Testa, 2001) and pendulum appliances (Fuzyi et al., 2006), have been shown to be effective. Nevertheless, significant forward movement of the premolars and incisors was found to be inevitable in response to molar distalization. Once maxillary molars are distalized, they are prone to relapse during the retraction of premolars and incisors, making overcorrection of the molars to a Class III position crucial. In conventional Class II treatment, efficient treatment necessitated predictable molar distalization and subsequent incisor retraction without burning anchorage. The segmental distalization using either miniplates or miniscrews can be effective (Sugawara et al., 2006; Yamada et al., 2009), in that they could eliminate the possibility of round-tripping the anterior teeth. Accordingly, the possibility of en-masse distalization using interradicular miniscrews or miniplates has been proposed.

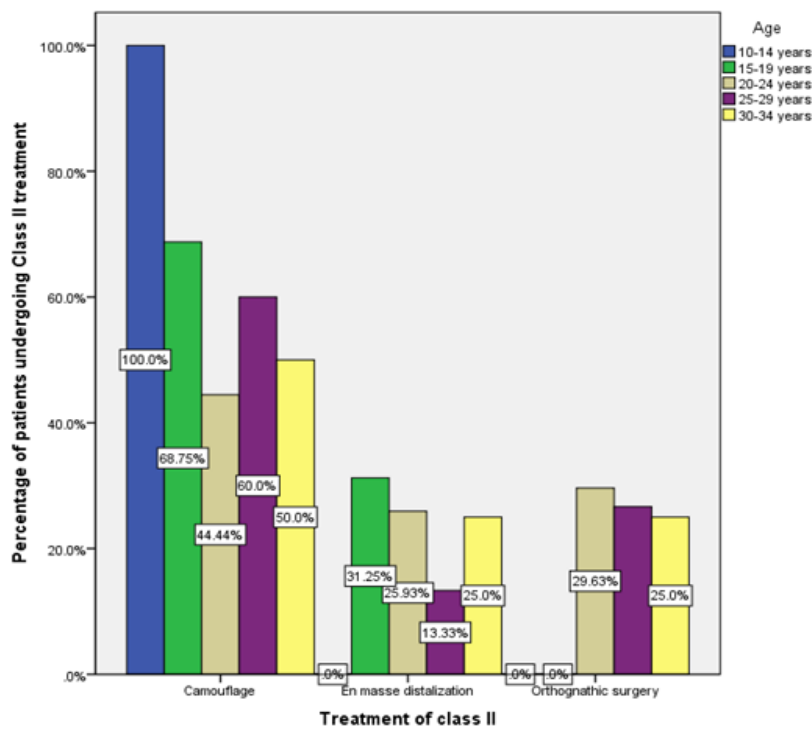
Monocortical miniscrew-type temporary anchorage devices have been widely used to move a single tooth or segments of teeth (Lee et al., 2007) (Park et al., 2003). Many studies have proposed simultaneous distalization of the entire dentition by applying force vector(s) from interradicular miniscrews to the main archwire. The basic concept is that a distalizing force applied to the anterior segment might be transmitted to the posterior segment along the continuous archwire and proximal contact points, leading to distalization of the molars as well as the incisors. In orthodontic camouflage treatment, the aim is to mask the skeletal discrepancy through dental compensations. When extractions are required, they are generally done in the upper arch (first premolars) to correct the protrusion of the incisors. Orthodontic-surgical treatment is intended to correct the underlying skeletal class II deformity, and in most surgical patients, only mandibular advancement surgery is required to correct mandibular retrognathia. However, some patients require superior repositioning of the maxilla or bimaxillary surgery (maxilla up and mandible forward). The two single-jaw procedures are considered very stable, whereas the combination of maxillary and mandibular surgery is stable only with rigid fixation. Our team has rich experience in research and we have collaborated with numerous authors over various topics in the past decade (Deogade, Gupta and Ariga, 2018; Ezhilarasan, 2018; Ezhilarasan, Sokal and Najimi, 2018; Jeevanandan and Govindaraju, 2018; J et al., 2018; Menon et al., 2018; Prabakar et al., 2018; Rajeshkumar et al., 2018, 2019; Vishnu Prasad et al., 2018; Wahab et al., 2018; Dua et al., 2019; Duraisamy et al., 2019; Ezhilarasan, Apoorva and Ashok Vardhan, 2019; Gheena and Ezhilarasan, 2019; Malli Sureshbabu et al., 2019; Mehta et al., 2019; Panchal, Jeevanandan and Subramanian, 2019; Rajendran et al., 2019; Ramakrishnan, Dhanalakshmi and Subramanian, 2019; Sharma et al., 2019; Varghese, Ramesh and Veeraiyan, 2019; Gomathi et al., 2020; Samuel, Acharya and Rao, 2020)

The aim of the study is to evaluate the the association between age wise distribution of patients reported with Angle's class II malocclusion and the treatment of class II malocclusion, and to assess the percentage distribution of various class II malocclusion treatment modalities available to them.

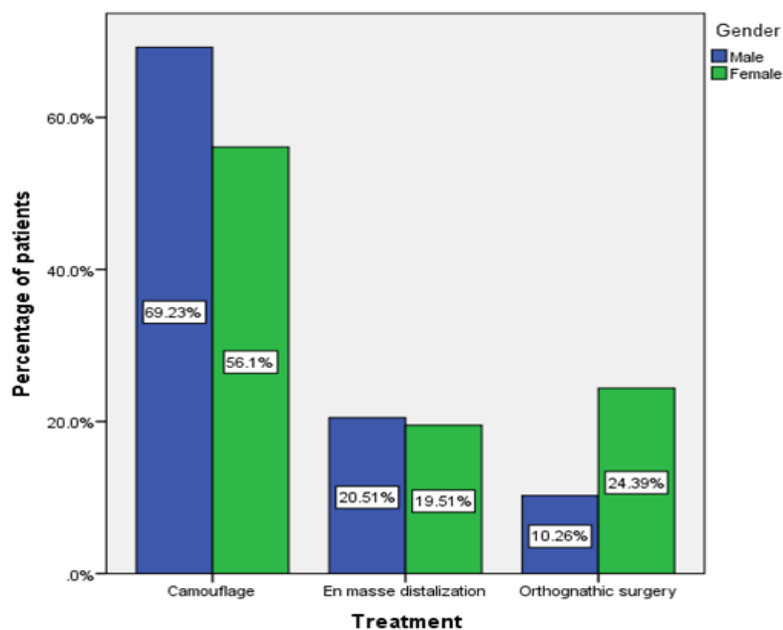
## **MATERIALS AND METHODOLOGY**

This retrospective cross-sectional study was done on skeletal class II malocclusion patients who reported to the department of orthodontics and dentofacial orthopedics from 01 June 2019 to 31 March 2020. The study was approved by the ethical committee and institutional research board (SDC/SIHEC/2020/DIASDATA/0619-0320). The dental records of 960 patients who were registered to the institution and are undergoing orthodontic correction were analysed for the study. Patients belonging to the age group of 10-34 years with skeletal class II malocclusion and ANB angle above 4 degrees were selected for the study. Patients who had systemic illness, skeletal class I malocclusion, skeletal class III malocclusion and craniofacial deformities were excluded. 80 subjects were selected based on the inclusion and exclusion criteria from the total sample of 160 subjects. The analysis was carried out using the statistical package for social sciences version 20.0 (SPSS Inc, Chicago, IL, USA). Chi Square tests, descriptive statistics and percentage distribution of class II malocclusion treatment were evaluated.

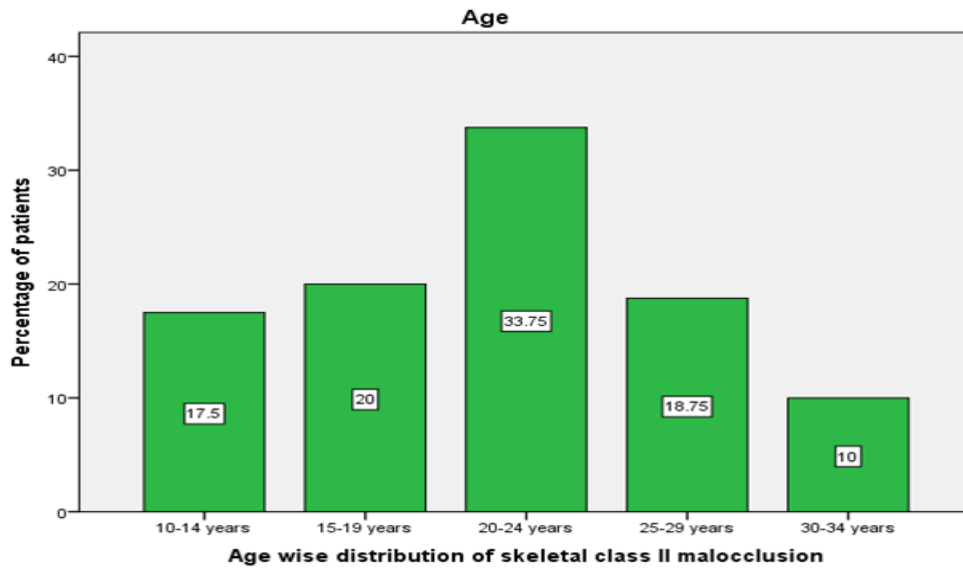**RESULTS AND DISCUSSION**



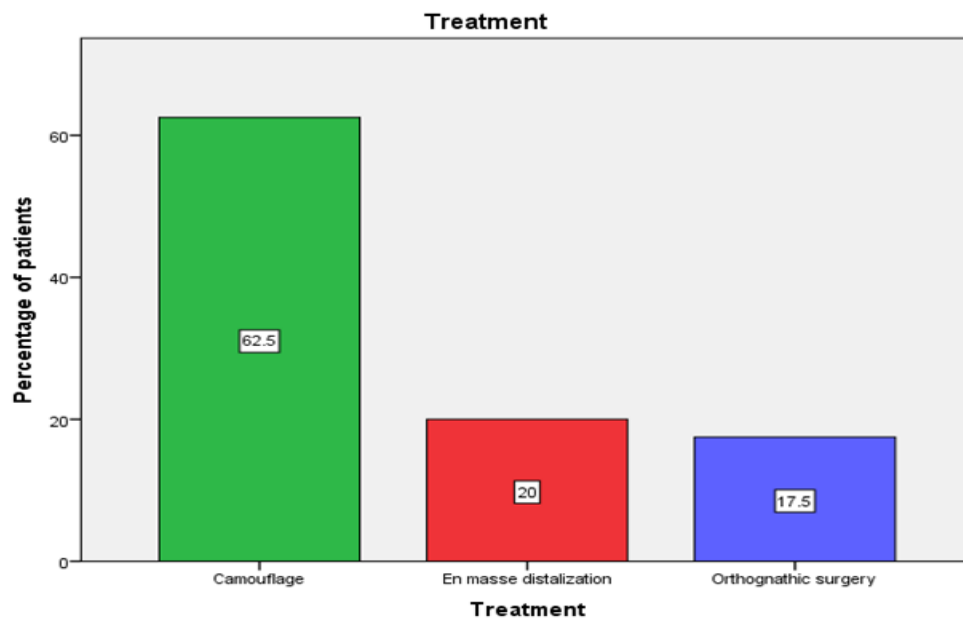
**Fig.1: Cluster Bar graph depicting the association between age wise distribution of samples and the treatment plan. X axis represents the various treatment plans for skeletal class II and Y axis represents the percentage of patients undergoing class II treatment in each group. Pearson Chi Square value was 18.09 and p-value of 0.021 (p value < 0.05 statistically significant), hence the preferred treatment option and age are associated. Camouflage option was mostly chosen in early adolescence and en masse distalization in late adolescence and young adults.**



**Fig.2 : Bar graph depicting the association between the treatment plan and gender. X axis represents the treatment plan and Y axis represents the percentage of patients in each group. Pearson Chi-Square was 2.843 and p value of 0.241 (p value > 0.05, not significant) implying that there was no major difference in treatment plan chosen among genders.**



**Fig.3 :** Bar graph depicting the number of patients with skeletal class II malocclusion across various age groups. X axis represents the age wise distribution of patients with class II malocclusion and Y axis represents the percentage of patients with malocclusion. Highest percentage of patients - 33.75% belonged to the age group of 20-24 and lowest percentage of patients - 10% belonged to the age group of 30-34 years of age. It was found that the majority of the subjects who sought orthodontic treatment were in late adolescence or young adults.



**Fig.4 :** Bar graph depicting the frequency of patients with skeletal class II malocclusion undergoing treatment . X axis represents the treatment options for patients with class II malocclusion and Y axis represents the percentage distribution of patients. It was found that the majority of the subjects who sought orthodontic treatment were widely treated by camouflage and en masse distalization

Previously our investigators had conducted clinical trials (Kamisetty et al., 2015; Krishnan, Pandian and Kumar S, 2015; Viswanath et al., 2015; Sivamurthy and Sundari, 2016; Felicita, 2017b; Samantha et al., 2017; Vikram et al., 2017), lab animal studies (Ramesh Kumar et al., 2011; Jain, Kumar and Manjula, 2014; Rubika, Sumathi Felicita and Sivambiga, 2015; Felicita, 2017a; Pandian, Krishnan and Kumar, 2018) and in - vitro studies(Felicita, Chandrasekar and Shanthasundari, 2012; Dinesh et al., 2013; Felicita, 2018) over the past 5 years. Now we are focussing on cross sectional study from our database. Out of the 80 subjects selected, there were 39 males and 41 females. All were undergoing treatment for skeletal class II malocclusion which did not

involve growth modification. All subjects belonged to the age group of 14 to 34 years. The percentage distribution of each treatment option was estimated and results were evaluated. Treatment of class II malocclusion in adolescents has mainly relied on growth modification. The majority of treatment options are directed at stopping or redirecting maxillary growth and stimulating mandibular growth. Molar distalization in adults has been considered difficult, which is contrasted by recent evidence of molar distalization using mini plates fixed with multiple bone screws (Sugawara et al., 2006) (Sugawara et al., 2004), with a major advantage being the elimination of side effects such as forward movement of premolars and incisors. Treatment of class II in adults is always challenging. Applying sound biomechanics principles to execute the mechanics plan is the surest way to achieve predictable results. Treatment of an adult class II requires careful diagnosis and treatment plan involving esthetic, occlusion and functional consideration. The treatment objective must include the chief complaint of the patient and the mechanics plan should be individualised based on the specific treatment goals. The study was to evaluate the various treatment options like en masse distalization, camouflage and surgical correction used among class II malocclusion. The results of the study showed that the camouflage treatment option was widely used among adolescents and adults whereas en masse distalization was predominantly used amongst late adolescents and young adults. Surgical management of skeletal class II was favoured amongst adults. The study also showed that there is statistically significant association between age and treatment plan chosen for the patient. Our institution is passionate about high quality evidence based research and has excelled in various fields (Pc, Marimuthu and Devadoss, 2018; Ramesh et al., 2018; Ezhilarasan, Apoorva and Ashok Vardhan, 2019; Ramadurai et al., 2019; Sridharan et al., 2019; Vijayashree Priyadharsini, 2019; Mathew et al., 2020)

## CONCLUSION

Within the limits of this study it can be concluded that there was a statistically significant association between age and treatment plan chosen for the patients. The study also shows that en masse distalisation as a treatment option was predominantly chosen in late adolescence and young adults. The limitations of the present study is that it is a retrospective cross sectional unicentric study done on a smaller section of the population. A prospective multicentric study on treatment options in correction of skeletal class II malocclusion is the need of the hour.

## REFERENCES

1. Carano, A. and Testa, M. (2001) 'Distal jet designed to be used alone', *American Journal of Orthodontics and Dentofacial Orthopedics*, p. 13A–14A. doi: 10.1067/mod.2001.121367.
2. Deogade, S., Gupta, P. and Ariga, P. (2018) 'Effect of monopoly-coating agent on the surface roughness of a tissue conditioner subjected to cleansing and disinfection: A Contact Profilometric In vitro study', *Contemporary Clinical Dentistry*, p. 122. doi: 10.4103/ccd.ccd\_112\_18.
3. Dinesh, S. P. S. et al. (2013) 'An indigenously designed apparatus for measuring orthodontic force', *Journal of clinical and diagnostic research: JCDR*, 7(11), pp. 2623–2626.
4. Dua, K. et al. (2019) 'The potential of siRNA based drug delivery in respiratory disorders: Recent advances and progress', *Drug development research*, 80(6), pp. 714–730.
5. Duraisamy, R. et al. (2019) 'Compatibility of Nonoriginal Abutments With Implants: Evaluation of Microgap at the Implant-Abutment Interface, With Original and Nonoriginal Abutments', *Implant dentistry*, 28(3), pp. 289–295.
6. Ezhilarasan, D. (2018) 'Oxidative stress is bane in chronic liver diseases: Clinical and experimental perspective', *Arab journal of gastroenterology: the official publication of the Pan-Arab Association of Gastroenterology*, 19(2), pp. 56–64.
7. Ezhilarasan, D., Apoorva, V. S. and Ashok Vardhan, N. (2019) 'Syzygium cumini extract induced reactive oxygen species-mediated apoptosis in human oral squamous carcinoma cells', *Journal of oral pathology & medicine: official publication of the International Association of Oral Pathologists and the American Academy of Oral Pathology*, 48(2), pp. 115–121.
8. Ezhilarasan, D., Sokal, E. and Najimi, M. (2018) 'Hepatic fibrosis: It is time to go with hepatic stellate cell-specific therapeutic targets', *Hepatobiliary & pancreatic diseases international: HBPD INT*, 17(3), pp. 192–197.
9. Felicita, A. S. (2017a) 'Orthodontic management of a dilacerated central incisor and partially impacted canine with unilateral extraction - A case report', *The Saudi dental journal*, 29(4), pp. 185–193.
10. Felicita, A. S. (2017b) 'Quantification of intrusive/retraction force and moment generated during en-masse retraction of maxillary anterior teeth using mini-implants: A conceptual approach', *Dental press journal of orthodontics*, 22(5), pp. 47–55.
11. Felicita, A. S. (2018) 'Orthodontic extrusion of Ellis Class VIII fracture of maxillary lateral incisor - The sling shot method', *The Saudi dental journal*, 30(3), pp. 265–269.
12. Felicita, A. S., Chandrasekar, S. and Shanthasundari, K. K. (2012) 'Determination of craniofacial relation

- among the subethnic Indian population: a modified approach - (Sagittal relation)', *Indian journal of dental research: official publication of Indian Society for Dental Research*, 23(3), pp. 305–312.
13. Fuziy, A. et al. (2006) 'Sagittal, vertical, and transverse changes consequent to maxillary molar distalization with the pendulum appliance', *American Journal of Orthodontics and Dentofacial Orthopedics*, pp. 502–510. doi: 10.1016/j.ajodo.2004.12.031.
  14. Gheena, S. and Ezhilarasan, D. (2019) 'Syringic acid triggers reactive oxygen species-mediated cytotoxicity in HepG2 cells', *Human & experimental toxicology*, 38(6), pp. 694–702.
  15. Gomathi, A. C. et al. (2020) 'Anticancer activity of silver nanoparticles synthesized using aqueous fruit shell extract of *Tamarindus indica* on MCF-7 human breast cancer cell line', *Journal of Drug Delivery Science and Technology*, p. 101376. doi: 10.1016/j.jddst.2019.101376.
  16. Jain, R. K., Kumar, S. P. and Manjula, W. S. (2014) 'Comparison of intrusion effects on maxillary incisors among mini implant anchorage, j-hook headgear and utility arch', *Journal of clinical and diagnostic research: JCDR*, 8(7), pp. ZC21–4.
  17. Jeevanandan, G. and Govindaraju, L. (2018) 'Clinical comparison of Kedo-S paediatric rotary files vs manual instrumentation for root canal preparation in primary molars: a double blinded randomised clinical trial', *European Archives of Paediatric Dentistry*, pp. 273–278. doi: 10.1007/s40368-018-0356-6.
  18. J, P. C. et al. (2018) 'Prevalence and measurement of anterior loop of the mandibular canal using CBCT: A cross sectional study', *Clinical implant dentistry and related research*, 20(4), pp. 531–534.
  19. Kamisetty, S. K. et al. (2015) 'SBS vs Inhouse Recycling Methods-An Invitro Evaluation', *Journal of clinical and diagnostic research: JCDR*, 9(9), pp. ZC04–8.
  20. Krishnan, S., Pandian, S. and Kumar S, A. (2015) 'Effect of bisphosphonates on orthodontic tooth movement-an update', *Journal of clinical and diagnostic research: JCDR*, 9(4), pp. ZE01–5.
  21. Lee, K.-J. et al. (2007) 'Uprighting mandibular second molars with direct miniscrew anchorage', *Journal of clinical orthodontics: JCO*, 41(10), pp. 627–635.
  22. Malli Sureshbabu, N. et al. (2019) 'Concentrated Growth Factors as an Ingenious Biomaterial in Regeneration of Bony Defects after Periapical Surgery: A Report of Two Cases', *Case reports in dentistry*, 2019, p. 7046203.
  23. Mathew, M. G. et al. (2020) 'Evaluation of adhesion of *Streptococcus mutans*, plaque accumulation on zirconia and stainless steel crowns, and surrounding gingival inflammation in primary ...', *Clinical oral investigations*. Available at: <https://link.springer.com/article/10.1007/s00784-020-03204-9>.
  24. Mehta, M. et al. (2019) 'Oligonucleotide therapy: An emerging focus area for drug delivery in chronic inflammatory respiratory diseases', *Chemico-biological interactions*, 308, pp. 206–215.
  25. Menon, S. et al. (2018) 'Selenium nanoparticles: A potent chemotherapeutic agent and an elucidation of its mechanism', *Colloids and Surfaces B: Biointerfaces*, pp. 280–292. doi: 10.1016/j.colsurfb.2018.06.006.
  26. Muse, D. S. et al. (1993) 'Molar and incisor changes with Wilson rapid molar distalization', *American Journal of Orthodontics and Dentofacial Orthopedics*, pp. 556–565. doi: 10.1016/s0889-5406(05)80439-1.
  27. Panchal, V., Jeevanandan, G. and Subramanian, E. M. G. (2019) 'Comparison of post-operative pain after root canal instrumentation with hand K-files, H-files and rotary Kedo-S files in primary teeth: a randomised clinical trial', *European archives of paediatric dentistry: official journal of the European Academy of Paediatric Dentistry*, 20(5), pp. 467–472.
  28. Pandian, K. S., Krishnan, S. and Kumar, S. A. (2018) 'Angular photogrammetric analysis of the soft-tissue facial profile of Indian adults', *Indian journal of dental research: official publication of Indian Society for Dental Research*, 29(2), pp. 137–143.
  29. Park, Y.-C. et al. (2003) 'Intrusion of posterior teeth using mini-screw implants', *American journal of orthodontics and dentofacial orthopedics: official publication of the American Association of Orthodontists, its constituent societies, and the American Board of Orthodontics*, 123(6), pp. 690–694.
  30. Pc, J., Marimuthu, T. and Devadoss, P. (2018) 'Prevalence and measurement of anterior loop of the mandibular canal using CBCT: A cross sectional study', *Clinical implant dentistry and related research*. Available at: <https://europepmc.org/article/med/29624863>.
  31. Prabakar, J. et al. (2018) 'Comparative Evaluation of Retention, Cariostatic Effect and Discoloration of Conventional and Hydrophilic Sealants - A Single Blinded Randomized Split Mouth Clinical Trial', *Contemporary clinical dentistry*, 9(Suppl 2), pp. S233–S239.
  32. Rajendran, R. et al. (2019) 'Comparative Evaluation of Remineralizing Potential of a Paste Containing Bioactive Glass and a Topical Cream Containing Casein Phosphopeptide-Amorphous Calcium Phosphate: An in Vitro Study', *Pesquisa Brasileira em Odontopediatria e Clínica Integrada*, pp. 1–10. doi: 10.4034/pboci.2019.191.61.
  33. Rajeshkumar, S. et al. (2018) 'Biosynthesis of zinc oxide nanoparticles using *Mangifera indica* leaves and evaluation of their antioxidant and cytotoxic properties in lung cancer (A549) cells', *Enzyme and microbial technology*, 117, pp. 91–95.
  34. Rajeshkumar, S. et al. (2019) 'Antibacterial and antioxidant potential of biosynthesized copper

- nanoparticles mediated through *Cissus arnotiana* plant extract', *Journal of photochemistry and photobiology. B, Biology*, 197, p. 111531.
35. Ramadurai, N. et al. (2019) 'Effectiveness of 2% Articaine as an anesthetic agent in children: randomized controlled trial', *Clinical oral investigations*, 23(9), pp. 3543–3550.
  36. Ramakrishnan, M., Dhanalakshmi, R. and Subramanian, E. M. G. (2019) 'Survival rate of different fixed posterior space maintainers used in Paediatric Dentistry - A systematic review', *The Saudi dental journal*, 31(2), pp. 165–172.
  37. Ramesh, A. et al. (2018) 'Comparative estimation of sulfiredoxin levels between chronic periodontitis and healthy patients - A case-control study', *Journal of periodontology*, 89(10), pp. 1241–1248.
  38. Ramesh Kumar, K. R. et al. (2011) 'Depth of resin penetration into enamel with 3 types of enamel conditioning methods: a confocal microscopic study', *American journal of orthodontics and dentofacial orthopedics: official publication of the American Association of Orthodontists, its constituent societies, and the American Board of Orthodontics*, 140(4), pp. 479–485.
  39. Rubika, J., Sumathi Felicita, A. and Sivambiga, V. (2015) 'Gonial Angle as an Indicator for the Prediction of Growth Pattern', *World Journal of Dentistry*, pp. 161–163. doi: 10.5005/jp-journals-10015-1334.
  40. Samantha, C. et al. (2017) 'Comparative Evaluation of Two Bis-GMA Based Orthodontic Bonding Adhesives - A Randomized Clinical Trial', *Journal of clinical and diagnostic research: JCDR*, 11(4), pp. ZC40–ZC44.
  41. Samuel, S. R., Acharya, S. and Rao, J. C. (2020) 'School Interventions-based Prevention of Early-Childhood Caries among 3-5-year-old children from very low socioeconomic status: Two-year randomized trial', *Journal of public health dentistry*, 80(1), pp. 51–60.
  42. Sharma, P. et al. (2019) 'Emerging trends in the novel drug delivery approaches for the treatment of lung cancer', *Chemico-biological interactions*, 309, p. 108720.
  43. Sivamurthy, G. and Sundari, S. (2016) 'Stress distribution patterns at mini-implant site during retraction and intrusion--a three-dimensional finite element study', *Progress in orthodontics*, 17, p. 4.
  44. Sridharan, G. et al. (2019) 'Evaluation of salivary metabolomics in oral leukoplakia and oral squamous cell carcinoma', *Journal of oral pathology & medicine: official publication of the International Association of Oral Pathologists and the American Academy of Oral Pathology*, 48(4), pp. 299–306.
  45. Sugawara, J. et al. (2004) 'Distal movement of mandibular molars in adult patients with the skeletal anchorage system', *American Journal of Orthodontics and Dentofacial Orthopedics*, pp. 130–138. doi: 10.1016/j.ajodo.2003.02.003.
  46. Sugawara, J. et al. (2006) 'Distal movement of maxillary molars in nongrowing patients with the skeletal anchorage system', *American Journal of Orthodontics and Dentofacial Orthopedics*, pp. 723–733. doi: 10.1016/j.ajodo.2005.08.036.
  47. Varghese, S. S., Ramesh, A. and Veeraiyan, D. N. (2019) 'Blended Module-Based Teaching in Biostatistics and Research Methodology: A Retrospective Study with Postgraduate Dental Students', *Journal of dental education*, 83(4), pp. 445–450.
  48. Vijayashree Priyadharsini, J. (2019) 'In silico validation of the non-antibiotic drugs acetaminophen and ibuprofen as antibacterial agents against red complex pathogens', *Journal of periodontology*, 90(12), pp. 1441–1448.
  49. Vikram, N. R. et al. (2017) 'Ball Headed Mini Implant', *Journal of clinical and diagnostic research: JCDR*, 11(1), pp. ZL02–ZL03.
  50. Vishnu Prasad, S. et al. (2018) 'Report on oral health status and treatment needs of 5-15 years old children with sensory deficits in Chennai, India', *Special care in dentistry: official publication of the American Association of Hospital Dentists, the Academy of Dentistry for the Handicapped, and the American Society for Geriatric Dentistry*, 38(1), pp. 58–59.
  51. Viswanath, A. et al. (2015) 'Obstructive sleep apnea: awakening the hidden truth', *Nigerian journal of clinical practice*, 18(1), pp. 1–7.
  52. Wahab, P. U. A. et al. (2018) 'Scalpel Versus Diathermy in Wound Healing After Mucosal Incisions: A Split-Mouth Study', *Journal of oral and maxillofacial surgery: official journal of the American Association of Oral and Maxillofacial Surgeons*, 76(6), pp. 1160–1164.
  53. Yamada, K. et al. (2009) 'Distal Movement of Maxillary Molars Using Miniscrew Anchorage in the Buccal Interradicular Region', *The Angle Orthodontist*, pp. 78–84. doi: 10.2319/020408-68.1.