
A Knowledge Attitude and Practice Survey Regarding Pulp Therapy Among Dental Students

ABHISHEK NARAM¹, DR. MAHALAKSHMI J^{2*}, DR. DEEPAK S³

¹Saveetha dental college and hospitals, Saveetha Institute of Medical and Technical Sciences, Saveetha University, Chennai, Tamilnadu, India.

²Senior lecturer, Department of Conservative Dentistry and Endodontics Saveetha dental college and hospitals, Saveetha Institute of Medical and Technical Sciences, Saveetha University, Chennai, Tamilnadu, India.

³Senior lecturer, Department of Conservative Dentistry and Endodontics, Saveetha dental college and hospitals, Saveetha Institute of Medical and Technical Sciences, Saveetha University, Chennai, Tamilnadu, India.

*Corresponding author

Email Id: mahalakshmi.j.sdc@saveetha.com

Abstract: Dental pulp is an unmineralized oral tissue containing soft connective, vascular, lymphatic and nervous elements which occupies the central pulp chamber. It is the most vital part of the tooth. Vital pulp therapy is done to maintain the vitality and preserve the pulp tissue that is compromised and is indicated depending on the amount of exposure of the pulp and presence of infection. The different types of vital pulp therapy are indirect pulp capping, direct pulp capping and pulpotomy. Vital pulp therapy is also indicated for open apex to ensure proper root growth. The aim of our survey was to evaluate the knowledge attitude and practice regarding pulp therapy among dental students. A questionnaire consisting of 16 questions was distributed among dental students in saveetha dental college. Responses were collected through google forms. Data was collected and analysed using SPSS software. From the study it was concluded that there was a fair knowledge and practice regarding pulp therapy among dental students. Continuing education programs should be conducted to increase knowledge regarding pulp therapy.

Keywords: Apexification, apexogenesis, direct pulp capping, immature, mineral trioxide aggregate, pulpotomy

INTRODUCTION

The tooth is composed of three basic parts enamel, dentin and pulp. Out of which the dental pulp is one of the most unique and important. The pulp is usually under constant threat from varied factors like stimuli from the mouth cracks, fractures etc. that provide pathways for the micro organisms and their toxic products to enter (Yu and Abbott, 2007). Hence it's important to safeguard and preserve the vitality of the tooth. This can be achieved by restorative treatments, but within the case of deep caries and caries that has infected the pulp, alternative treatment options like vital pulp therapy which includes direct pulp capping, indirect pulp capping and pulpotomy are often done to save the vitality of the tooth instead of proceeding with invasive treatment options like root canal treatment. The main objective of pulp treatment is to maintain the integrity and health of the oral tissues, even though the tooth can remain non-functional, it is necessary to try in restoring the vitality of the pulp. (of Pediatric Dentistry and Others, 2008). Therefore, the aim of vital pulp therapy is to treat the reversible pulpal injury

The molecular and cellular changes that take place during tooth development and during tooth repair both show similarity indicating the method with which the various pulp treatment will work. In Dentinogenesis, the odontoblasts that are derived from the dental papilla secrete primary dentine during the post mitotic state, the cells of the pulp don't play any role in primary dentine formation. After a bulk of dentine has been formed, secondary dentine at a slower rate is deposited reducing the pulp chamber size. The post mitotic odontoblasts remain in a dormant state unless subjected to injury. (Linde and Goldberg, 1993) in the case of injury, the dentin and pulp complex secrete tertiary dentin increasing the space between the injury and the healthy cells (Fuks, 2002). The tertiary dentin formed can be of two types reactionary and reparative depending on the severity of the injury to the pulp. This forms the basis of vital pulp therapy. Indirect pulp capping is done in the case of deep carious lesions without any pulpal exposure. In this procedure, the deep carious dentin remains with a layer of calcium hydroxide to prevent additional trauma to the pulp and to initiate the tertiary dentin formation. Over the protective liner, temporary filling such as zinc oxide eugenol or glass ionomer cement (Farooq et al., 2000). The rationale of indirect pulp therapy is that the remaining bacteria present in the cavity will get sealed and become inactive. The only contraindication is that this treatment may lead to pulp exposure and trauma (Dumsha and Hovland, 1985). Direct pulp capping is done in the case of pulpal exposure during trauma or treatment. The exposure site is asymptomatic and is pin point in size. Calcium hydroxide liner is placed to

initiate dentin growth and heal the pulp, hence maintaining the vitality of the tooth (Levine, 1988). This treatment is ideal for young permanent teeth, failure could lead to internal resorption or dentoalveolar abscess. Pulpotomy is done when the radicular pulp is capable of healing once the infected coronal pulp is surgically removed (Fuks, 2002) It is contraindicated if the infection spreads towards the radicular pulp and in cases of fistula, pathological movement etc. The medicament used should be bactericidal and harmless to the surrounding structures. Studies have revealed 84% success rate. Previously our team had conducted numerous clinical trials and invitro studies (Ramamoorthi, Nivedhitha and Divyanand, 2015; Ramanathan and Solete, 2015; Noor and Others, 2016; Hussainy et al., 2018; Kumar and Antony, 2018; Mahalakshmi Nandakumar, 2018; Manohar and Sharma, 2018; Ravinthar and Others, 2018; Teja, Ramesh and Priya, 2018; Rajakeerthi and Ms, 2019; Rajendran et al., 2019a; Siddique et al., 2019; Teja and Ramesh, 2019; Janani, Palanivelu and Sandhya, 2020; Jose and Subbaiyan, 2020) over the past 5 years now we are focussing on surveys the idea of this survey stemmed from the current interest in our community. Our team has rich experience in research and we have collaborated with numerous authors over various topics in the past decade (Deogade, Gupta and Ariga, 2018; Ezhilarasan, 2018; Ezhilarasan, Sokal and Najimi, 2018; Jeevanandan and Govindaraju, 2018; J et al., 2018; Menon et al., 2018; Prabakar et al., 2018; Rajeshkumar et al., 2018, 2019; Vishnu Prasad et al., 2018; Wahab et al., 2018; Dua et al., 2019; Duraisamy et al., 2019; Ezhilarasan, Apoorva and Ashok Vardhan, 2019; Gheena and Ezhilarasan, 2019; Malli Sureshbabu et al., 2019; Mehta et al., 2019; Panchal, Jeevanandan and Subramanian, 2019; Rajendran et al., 2019b; Ramakrishnan, Dhanalakshmi and Subramanian, 2019; Sharma et al., 2019; Varghese, Ramesh and Veeraiyan, 2019; Gomathi et al., 2020; Samuel, Acharya and Rao, 2020) So the aim of our survey was to access the knowledge, awareness and practice of pulp therapy among dental students.

MATERIALS AND METHODS

This survey was conducted among dental students undergoing training in saveetha dental college and hospitals. Data were collected by means of a self-administered questionnaire consisting of 16 closed ended questions. The survey was prepared in the form of google forms and was sent to potential responders. 100 people have responded to the survey. The questionnaire consisted of questions regarding steps in pulp therapy materials used, indications etc. Convenient sampling method was used for data collection. The responses were presented as percentages. Results were tabulated and statistically analysed using SPSS software using a chi square test.

RESULTS & DISCUSSION

In the present study [fig1] 72% agreed with the fact that the closure of apex is completed approximately 2 to 3 years after tooth eruption, [fig2] 65% said that after traumatic injuries electric and thermal pulp tests may be reliable. [fig3] Only 37% of the study population selected the use of cbct provides more accurate information about root formation compared to conventional radiographs. [fig4] 40% of the participants said that the vital pulp therapy should only be performed in teeth with reversible pulpitis. [fig 5] 60% of the study population know that the main objective of vital pulp therapy is to initiate formation of tertiary reparative dentin or calcific bridge formation. [fig 6] 72% of the study population know the definition of apexogenesis in vital pulp therapy. [fig 7] 41% agreed with the fact that apexogenesis maintains pulp vitality thus allows continuous deposition of dentin. [fig8] 45% of the study population agreed with the fact that apexogenesis allows dentin bridge formation at the site of pulpotomy. [fig9] nearly two third of the population agreed with the fact that indirect pulp capping is a procedure performed in a tooth with a deep carious lesion approximating the pulp but without the signs of symptoms of pulp degeneration. [fig 10] 48% of the students agreed with the fact that In indirect pulp capping, the patient returns in 8–12 weeks for placement of a permanent coronal restoration. [fig11] 69% of the participants acknowledged the drawbacks of Ca(OH)₂. [fig12] majority of the students (67%) know the unique properties of the MTA. [fig 13] 56% of the study participants agreed with the fact that complete removal of the coronal pulp to the pulp floor is the preferred option if bleeding is not controlled within 10 minutes. [fig14] more than two third of the students (82%) said that successful outcomes of vital pulp therapy decreases with increase in patients age. [fig 15] 72% of the students agreed with the fact that caries detector dye can be a valuable tool in caries excavation. [fig16] majority of the students did not agree with the fact that If MTA is substituted for Ca (OH)₂ in vital pulp therapy procedures, similar time periods for apical maturation can be anticipated.

VPT is a biologic and conservative treatment modality to preserve the vitality and function of the coronal or remaining radicular pulp tissue in vital permanent teeth. (Akhlaghi and Khademi, 2015) Several studies have been conducted to meet this important aspect. However, the survey-based researches about (VPT) are rare. In 2018, Pishbin et al. designed a survey about (VPT), (Pishbin et al., 2018) but the content of this study was totally different from the questionnaires used in this study, so we have not found in literature any study similar to ours to compare with. High percentage of participants (74%) agreed that an open apex is present in the roots of immature teeth until apical closure occurs approximately 3 years after the eruption (Kleier and Barr, 1991; Capurro and Zmener, 1999) It was mentioned that immature teeth may require up to 5 years or more to gain

apical closure after emergence into the oral cavity (CAMP and JH, 2002) 71% of participants supported the information of Ohman (Ohman, 1965) and Andrease (Andreasen, 1986) that sensibility tests may be unreliable after traumatic injuries, which consider an important tip before starting any type of VPT. Due to drawbacks of conventional periapical radiographs the need to analyze the area of interest three-dimensionally led to the introduction of CBCT (Sethi et al., 2017) It has concluded that the use of CBCT technique provides more accurate information about the root formation compared to conventional radiographs (Hargreaves, 2016) In this study, there was good awareness about the importance of this technique to evaluate the case before VPT selection. About 40% of participants realize that the new technology, CBCT of much help in building an accurate diagnosis prior to VPT. It is well known that in case of irreversible pulpitis or pulpal necrosis, the suitable treatment is depending on the degree of root development. If root development is completely formed and the apex is closed, conventional root canal therapy can be performed. When root development is incomplete, root-end closure by apexification must be induced before root canal obturation. A recent trend of VPT proved that it is possible to perform VPT on mature teeth irreversibly inflamed (Taha and Khazali, 2017) As it is understood that there are a lot of scientific opinions depending on clinical treatments; so it is very important to know that the primary objective of VPT is to maintain pulp vitality to initiate reparative process such as tertiary dentin formation (Taha and Khazali, 2017) 71% of participants were familiar with apexogenesis which is a VPT procedure performed to encourage continued physiologic development and formation of the root end (Welbury and Walton, 1999; Cao et al., 2015) While 65% agreed that the objective of apexogenesis is to maintain the vitality of the radicular pulp only half of the participants knew that apexogenesis allows generating dentine bridge at the site of pulpotomy 75.2% of respondents showed a knowledge of the indication of indirect pulp capping, as it is a procedure performed in a tooth with a deep carious lesion approximating the pulp but without signs or symptoms of pulp degeneration (Hargreaves, 2016) in indirect pulp capping the patient returns in 8–12 weeks for the placement of a permanent coronal restoration (Jeuruphan et al., 2012) $\text{Ca}(\text{OH})_2$ has long been considered the universal standard for VPT materials. The introduction of $\text{Ca}(\text{OH})_2$ into dentistry is credited to Hermann in the 1920s. Desirable characteristics of $\text{Ca}(\text{OH})_2$ include an initial high alkaline pH which is responsible for stimulating fibroblasts and enzyme systems. The drawbacks of $\text{Ca}(\text{OH})_2$ include weak marginal adaptation to dentin, degradation, and dissolution over time (Hargreaves, 2016) More than 70% of internship dentists and clinical levels' dental students have background that the unique physiochemical properties of MTA promote a superior environment for pulpal repair and bridge formation compared to $\text{Ca}(\text{OH})_2$ products (Memarpour, Mesbahi and Shafei, 2010) Of all participants, 64% are aware of the statement "If bleeding cannot be controlled after 10 min of direct exposure to NaOCl after removal of unhealthy tissue, complete removal of the coronal pulp to the pulp floor is the preferred option" The low percentage of participants 35% realized an important side of NaOCl that it serves as an excellent diagnostic tool to differentiate irreversible from reversible pulpitis and to help determine whether to proceed with a partial pulpotomy, complete pulpotomy, or pulpectomy. (Mente et al., 2009) The outcomes for VPT can vary depending on the age of the patient, extent of bacterial contamination, and degree of pulp inflammation. Perhaps of greater importance may be the choice of pulp capping material and the quality of the permanent restoration (Cho et al., 2013) 26.2% of participants did not know that caries detector dyes can be considered a valuable tool in caries excavation when attempts are made to preserve remineralizable dentin and to minimize trauma to the pulp. (de Almeida Neves and Coutinho, 2011) Only 39% of participants agreed with this proved information if MTA is substituted for $\text{Ca}(\text{OH})_2$ in VPT. Procedures, similar time periods for apical maturation can be anticipated Our institution is passionate about high quality evidence based research and has excelled in various fields ((Pc, Marimuthu and Devadoss, 2018; Ramesh et al., 2018; Ezhilarasan, Apoorva and Ashok Vardhan, 2019; Ramadurai et al., 2019; Sridharan et al., 2019; Vijayashree Priyadharsini, 2019; Mathew et al., 2020)

CONCLUSION

From our survey, it can be concluded that most dental students have fair knowledge regarding pulp therapy. Pulp therapy is done to ensure and conserve the vitality of the tooth rather than doing invasive procedures such as Root canal treatment, as preservation of what remains is of utmost importance. In addition to the need of more lectures about the new materials used in endodontic field which is a very quick developed branch of dentistry, and it is very necessary to enhance the knowledge and practice of students about pulp therapy.

ACKNOWLEDGEMENT:

We, the authors of the manuscript, would like to thank and acknowledge Saveetha Dental College for providing us access to use the data for our study.

AUTHOR CONTRIBUTIONS:

All authors have equal contribution in bringing out this research work.

CONFLICT OF INTEREST:

This research project is self funded and it is not sponsored or aided by any third party. There is no conflict of interest.

REFERENCES:

1. Akhlaghi, N. and Khademi, A. (2015) 'Outcomes of vital pulp therapy in permanent teeth with different medicaments based on review of the literature', *Dental research journal*, 12(5), p. 406.
2. de Almeida Neves, A. and Coutinho, E. (2011) 'Current concepts and techniques for caries excavation and adhesion to residual dentin', *Journal of Adhesive*. doi: 10.3290/j.jad.a18443.
3. Andreasen, F. M. (1986) 'Transient apical breakdown and its relation to color and sensibility changes after luxation injuries to teeth', *Dental traumatology: official publication of International Association for Dental Traumatology*, 2(1), pp. 9–19.
4. CAMP and JH (2002) 'Pediatric endodontics, endodontic treatment for the primary and young permanent dentition', *Pathways of the pulp*, pp. 833–839.
5. Cao, Y. et al. (2015) 'Pulp-dentin Regeneration: Current State and Future Prospects', *Journal of dental research*, 94(11), pp. 1544–1551.
6. Capurro, M. and Zmener, O. (1999) 'Delayed apical healing after apexification treatment of non-vital immature tooth: a case report', *Dental traumatology: official publication of International Association for Dental Traumatology*, 15(5), pp. 244–246.
7. Cho, S.-Y. et al. (2013) 'Prognostic Factors for Clinical Outcomes According to Time after Direct Pulp Capping', *Journal of endodontics*, 39(3), pp. 327–331.
8. Deogade, S., Gupta, P. and Ariga, P. (2018) 'Effect of monopoly-coating agent on the surface roughness of a tissue conditioner subjected to cleansing and disinfection: A Contact Profilometric In vitro study', *Contemporary Clinical Dentistry*, p. 122. doi: 10.4103/ccd.ccd_112_18.
9. Dua, K. et al. (2019) 'The potential of siRNA based drug delivery in respiratory disorders: Recent advances and progress', *Drug development research*, 80(6), pp. 714–730.
10. Dumsha, T. and Hovland, E. (1985) 'Considerations and treatment of direct and indirect pulp-capping', *Dental clinics of North America*, 29(2), pp. 251–259.
11. Duraisamy, R. et al. (2019) 'Compatibility of Nonoriginal Abutments With Implants: Evaluation of Microgap at the Implant-Abutment Interface, With Original and Nonoriginal Abutments', *Implant dentistry*, 28(3), pp. 289–295.
12. Ezhilarasan, D. (2018) 'Oxidative stress is bane in chronic liver diseases: Clinical and experimental perspective', *Arab journal of gastroenterology: the official publication of the Pan-Arab Association of Gastroenterology*, 19(2), pp. 56–64.
13. Ezhilarasan, D., Apoorva, V. S. and Ashok Vardhan, N. (2019) 'Syzygium cumini extract induced reactive oxygen species-mediated apoptosis in human oral squamous carcinoma cells', *Journal of oral pathology & medicine: official publication of the International Association of Oral Pathologists and the American Academy of Oral Pathology*, 48(2), pp. 115–121.
14. Ezhilarasan, D., Sokal, E. and Najimi, M. (2018) 'Hepatic fibrosis: It is time to go with hepatic stellate cell-specific therapeutic targets', *Hepatobiliary & pancreatic diseases international: HBPD INT*, 17(3), pp. 192–197.
15. Farooq, N. S. et al. (2000) 'Success rates of formocresol pulpotomy and indirect pulp therapy in the treatment of deep dentinal caries in primary teeth', *Pediatric dentistry*, 22(4), pp. 278–286.
16. Fuks, A. B. (2002) 'Current concepts in vital primary pulp therapy', *European journal of paediatric dentistry: official journal of European Academy of Paediatric Dentistry*, 3, pp. 115–120.
17. Gheena, S. and Ezhilarasan, D. (2019) 'Syringic acid triggers reactive oxygen species-mediated cytotoxicity in HepG2 cells', *Human & experimental toxicology*, 38(6), pp. 694–702.
18. Gomathi, A. C. et al. (2020) 'Anticancer activity of silver nanoparticles synthesized using aqueous fruit shell extract of Tamarindus indica on MCF-7 human breast cancer cell line', *Journal of Drug Delivery Science and Technology*, p. 101376. doi: 10.1016/j.jddst.2019.101376.
19. Hargreaves, K. M. (2016) 'Cohen's Pathways of the Pulp. 10th', St. Louis, Mo, USA: Mosby.
20. Hussainy, S. N. et al. (2018) 'Clinical performance of resin-modified glass ionomer cement, flowable composite, and polyacid-modified resin composite in noncarious cervical lesions: One-year follow-up', *Journal of conservative dentistry: JCD*, 21(5), p. 510.
21. Janani, K., Palanivelu, A. and Sandhya, R. (2020) 'Diagnostic accuracy of dental pulse oximeter with customized sensor holder, thermal test and electric pulp test for the evaluation of pulp vitality: an in vivo study', *Brazilian Dental Science*, 23(1), p. 8.
22. Jeeruphan, T. et al. (2012) 'Mahidol Study 1: Comparison of Radiographic and Survival Outcomes of Immature Teeth Treated with Either Regenerative Endodontic or Apexification Methods: A Retrospective Study', *Journal of endodontics*, 38(10), pp. 1330–1336.

23. Jeevanandan, G. and Govindaraju, L. (2018) 'Clinical comparison of Kedo-S paediatric rotary files vs manual instrumentation for root canal preparation in primary molars: a double blinded randomised clinical trial', *European Archives of Paediatric Dentistry*, pp. 273–278. doi: 10.1007/s40368-018-0356-6.
24. Jose, J. and Subbaiyan, H. (2020) 'Different Treatment Modalities followed by Dental Practitioners for Ellis Class 2 Fracture—A Questionnaire-based Survey', *The open dentistry journal*. Available at: <https://opendentistryjournal.com/VOLUME/14/PAGE/59/FULLTEXT/>.
25. J, P. C. et al. (2018) 'Prevalence and measurement of anterior loop of the mandibular canal using CBCT: A cross sectional study', *Clinical implant dentistry and related research*, 20(4), pp. 531–534.
26. Kleier, D. J. and Barr, E. S. (1991) 'A study of endodontically apexified teeth', *Dental traumatology: official publication of International Association for Dental Traumatology*, 7(3), pp. 112–117.
27. Kumar, D. and Antony, S. (2018) 'Calcified Canal and Negotiation-A Review', *Research Journal of Pharmacy and Technology*, 11(8), pp. 3727–3730.
28. Levine, N. (1988) 'Pulpal therapy in primary and young permanent teeth', *Pediatric dentistry: total patient care*. Available at: <https://ci.nii.ac.jp/naid/10014767975/>.
29. Linde, A. and Goldberg, M. (1993) 'Dentinogenesis', *Critical reviews in oral biology and medicine: an official publication of the American Association of Oral Biologists*, 4(5), pp. 679–728.
30. Mahalakshmi Nandakumar, I. N. (2018) 'Comparative evaluation of grape seed and cranberry extracts in preventing enamel erosion: An optical emission spectrometric analysis', *Journal of conservative dentistry: JCD*, 21(5), p. 516.
31. Malli Sureshbabu, N. et al. (2019) 'Concentrated Growth Factors as an Ingenious Biomaterial in Regeneration of Bony Defects after Periapical Surgery: A Report of Two Cases', *Case reports in dentistry*, 2019, p. 7046203.
32. Manohar, M. P. and Sharma, S. (2018) 'A survey of the knowledge, attitude, and awareness about the principal choice of intracanal medicaments among the general dental practitioners and nonendodontic specialists', *Indian journal of dental research: official publication of Indian Society for Dental Research*, 29(6), p. 716.
33. Mathew, M. G. et al. (2020) 'Evaluation of adhesion of *Streptococcus mutans*, plaque accumulation on zirconia and stainless steel crowns, and surrounding gingival inflammation in primary ...', *Clinical oral investigations*. Available at: <https://link.springer.com/article/10.1007/s00784-020-03204-9>.
34. Mehta, M. et al. (2019) 'Oligonucleotide therapy: An emerging focus area for drug delivery in chronic inflammatory respiratory diseases', *Chemico-biological interactions*, 308, pp. 206–215.
35. Memarpour, M., Mesbahi, M. and Shafei, F. (2010) 'Three-and-a-half-year Clinical Evaluation of Posterior Composite Resin in Children', *Journal of dentistry for children*, 77(2), pp. 92–98.
36. Menon, S. et al. (2018) 'Selenium nanoparticles: A potent chemotherapeutic agent and an elucidation of its mechanism', *Colloids and Surfaces B: Biointerfaces*, pp. 280–292. doi: 10.1016/j.colsurfb.2018.06.006.
37. Mente, J. et al. (2009) 'Mineral Trioxide Aggregate Apical Plugs in Teeth with Open Apical Foramina: A Retrospective Analysis of Treatment Outcome', *Journal of endodontics*, 35(10), pp. 1354–1358.
38. Noor, S. and Others (2016) 'Chlorhexidine: Its properties and effects', *Research Journal of Pharmacy and Technology*, 9(10), pp. 1755–1760.
39. Ohman, A. (1965) 'HEALING AND SENSITIVITY TO PAIN IN YOUNG REPLANTED HUMAN TEETH. AN EXPERIMENTAL, CLINICAL AND HISTOLOGICAL STUDY', *Odontologisk tidskrift*, 73, p. 166.
40. Panchal, V., Jeevanandan, G. and Subramanian, E. M. G. (2019) 'Comparison of post-operative pain after root canal instrumentation with hand K-files, H-files and rotary Kedo-S files in primary teeth: a randomised clinical trial', *European archives of paediatric dentistry: official journal of the European Academy of Paediatric Dentistry*, 20(5), pp. 467–472.
41. Pc, J., Marimuthu, T. and Devadoss, P. (2018) 'Prevalence and measurement of anterior loop of the mandibular canal using CBCT: A cross sectional study', *Clinical implant dentistry and related research*. Available at: <https://europepmc.org/article/med/29624863>.
42. of Pediatric Dentistry, A. A. and Others (2008) *American Academy of Pediatric Dentistry reference manual*. American Academy of Pediatric Dentistry.
43. Pishbin, L. et al. (2018) [No title]. *researchgate.net*. Available at: https://www.researchgate.net/profile/Fatemeh_Sajadi4/publication/324583619_Knowledge_and_practice_of_vital_pulp_therapy_in_young_permanent_teeth_among_general_dental_practitioners_in_Kerman_Iran/links/5ae4396fa6fdcc3bea944efc/Knowledge-and-practice-of-vital-pulp-therapy-in-young-permanent-teeth-among-general-dental-practitioners-in-Kerman-Iran.pdf (Accessed: 12 June 2020).
44. Prabakar, J. et al. (2018) 'Comparative Evaluation of Retention, Cariostatic Effect and Discoloration of Conventional and Hydrophilic Sealants - A Single Blinded Randomized Split Mouth Clinical Trial', *Contemporary clinical dentistry*, 9(Suppl 2), pp. S233–S239.
45. Rajakeerthi, R. and Ms, N. (2019) 'Natural Product as the Storage medium for an avulsed tooth--A

- Systematic Review', *Cumhuriyet Dental Journal*, 22(2), pp. 249–256.
46. Rajendran, R. et al. (2019a) 'Comparative Evaluation of Remineralizing Potential of a Paste Containing Bioactive Glass and a Topical Cream Containing Casein Phosphopeptide-Amorphous Calcium Phosphate: An in Vitro Study', *Pesquisa brasileira em odontopediatria e clinica integrada*, 19. Available at: http://www.scielo.br/scielo.php?pid=S1983-46322019000100364&script=sci_arttext.
 47. Rajendran, R. et al. (2019b) 'Comparative Evaluation of Remineralizing Potential of a Paste Containing Bioactive Glass and a Topical Cream Containing Casein Phosphopeptide-Amorphous Calcium Phosphate: An in Vitro Study', *Pesquisa Brasileira em Odontopediatria e Clínica Integrada*, pp. 1–10. doi: 10.4034/pboci.2019.191.61.
 48. Rajeshkumar, S. et al. (2018) 'Biosynthesis of zinc oxide nanoparticles using *Mangifera indica* leaves and evaluation of their antioxidant and cytotoxic properties in lung cancer (A549) cells', *Enzyme and microbial technology*, 117, pp. 91–95.
 49. Rajeshkumar, S. et al. (2019) 'Antibacterial and antioxidant potential of biosynthesized copper nanoparticles mediated through *Cissus arnotiana* plant extract', *Journal of photochemistry and photobiology. B, Biology*, 197, p. 111531.
 50. Ramadurai, N. et al. (2019) 'Effectiveness of 2% Articaine as an anesthetic agent in children: randomized controlled trial', *Clinical oral investigations*, 23(9), pp. 3543–3550.
 51. Ramakrishnan, M., Dhanalakshmi, R. and Subramanian, E. M. G. (2019) 'Survival rate of different fixed posterior space maintainers used in Paediatric Dentistry - A systematic review', *The Saudi dental journal*, 31(2), pp. 165–172.
 52. Ramamoorthi, S., Nivedhitha, M. S. and Divyanand, M. J. (2015) 'Comparative evaluation of postoperative pain after using endodontic needle and EndoActivator during root canal irrigation: a randomised controlled trial', *Australian endodontic journal: the journal of the Australian Society of Endodontology Inc*, 41(2), pp. 78–87.
 53. Ramanathan, S. and Solete, P. (2015) 'Cone-beam Computed Tomography Evaluation of Root Canal Preparation using Various Rotary Instruments: An in vitro Study', *The journal of contemporary dental practice*, 16(11), pp. 869–872.
 54. Ramesh, A. et al. (2018) 'Comparative estimation of sulfiredoxin levels between chronic periodontitis and healthy patients - A case-control study', *Journal of periodontology*, 89(10), pp. 1241–1248.
 55. Ravinthar, K. and Others (2018) 'Recent Advancements in Laminates and Veneers in Dentistry', *Research Journal of Pharmacy and Technology*, 11(2), pp. 785–787.
 56. Samuel, S. R., Acharya, S. and Rao, J. C. (2020) 'School Interventions-based Prevention of Early-Childhood Caries among 3-5-year-old children from very low socioeconomic status: Two-year randomized trial', *Journal of public health dentistry*, 80(1), pp. 51–60.
 57. Sethi, P. et al. (2017) 'Endodontic practice management with cone-beam computed tomography', *Saudi Endodontic*. Available at: <http://www.saudiendodj.com/article.asp?issn=1658-5984;year=2017;volume=7;issue=1;spage=1;epage=7;aulast=Sethi>.
 58. Sharma, P. et al. (2019) 'Emerging trends in the novel drug delivery approaches for the treatment of lung cancer', *Chemico-biological interactions*, 309, p. 108720.
 59. Siddique, R. et al. (2019) 'Qualitative and quantitative analysis of precipitate formation following interaction of chlorhexidine with sodium hypochlorite, neem, and tulsi', *Journal of conservative dentistry: JCD*, 22(1), p. 40.
 60. Sridharan, G. et al. (2019) 'Evaluation of salivary metabolomics in oral leukoplakia and oral squamous cell carcinoma', *Journal of oral pathology & medicine: official publication of the International Association of Oral Pathologists and the American Academy of Oral Pathology*, 48(4), pp. 299–306.
 61. Taha, N. A. and Khazali, M. A. (2017) 'Partial Pulpotomy in Mature Permanent Teeth with Clinical Signs Indicative of Irreversible Pulpitis: A Randomized Clinical Trial', *Journal of endodontics*, 43(9), pp. 1417–1421.
 62. Teja, K. V. and Ramesh, S. (2019) 'Shape optimal and clean more', *Saudi Endodontic Journal*, 9(3), p. 235.
 63. Teja, K. V., Ramesh, S. and Priya, V. (2018) 'Regulation of matrix metalloproteinase-3 gene expression in inflammation: A molecular study', *Journal of conservative dentistry: JCD*, 21(6), p. 592.
 64. Varghese, S. S., Ramesh, A. and Veeraiyan, D. N. (2019) 'Blended Module-Based Teaching in Biostatistics and Research Methodology: A Retrospective Study with Postgraduate Dental Students', *Journal of dental education*, 83(4), pp. 445–450.
 65. Vijayashree Priyadharsini, J. (2019) 'In silico validation of the non-antibiotic drugs acetaminophen and ibuprofen as antibacterial agents against red complex pathogens', *Journal of periodontology*, 90(12), pp. 1441–1448.
 66. Vishnu Prasad, S. et al. (2018) 'Report on oral health status and treatment needs of 5-15 years old children with sensory deficits in Chennai, India', *Special care in dentistry: official publication of the American Association of Hospital Dentists, the Academy of Dentistry for the Handicapped, and the American Society*

for Geriatric Dentistry, 38(1), pp. 58–59.

67. Wahab, P. U. A. et al. (2018) ‘Scalpel Versus Diathermy in Wound Healing After Mucosal Incisions: A Split-Mouth Study’, *Journal of oral and maxillofacial surgery: official journal of the American Association of Oral and Maxillofacial Surgeons*, 76(6), pp. 1160–1164.
68. Welbury, R. and Walton, A. G. (1999) ‘Continued apexogenesis of immature permanent incisors following trauma’, *British dental journal*, 187(12), pp. 643–644.
69. Yu, C. and Abbott, P. V. (2007) ‘An overview of the dental pulp: its functions and responses to injury’, *Australian dental journal*, 52, pp. S4–S6.

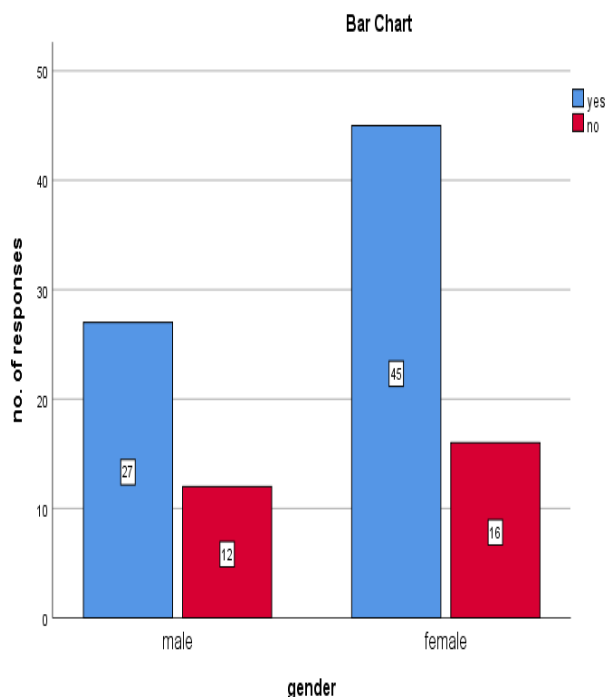


Fig.1: Bar graph represents the association between the gender and number of responses. X axis represents gender and Y axis represents number of responses. When asked “closure of root apex is completed 2 to 3 years after the eruption of the teeth” 72 have responded yes and 28 have responded no. Pearson chi square test was done and it gave a p value of 0.622 which is >0.05 hence the results were not statistically significant. Proving Females have better awareness than males.

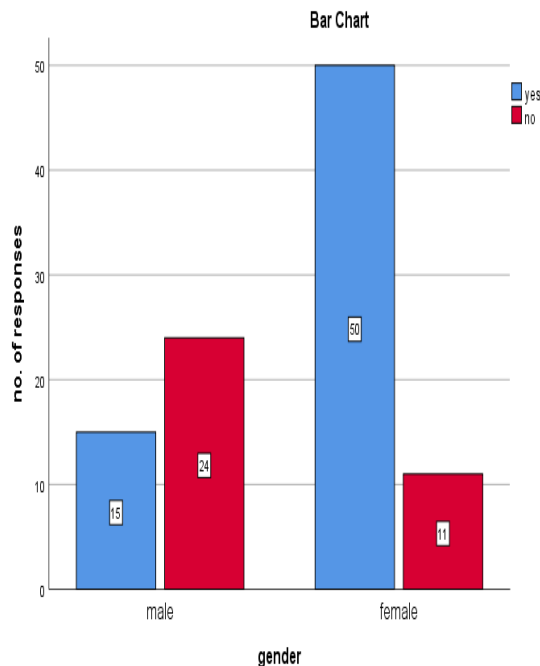


Fig.2: Bar graph represents the association between gender and number of responses. X axis represents gender and Y axis represents number of responses. When asked “after traumatic injury electric and thermal pulp test is unreliable” 65 have responded yes and 35 have responded no. Pearson chi square test was done and it gave a p value was 0.025 which is <0.05 hence the results were statistically significant proving males have better awareness than females.

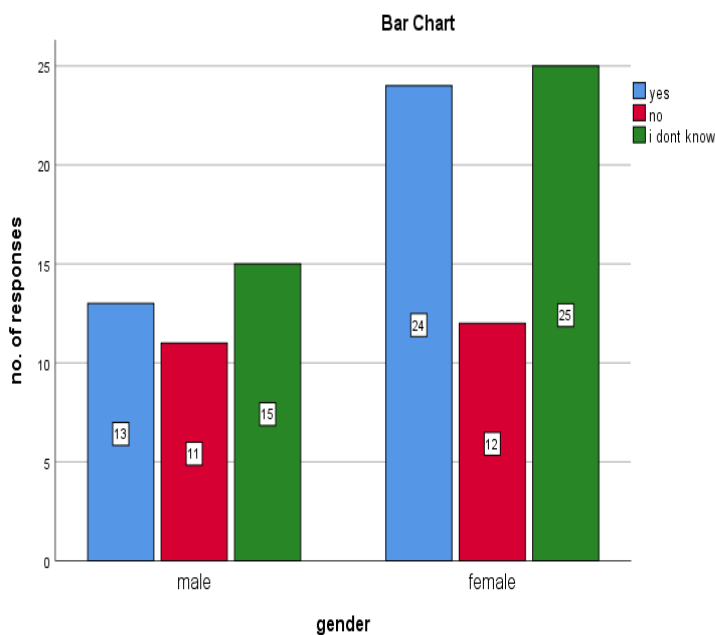


Fig.3: Bar graph represents the association between gender and number of responses. X axis represents gender and Y axis represents number of responses. When asked “the use of cbct provides more accurate information about root formation compared to conventional radiographs” 37 have responded yes and 23 have responded no and 40 have responded i dont know. Pearson chi square test was done and it gave a p value of 0.600 which is >0.05 hence the results were not statistically significant.

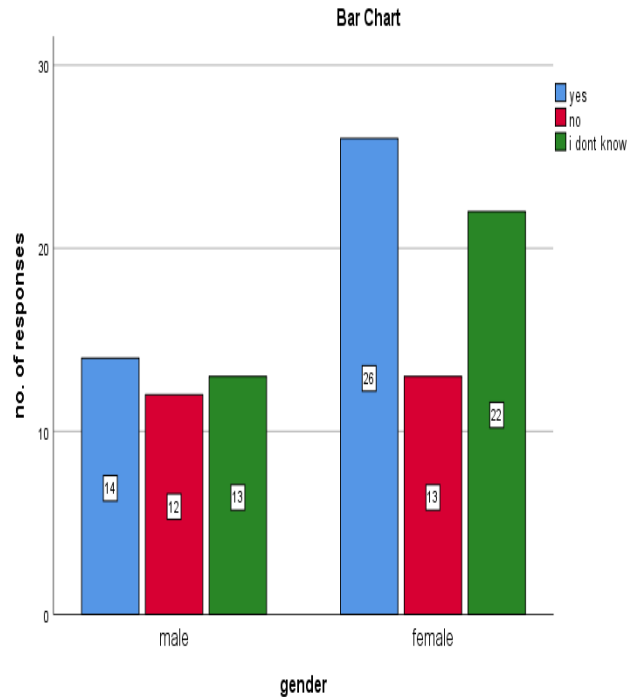


Fig.4: Bar graph represents the association between gender and number of responses. X axis represents gender and Y axis represents number of responses. When asked “vital pulp therapy should only be performed in teeth with reversible pulpitis” 40 have responded yes and 25 have responded no and 35 have responded i dont know. Pearson chi square test was done and it gave a p value of 0.557 which is >0.05 hence the results were not statistically significant.

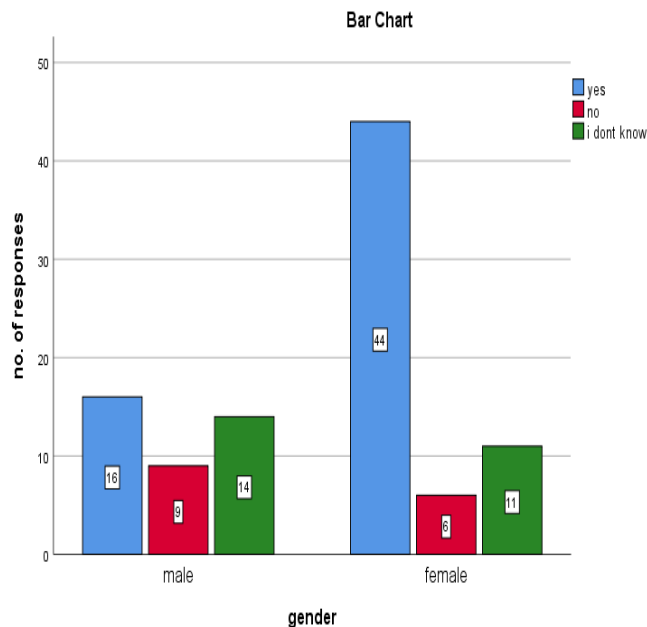


Fig.5: Bar graph represents the association between gender and number of responses. X axis represents gender and Y axis represents number of responses. When asked “The main objective in vital pulp therapy is to initiate the formation of tertiary reparative dentin or calcific bridge formation” 60 have responded yes and 15 have responded no and 25 have responded i dont know. Pearson chi square test was done and it gave a p value of 0.008 which is <0.05 hence the results are statistically significant. Proving that males have better awareness than females.

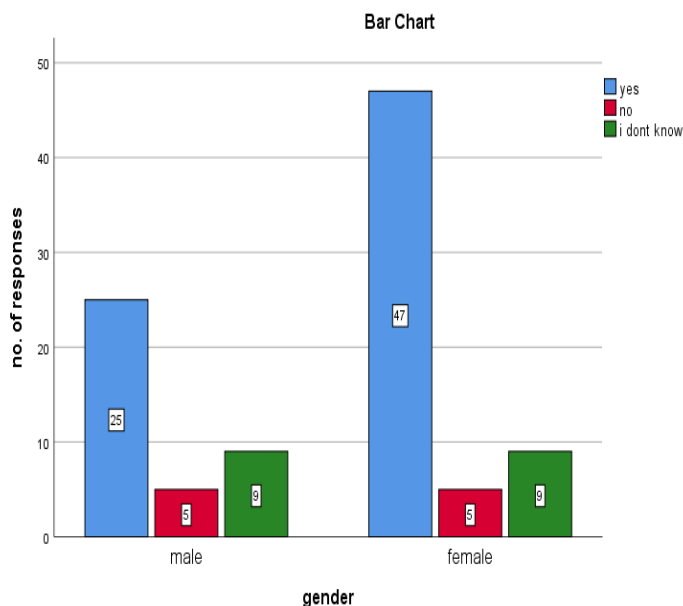


Fig.6: Bar graph represents the association between gender and number of responses. X axis represents gender and Y axis represents number of responses. When asked “Apexogenesis is a vital pulp therapy procedure to encourage the physiological development and formation of the root end” 72 have responded yes and 10 have responded no and 18 have responded i dont know. Pearson chi square test was done and it gave a p value of 0.372 which is >0.05 hence the results are not statistically significant.

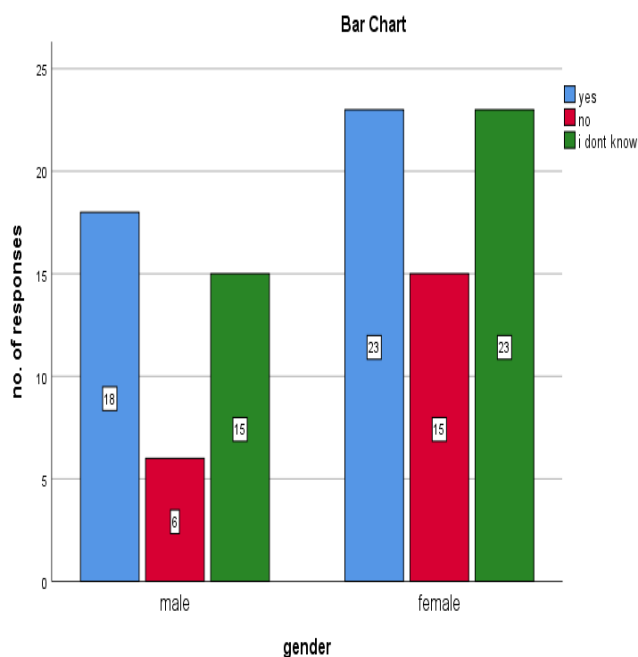


Fig.7: Bar graph represents the association between the gender and number of responses. X axis represents gender and Y axis represents number of responses. When asked “Apexogenesis maintains pulp vitality, thus allows continued deposition of dentin” 41 have responded yes and 21 have responded no and 38 have responded i dont know. Pearson chi square test was done and it gave a p value of 0.502 which is >0.05 hence the results are not statistically significant.

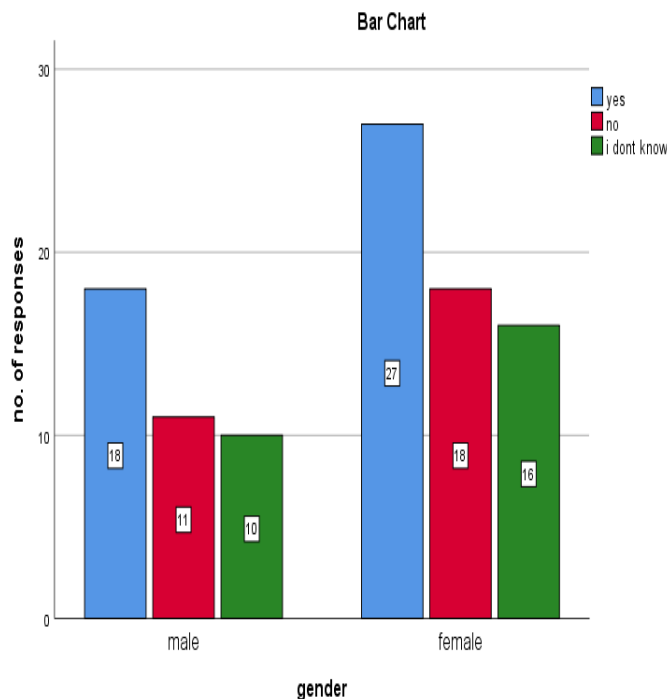


Fig.8: Bar graph represents the association between gender and number of responses. X axis represents gender and Y axis represents number of responses. When asked “Apexogenesis allows generating dentine bridge at the site of pulpotomy” 45 have responded yes and 30 have responded no and 25 have responded i dont know. Pearson chi square test was done and it gave a p value of 0.982 which is >0.05 hence the results are not statistically significant.

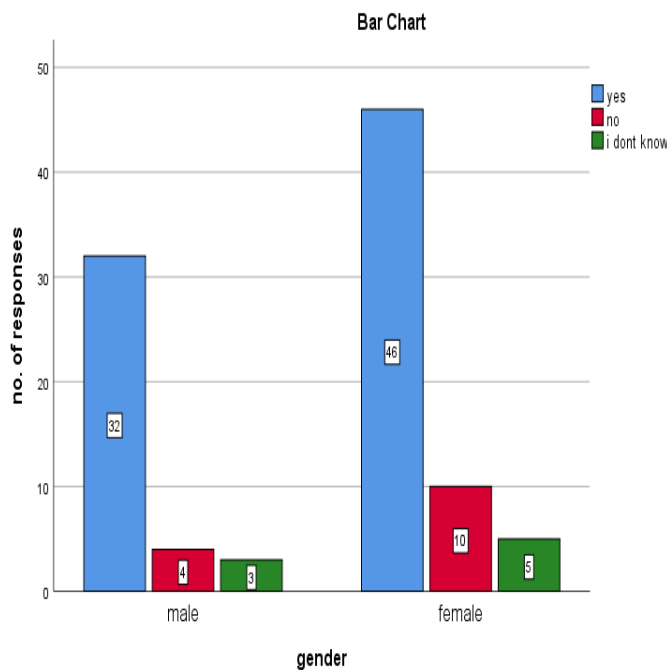


Fig.9: Bar graph represents the association between gender and number of responses. X axis represents gender and Y axis represents number of responses. When asked “Indirect pulp capping is a procedure performed in a tooth with a deep carious lesion approximating the pulp but without signs or symptoms of pulp degeneration” 78 have responded yes and 14 have responded no and 8 have responded i dont know. Pearson chi square test was done and it gave a p value of 0.676 which is >0.05 hence the results are not statistically significant.

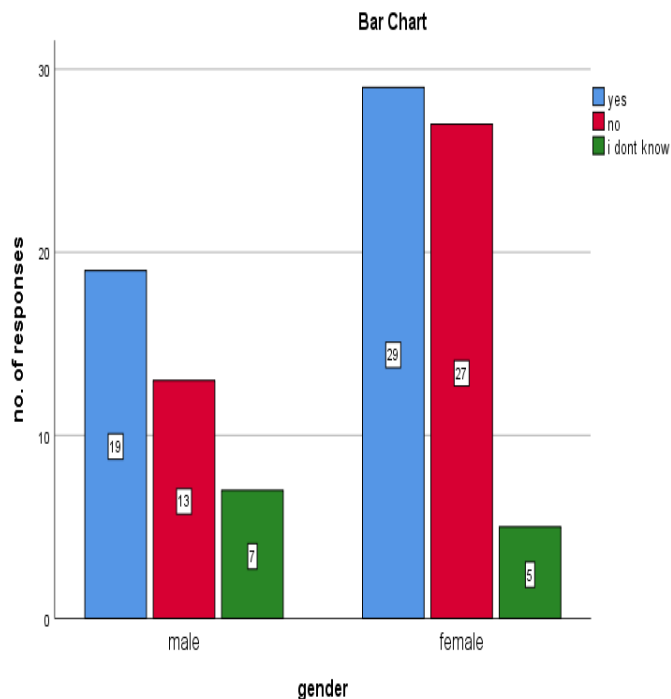


Fig.10: Bar graph represents the association between gender and number of responses. X axis represents gender and Y axis represents number of responses. When asked “In indirect pulp capping, the patient returns in 8–12 weeks for placement of a permanent coronal restoration ” 48 have responded yes and 40 have responded no and 12 have responded i dont know. Pearson chi square test was done and it gave a p value of 0.272 which is >0.05 hence the results are not statistically significant.

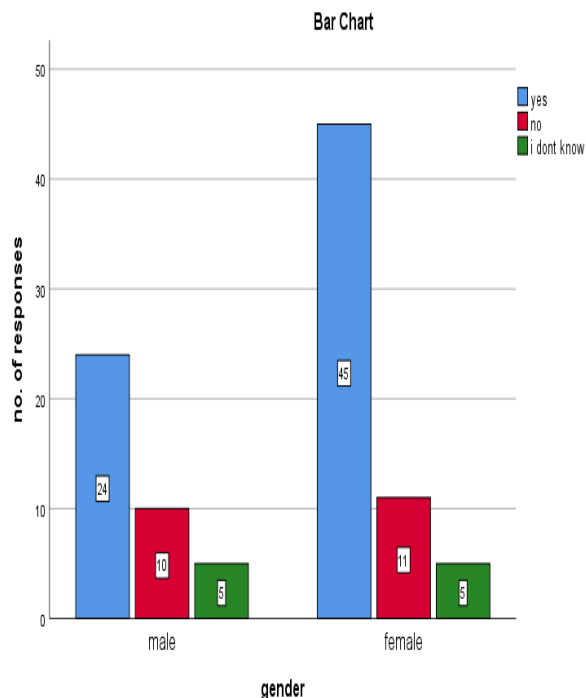


Fig.11: Bar graph represents the association between the gender and number of responses. X axis represents gender and Y axis represents number of responses.. When asked “The drawbacks of Ca (OH)2 include weak marginal adaptation to dentin, and dissolution over time” 69 have responded yes and 22 have responded no and 9 have responded i dont know. Pearson chi square test was done and it gave a p value of 0.432 which is >0.05 hence the results are not statistically significant.

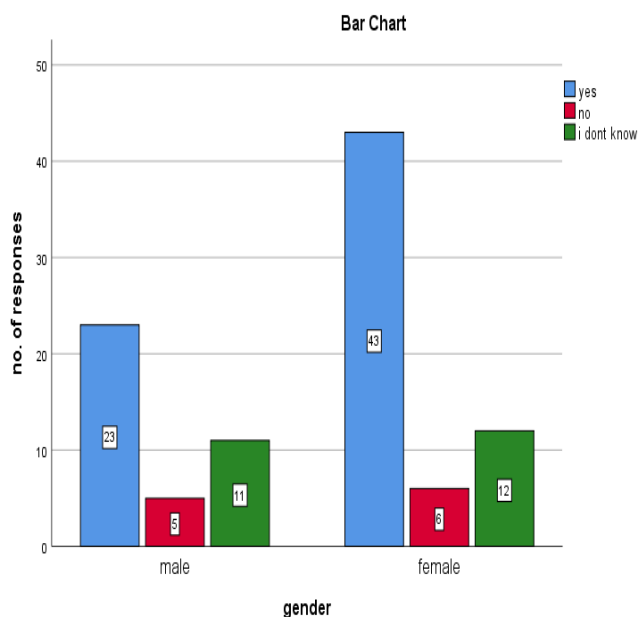


Fig.12: Bar graph represents the association between the gender and number of responses. X axis represents gender and Y axis represents number of responses. When asked “The unique physicochemical properties of MTA promote a superior environment for pulpal repair and bridge formation, compared to Ca (OH)₂ products” 67 have responded yes and 10 have responded no and 23 have responded i dont know. Pearson chi square test was done and it gave a p value of 0.491 which is >0.05 hence the results are not statistically significant.

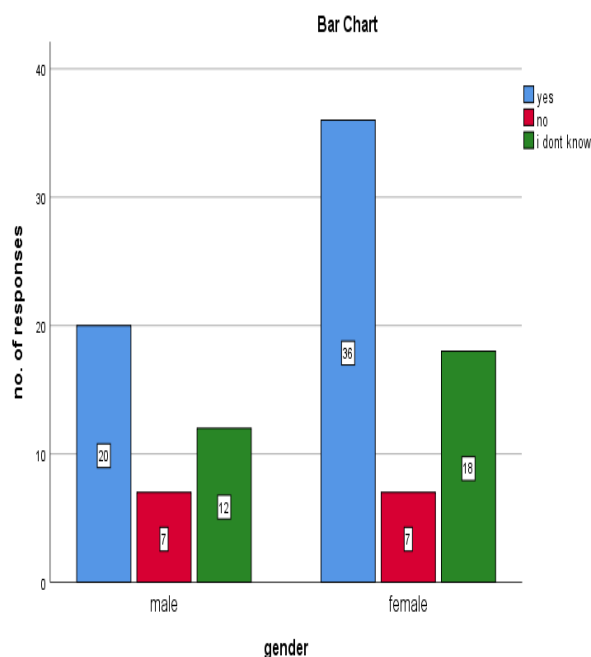


Fig.13: Bar graph represents the association between the gender and number of responses. X axis represents gender and Y axis represents number of responses.. When asked “In partial pulpotomy: If bleeding cannot be controlled after 10 min of direct exposure to NaOCl after removal of unhealthy tissue, complete removal of the coronal pulp to the pulp floor is the preferred option” 56 have responded yes and 14 have responded no and 30 have responded i dont know. Pearson chi square test was done and it gave a p value of 0.613 which is >0.05 hence the results are not statistically significant.

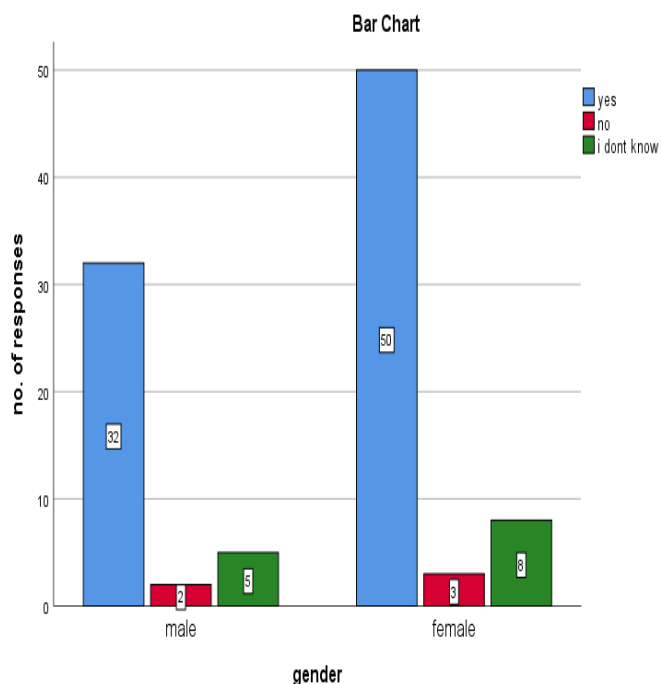


Fig.14: Bar graph represents the association between the gender and number of responses. X axis represents gender and Y axis represents number of responses.. When asked “Successful outcomes for vital pulp therapy decrease as the patient’s age increases”, 82 have responded yes and 5 have responded no and 13 have responded i dont know. pearson chi square test was done and it gave a p value of 0.998 which is >0.05 hence the results are not statistically significant.

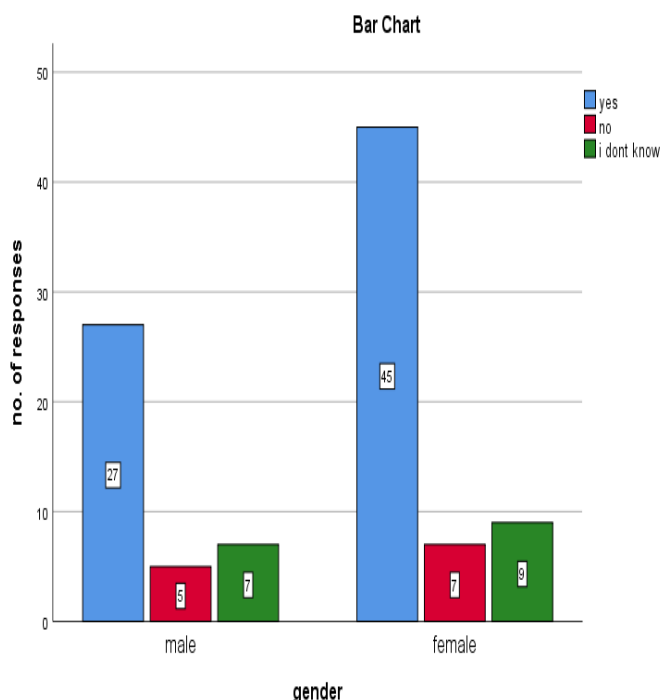


Fig.15: Bar graph represents the association between the gender and number of responses. X axis represents gender and Y axis represents number of responses. When asked “Caries detector dyes can be considered a valuable tool in caries excavation when attempts are made to preserve remineralized dentin and to minimize trauma to the pulp”, 72 have responded yes and 12 have responded no and 16 have responded i don't know. Pearson chi square test was done and it gave a p value of 0.880 which is >0.05 hence the results are not statistically significant.

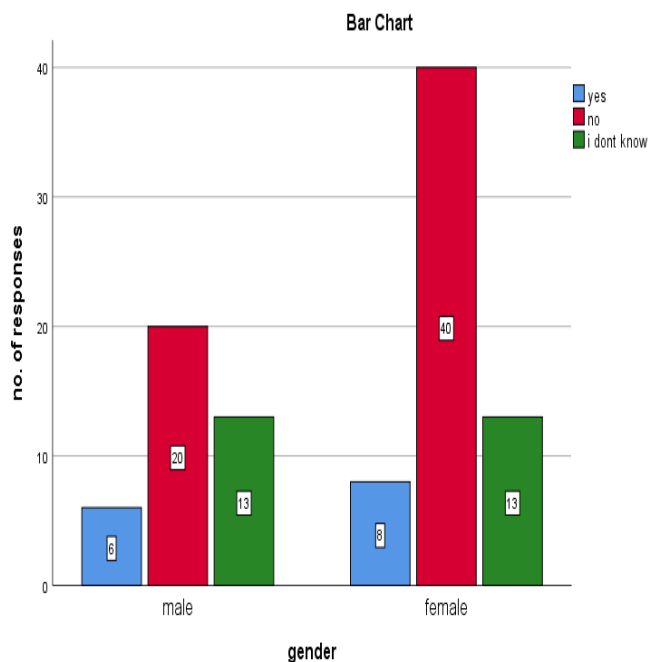


Fig.16: Bar graph represents the association between the gender and number of responses. X axis represents gender and Y axis represents number of responses.. When asked “Caries detector dyes can be considered a valuable tool in caries excavation when attempts are made to preserve remineralized dentin and to minimize trauma to the pulp”. 14 have responded yes and 60 have responded no and 26 have responded i dont know. Pearson chi square test was done and it gave a p value of 0.330 which is >0.05 hence the results are not statistically significant.