
Prevalence and gender association of radix entomolaris in mandibular molars

MOHAMAD QULAM ZAKI BIN MOHAMAD RASIDI¹, DEEPAK.S^{2*}, DINESH PRABU³

¹Saveetha Dental College and Hospitals, Saveetha Institute of Medical and Technical Sciences, Chennai, Tamil Nadu, India.

²Senior Lecturer, Department of Conservative Dentistry and Endodontics, Saveetha Dental College and Hospitals, Saveetha Institute of Medical and Technical Sciences, Chennai, Tamil Nadu, India.

³Senior Lecturer, Department of Oral and Maxillofacial Surgery, Saveetha Dental College and Hospitals, Saveetha Institute of Medical and Technical Sciences, Chennai, Tamil Nadu, India.

*Corresponding Author

Email ID: 151501099.sdc@saveetha.com¹, deepaks.sdc@saveetha.com, dineshprabum.sdc@saveetha.com

Abstract: Endodontic treatment with excellent outcomes depends on the critical identification of the root and its canals anatomy. The successful identification of these anatomies guaranteed the pulp tissue extirpation completely, with efficiency in chemo-mechanical cleaning and shaping. All these lead to three-dimensional root canal obturation with the most reliable inert filling. Therefore, the aim of this study was to evaluate the occurrence of radix entomolaris in mandibular molars between male and female patients. A total of 1503 patient records were reviewed and analyzed from June 2019 to March 2020 in Saveetha Dental College. All 1503 patients were assessed for the radix entomolaris, data entered in Microsoft excel sheet, and transferred to SPSS software for statistical results. The Chi-Square test was done to analyze the correlation between the gender prevalence of radix entomolaris in mandibular first molars. The prevalence of patients with Radix Entomolaris was 0.5% (7 of 1503), 0.47% (4 of 843) for females, and 0.45% (3 of 660) for males, which showed statistically insignificant (p-value >0.05). Within the limitations of the study, there is no significant evidence suggesting that gender plays a major role in the occurrence of Radix Entomolaris.

Keywords: Gender; Radix Entomolaris; Root canal anatomy; Root canal treatment.

INTRODUCTION

The excellent root canal treatment with a high success rate depends on the complete elimination of microorganisms and their products. It is a rare case for mandibular molars to have one additional root. The additional root is located on the distolingual surface of mandibular first molars. This rare anatomical structure is called Radix Entomolaris (RE). (Chandra *et al.*, 2011)

However, if the additional root is located mesiolingual, it is called as Radix Paramolaris. (Garg *et al.*, 2010) Both radix entomolaris and radix paramolaris can be suggested with normal radiographic imaging in a routine examination. (Cohen and Burns, 2002)

The mandibular first molars normally have two roots, which are one mesial root and one distal root. In the mesial root of the mandibular molar, have two canals; mesiobuccal canal and mesiolingual canal. These canals may end in two distinct apical foramina. However, there are occurrences of canals emerge together and form only one foramen. In the distal root, it may have one canal, although rarely it has two canals.

The previous studies depicted that there is an association between the presence of radix entomolaris and various ethnic groups, regard to their gender. (Calberson, De Moor and Deroose, 2007) For example, in the Mongoloid traits population (Eskimos, Chinese, and American-Indians), the occurrence of the radix entomolaris is between 5% and 30% which is more frequent. Meanwhile, in the European population, the occurrence of radix entomolaris is less. (Souza-Flamini *et al.*, 2014)

The endodontic treatment with excellent outcomes depends on the critical identification of the root and its canals anatomy. The successful identification of these anatomies guaranteed the pulp tissue extirpation completely, with efficiency in chemo-mechanical cleaning and shaping. (Bahammam and Bahammam, 2012; Rajendran *et al.*, 2019a) All these lead to the most proper three-dimensionally root canal obturation with the most reliable inert filling.

The radiographic imaging for identification purposes in additional roots in mandibular molars is an important step as it identifies all root canals which are to be instrumented during the cleaning and shaping procedure of

endodontic treatment. The identification of extra root canals is essential as overlooked canals may lead to endodontic treatment failure due to the canal walls not undergoing proper chemomechanical preparation. The use of cone-beam volumetric tomography is highly recommended and more informative when the anomalies of root morphology are identified during routine periapical radiographic imaging. In these methods, the tube needs to be a shift with additional views taken from the medial or distal angle at 20 to 30 degrees. This technique is also known as the Parallax technique and it can help in delineate the root morphology according to the Buccal Object Rule.(Wang *et al.*, 2011)

In the supernumerary roots of mandibular molars teeth, Radix Entomolaris or Radix Paramolaris may range from a short conical to a normal length. According to De Moor classification scheme, there are three main patterns for supernumerary roots curvatures which are Type I (straight root), Type II (curved in the coronal third and then straight continuing to the apex), and Type III (curved in the coronal third, with mesiobuccal curvature from the middle third to the apical third of the root.(Calberson, De Moor and Deroose, 2007)

The endodontic treatment with missing one or more of these criteria mentioned may lead to an increased risk of unsuccessful root canal treatment. The failure symptoms may appear like the subsequent development of periapical lesion persistence afterward.(Walker and Quackenbush, 1985; Shemesh *et al.*, 2015),(Colak, Ozcan and Hamidi, 2012)

Previously our team had conducted numerous clinical trials (Ramamoorthi, Nivedhitha and Divyanand, 2015; Nandakumar and Nasim, 2018; Nasim *et al.*, 2018; Janani, Palanivelu and Sandhya, 2020) and lab animal studies (Teja, Ramesh and Priya, 2018) and in-vitro studies(Ramanathan and Solete, 2015; Noor, S Syed Shihaab and Pradeep, 2016; Kumar and Delphine Priscilla Antony, 2018; Manohar and Sharma, 2018; Ravinthar and Jayalakshmi, 2018; Rajakeerthi and Ms, 2019; Rajendran *et al.*, 2019a; Siddique *et al.*, 2019; Teja and Ramesh, 2019; Jose, P. and Subbaiyan, 2020) over the past 5 years. Now we are focussing on epidemiological surveys. The idea for this survey stemmed from the current interest in our community. Our team has rich experience in research and we have collaborated with numerous authors over various topics in the past decade (Deogade, Gupta and Ariga, 2018; Ezhilarasan, 2018; Ezhilarasan, Sokal and Najimi, 2018; Jeevanandan and Govindaraju, 2018; J *et al.*, 2018; Menon *et al.*, 2018; Prabakar *et al.*, 2018; Rajeshkumar *et al.*, 2018, 2019; Vishnu Prasad *et al.*, 2018; Wahab *et al.*, 2018; Dua *et al.*, 2019; Duraisamy *et al.*, 2019; Ezhilarasan, Apoorva and Ashok Vardhan, 2019; Gheena and Ezhilarasan, 2019; Malli Sureshbabu *et al.*, 2019; Mehta *et al.*, 2019; Panchal, Jeevanandan and Subramanian, 2019; Rajendran *et al.*, 2019b; Ramakrishnan, Dhanalakshmi and Subramanian, 2019; Sharma *et al.*, 2019; Varghese, Ramesh and Veeraiyan, 2019; Gomathi *et al.*, 2020; Samuel, Acharya and Rao, 2020)

Hence, the present study intends to evaluate the prevalence of the occurrence of Radix Entomolaris in the Chennai Population reporting to the Outpatient Department for various treatments and their gender prevalence.

MATERIALS AND METHODS

This retrospective clinical study evaluated the patients who underwent root canal treatment in first mandibular teeth and suggestive of Radix Entomolaris based on radiographic examination.

DATA EXTRACTION - Over 1503 patients' records were selected for this study based on inclusion and exclusion criteria from June 2019 to March 2020.

Inclusion criteria- Presence of Radix Entomolaris in mandibular first molar.

Exclusion criteria - Normal root canal anatomy with no additional roots in mandibular first molar.

The collected data was entered in the Microsoft Excel sheet and grouping was done. The two parameters in this study were the gender of the patients and the presence of radix entomolaris in first mandibular molar teeth.

After grouping of parameters, data copied to SPSS software. The statistical analysis between different groups was carried out in SPSS software. A Chi-square test was done to compare genders and the occurrence of Radix Entomolaris.

RESULTS AND DISCUSSION

Among 1503 patients the prevalence of patients with Radix Entomolaris was only 0.5% (7 of 1503). For females, the prevalence was 0.47% (4 of 843) and 0.45% for males (3 of 660) [Figure 1]. The results showed there is no significant difference between genders and the occurrence of Radix Entomolaris ($P > 0.05$) [Figure 2].

In this present study, root canal treatment done in mandibular first molars are analyzed and correlated with the gender and occurrence of Radix Entomolaris. All the root canal of mandibular molars with Radix Entomolaris were segregated based on genders. Out of the total sample size of 1503 patients, 660 patients are male and 843 patients are females. The chi-square test shows an insignificant value $P > 0.05$ between the occurrence of Radix Entomolaris and gender prevalence.

Here, 3 variables were assessed (Gender, Tooth Number, Presence of RE). The results show males have higher prevalence compared to females and the mandibular first molar having the highest percentage reported with Radix Entomolaris.

7 of 1503 samples have the occurrence of Radix Entomolaris, consisting of 4 males and 3 females. The prevalence of Radix Entomolaris was 0.5% ($P>0.05$), 0.47% for females and 0.45% for males [Graph 3]

In comparison with other studies, a study done in a population of Iranian shows a 6% prevalence of mandibular first molar teeth (15/250) and 0.8% prevalence of mandibular second molar teeth (2/250). The prevalence of Radix Entomolaris in first molars is 6% higher than reported rates in other research studies done in the European or Caucasian population previously. The prevalence of Radix Entomolaris in these two populations typically less than 2%, but much less than the Mongoloid trait. (Kuzekanani, Haghani and Nosrati, 2012; Kuzekanani *et al.*, 2017)

Studies are done among the South Indian population reported by Chandra SS *et al.* which included 500 patients of South Indian origin reported an overall occurrence of 13.3% prevalence of Radix Entomolaris. This prevalence value was less than reported in other Asian populations, where the higher occurrence can be seen on the right side of the arch and in the female. (Chandra *et al.*, 2011)

In a study done in the Palestinian population of 222 patients, the incidence of patients with three rooted mandibular first molars was 3.73%. The finding was in the range of previous reports on Middle Easterners, but it is considerably lower than the percentage if compared to the Far East population. (Mukhaimer and Azizi, 2014) This study used conventional two-dimensional radiographs for assessment of Radix Entomolaris, where it would be considered as a limitation in the clinical approach-methodology of this study. (Ahmed *et al.*, 2007)

In a clinical study done by Mukhaimer and Azizi on a total of 322 mandibular first molars that underwent for root canal treatment at the Dental Center of the Arab American university reported that the incidence of Radix Entomolaris is 3.73% for the Palestinian group of patients which is within the range limits of previous reports of Middle East but lower than the far east significantly. (Mukhaimer and Azizi, 2014)

A retrospective study by Shemesh *et al.*, a total of 1020 Israeli patients examined by using Cone Beam Computed Tomographic scans showed the Radix Entomolaris incidence of 2.03% in mandibular first and second molars of this population. In 26% of these cases, the Radix Entomolaris happened bilaterally while there was no significant difference in the incidence of the Radix Entomolaris between different genders or sites of occurrence. (Shemesh *et al.*, 2015) Our institution is passionate about high quality evidence based research and has excelled in various fields (Pc, Marimuthu and Devadoss, 2018; Ramesh *et al.*, 2018; Ezhilarasan, Apoorva and Ashok Vardhan, 2019; Ramadurai *et al.*, 2019; Sridharan *et al.*, 2019; Vijayashree Priyadharsini, 2019; Mathew *et al.*, 2020)

The limitation of this present study can be improved by increasing the sample size. In the future, the present study can be a plan in better scope with larger sample size.

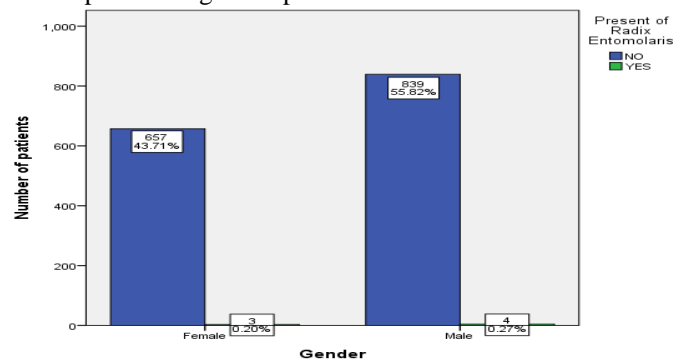


Fig.1: Bar graph showing the occurrence of Radix Entomolaris in different gender. The X-axis represents the occurrence of Radix Entomolaris in male and female patients, and Y-axis represents the total number of patients reported. The bar chart depicted that the prevalence of Radix Entomolaris is higher in female patients with 0.47% (4 of 843).

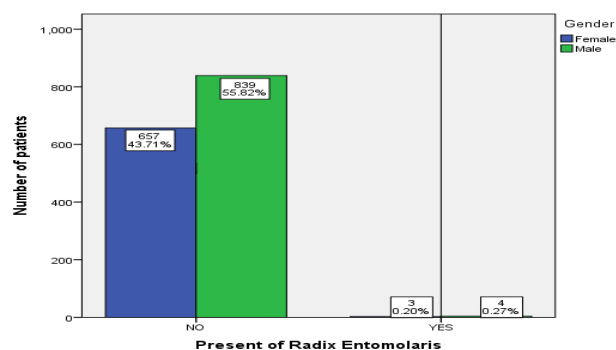


Fig.2: Bar graph showing the association between the occurrence of Radix Entomolaris and the gender prevalence . The X-axis represents the different gender and the occurrence of Radix Entomolaris, Y-axis represents the number of patients having Radix Entomolaris. The Chi-square test was done, P-value=0.955, (P>0.05), which is statistically non significant. There is no association between the occurrence of Radix Entomolaris and the gender.

CONCLUSION

Within the limitation of the study, it showed that the prevalence of Radix Entomolaris is 0.47% for females and 0.45% for males, with an overall 0.5% in both genders and more common in mandibular first molars this population. However, there is no significant evidence suggesting that gender plays a major role in the occurrence of Radix Entomolaris.

AUTHOR CONTRIBUTIONS

The authors have contributed to study design, data collection, analysis of data, tabulation of results, manuscript typing, and formatting. and critical reviewing.

ACKNOWLEDGMENTS

The authors thank Saveetha Dental College and Hospital, India for providing infrastructure support for the conduct of the study.

CONFLICT OF INTEREST

The authors deny any conflicts of interest regarding publishing this article.

REFERENCES

1. Ahmed, H. A. *et al.* (2007) 'Root and canal morphology of permanent mandibular molars in a Sudanese population', *International endodontic journal*, 40(10), pp. 766–771.
2. Bahammam, H. A. and Bahammam, L. A. (2012) 'The incidence of radix entomolaris in mandibular first permanent molars in a Saudi Arabian Sub-Population', *Journal of King Abdulaziz University: Medical Sciences*, 98(284), pp. 1–16.
3. Calberson, F. L., De Moor, R. J. and Deroose, C. A. (2007) 'The radix entomolaris and paramolaris: clinical approach in endodontics', *Journal of endodontia*, 33(1), pp. 58–63.
4. Chandra, S. S. *et al.* (2011) 'Prevalence of radix entomolaris in mandibular permanent first molars: a study in a South Indian population', *Oral surgery, oral medicine, oral pathology, oral radiology, and endodontics*, 112(3), pp. e77–82.
5. Cohen, S. and Burns, R. C. (2002) 'Pathways of the pulp, St. Louis'. Mosby, Inc.
6. Colak, H., Ozcan, E. and Hamidi, M. M. (2012) 'Prevalence of three-rooted mandibular permanent first molars among the Turkish population', *Nigerian journal of clinical practice*, 15(3), pp. 306–310.
7. Deogade, S., Gupta, P. and Ariga, P. (2018) 'Effect of monopoly-coating agent on the surface roughness of a tissue conditioner subjected to cleansing and disinfection: A Contact Profilometric In vitro study', *Contemporary Clinical Dentistry*, p. 122. doi: 10.4103/ccd.ccd_112_18.
8. Dua, K. *et al.* (2019) 'The potential of siRNA based drug delivery in respiratory disorders: Recent advances and progress', *Drug development research*, 80(6), pp. 714–730.
9. Duraisamy, R. *et al.* (2019) 'Compatibility of Nonoriginal Abutments With Implants: Evaluation of Microgap at the Implant-Abutment Interface, With Original and Nonoriginal Abutments', *Implant dentistry*, 28(3), pp. 289–295.
10. Ezhilarasan, D. (2018) 'Oxidative stress is bane in chronic liver diseases: Clinical and experimental perspective', *Arab journal of gastroenterology: the official publication of the Pan-Arab Association of Gastroenterology*, 19(2), pp. 56–64.
11. Ezhilarasan, D., Apoorva, V. S. and Ashok Vardhan, N. (2019) 'Syzygium cumini extract induced reactive oxygen species-mediated apoptosis in human oral squamous carcinoma cells', *Journal of oral pathology & medicine: official publication of the International Association of Oral Pathologists and the American Academy of Oral Pathology*, 48(2), pp. 115–121.
12. Ezhilarasan, D., Sokal, E. and Najimi, M. (2018) 'Hepatic fibrosis: It is time to go with hepatic stellate cell-specific therapeutic targets', *Hepatobiliary & pancreatic diseases international: HBPD INT*, 17(3), pp. 192–197.
13. Garg, A. K. *et al.* (2010) 'Prevalence of three-rooted mandibular permanent first molars among the Indian Population', *Journal of endodontia*, 36(8), pp. 1302–1306.
14. Gheena, S. and Ezhilarasan, D. (2019) 'Syringic acid triggers reactive oxygen species-mediated cytotoxicity in HepG2 cells', *Human & experimental toxicology*, 38(6), pp. 694–702.
15. Gomathi, A. C. *et al.* (2020) 'Anticancer activity of silver nanoparticles synthesized using aqueous fruit shell extract of Tamarindus indica on MCF-7 human breast cancer cell line', *Journal of Drug Delivery*

- Science and Technology*, p. 101376. doi: 10.1016/j.jddst.2019.101376.
16. Janani, K., Palanivelu, A. and Sandhya, R. (2020) 'Diagnostic accuracy of dental pulse oximeter with customized sensor holder, thermal test and electric pulp test for the evaluation of pulp vitality - An in vivo study', *Brazilian Dental Science*. doi: 10.14295/bds.2020.v23i1.1805.
 17. Jeevanandan, G. and Govindaraju, L. (2018) 'Clinical comparison of Kedo-S paediatric rotary files vs manual instrumentation for root canal preparation in primary molars: a double blinded randomised clinical trial', *European Archives of Paediatric Dentistry*, pp. 273–278. doi: 10.1007/s40368-018-0356-6.
 18. Jose, J., P., A. and Subbaiyan, H. (2020) 'Different Treatment Modalities followed by Dental Practitioners for Ellis Class 2 Fracture – A Questionnaire-based Survey', *The Open Dentistry Journal*, pp. 59–65. doi: 10.2174/1874210602014010059.
 19. J, P. C. et al. (2018) 'Prevalence and measurement of anterior loop of the mandibular canal using CBCT: A cross sectional study', *Clinical implant dentistry and related research*, 20(4), pp. 531–534.
 20. Kumar, D. and Delphine Priscilla Antony, S. (2018) 'Calcified Canal and Negotiation-A Review', *Research Journal of Pharmacy and Technology*, p. 3727. doi: 10.5958/0974-360x.2018.00683.2.
 21. Kuzekanani, M. et al. (2017) 'Radix Entomolaris in the Mandibular Molar Teeth of an Iranian Population', *International journal of dentistry*, 2017, p. 9364963.
 22. Kuzekanani, M., Haghani, J. and Nosrati, H. (2012) 'Root and canal morphology of mandibular third molars in an Iranian population', *Journal of dental research, dental clinics, dental prospects*, 6(3), pp. 85–88.
 23. Malli Sureshababu, N. et al. (2019) 'Concentrated Growth Factors as an Ingenious Biomaterial in Regeneration of Bony Defects after Periapical Surgery: A Report of Two Cases', *Case reports in dentistry*, 2019, p. 7046203.
 24. Manohar, M. P. and Sharma, S. (2018) 'A survey of the knowledge, attitude, and awareness about the principal choice of intracanal medicaments among the general dental practitioners and nonendodontic specialists', *Indian journal of dental research: official publication of Indian Society for Dental Research*, 29(6), pp. 716–720.
 25. Mathew, M. G. et al. (2020) 'Evaluation of adhesion of Streptococcus mutans, plaque accumulation on zirconia and stainless steel crowns, and surrounding gingival inflammation in primary ...', *Clinical oral investigations*. Available at: <https://link.springer.com/article/10.1007/s00784-020-03204-9>.
 26. Mehta, M. et al. (2019) 'Oligonucleotide therapy: An emerging focus area for drug delivery in chronic inflammatory respiratory diseases', *Chemico-biological interactions*, 308, pp. 206–215.
 27. Menon, S. et al. (2018) 'Selenium nanoparticles: A potent chemotherapeutic agent and an elucidation of its mechanism', *Colloids and Surfaces B: Biointerfaces*, pp. 280–292. doi: 10.1016/j.colsurfb.2018.06.006.
 28. Mukhaimer, R. and Azizi, Z. (2014) 'Incidence of Radix Entomolaris in Mandibular First Molars in Palestinian Population: A Clinical Investigation', *International scholarly research notices*, 2014, p. 405601.
 29. Nandakumar, M. and Nasim, I. (2018) 'Comparative evaluation of grape seed and cranberry extracts in preventing enamel erosion: An optical emission spectrometric analysis', *Journal of conservative dentistry: JCD*, 21(5), pp. 516–520.
 30. Nasim, I. et al. (2018) 'Clinical performance of resin-modified glass ionomer cement, flowable composite, and polyacid-modified resin composite in noncarious cervical lesions: One-year follow-up', *Journal of Conservative Dentistry*, p. 510. doi: 10.4103/jcd.jcd_51_18.
 31. Noor, S. S. S. E., S Syed Shihaab and Pradeep (2016) 'Chlorhexidine: Its properties and effects', *Research Journal of Pharmacy and Technology*, p. 1755. doi: 10.5958/0974-360x.2016.00353.x.
 32. Panchal, V., Jeevanandan, G. and Subramanian, E. M. G. (2019) 'Comparison of post-operative pain after root canal instrumentation with hand K-files, H-files and rotary Kedo-S files in primary teeth: a randomised clinical trial', *European archives of paediatric dentistry: official journal of the European Academy of Paediatric Dentistry*, 20(5), pp. 467–472.
 33. Pc, J., Marimuthu, T. and Devadoss, P. (2018) 'Prevalence and measurement of anterior loop of the mandibular canal using CBCT: A cross sectional study', *Clinical implant dentistry and related research*. Available at: <https://europepmc.org/article/med/29624863>.
 34. Prabakar, J. et al. (2018) 'Comparative Evaluation of Retention, Cariostatic Effect and Discoloration of Conventional and Hydrophilic Sealants - A Single Blinded Randomized Split Mouth Clinical Trial', *Contemporary clinical dentistry*, 9(Suppl 2), pp. S233–S239.
 35. Rajakeerthi, R. and Ms, N. (2019) 'Natural Product as the Storage medium for an avulsed tooth--A Systematic Review', *Cumhuriyet Dental Journal*, 22(2), pp. 249–256.
 36. Rajendran, R. et al. (2019a) 'Comparative Evaluation of Remineralizing Potential of a Paste Containing Bioactive Glass and a Topical Cream Containing Casein Phosphopeptide-Amorphous Calcium Phosphate: An in Vitro Study', *Pesquisa brasileira em odontopediatria e clinica integrada*, 19. Available at: http://www.scielo.br/scielo.php?pid=S1983-46322019000100364&script=sci_arttext.

37. Rajendran, R. *et al.* (2019b) 'Comparative Evaluation of Remineralizing Potential of a Paste Containing Bioactive Glass and a Topical Cream Containing Casein Phosphopeptide-Amorphous Calcium Phosphate: An in Vitro Study', *Pesquisa Brasileira em Odontopediatria e Clínica Integrada*, pp. 1–10. doi: 10.4034/pboci.2019.191.61.
38. Rajeshkumar, S. *et al.* (2018) 'Biosynthesis of zinc oxide nanoparticles using *Mangifera indica* leaves and evaluation of their antioxidant and cytotoxic properties in lung cancer (A549) cells', *Enzyme and microbial technology*, 117, pp. 91–95.
39. Rajeshkumar, S. *et al.* (2019) 'Antibacterial and antioxidant potential of biosynthesized copper nanoparticles mediated through *Cissus arnotiana* plant extract', *Journal of photochemistry and photobiology. B, Biology*, 197, p. 111531.
40. Ramadurai, N. *et al.* (2019) 'Effectiveness of 2% Articaine as an anesthetic agent in children: randomized controlled trial', *Clinical oral investigations*, 23(9), pp. 3543–3550.
41. Ramakrishnan, M., Dhanalakshmi, R. and Subramanian, E. M. G. (2019) 'Survival rate of different fixed posterior space maintainers used in Paediatric Dentistry - A systematic review', *The Saudi dental journal*, 31(2), pp. 165–172.
42. Ramamoorthi, S., Nivedhitha, M. S. and Divyanand, M. J. (2015) 'Comparative evaluation of postoperative pain after using endodontic needle and EndoActivator during root canal irrigation: A randomised controlled trial', *Australian endodontic journal: the journal of the Australian Society of Endodontology Inc*, 41(2), pp. 78–87.
43. Ramanathan, S. and Solete, P. (2015) 'Cone-beam Computed Tomography Evaluation of Root Canal Preparation using Various Rotary Instruments: An in vitro Study', *The Journal of Contemporary Dental Practice*, pp. 869–872. doi: 10.5005/jp-journals-10024-1773.
44. Ramesh, A. *et al.* (2018) 'Comparative estimation of sulfiredoxin levels between chronic periodontitis and healthy patients - A case-control study', *Journal of periodontology*, 89(10), pp. 1241–1248.
45. Ravinthar, K. and Jayalakshmi (2018) 'Recent Advancements in Laminates and Veneers in Dentistry', *Research Journal of Pharmacy and Technology*, p. 785. doi: 10.5958/0974-360x.2018.00148.8.
46. Samuel, S. R., Acharya, S. and Rao, J. C. (2020) 'School Interventions-based Prevention of Early-Childhood Caries among 3-5-year-old children from very low socioeconomic status: Two-year randomized trial', *Journal of public health dentistry*, 80(1), pp. 51–60.
47. Sharma, P. *et al.* (2019) 'Emerging trends in the novel drug delivery approaches for the treatment of lung cancer', *Chemico-biological interactions*, 309, p. 108720.
48. Shemesh, A. *et al.* (2015) 'Prevalence of 3- and 4-rooted first and second mandibular molars in the Israeli population', *Journal of endodontia*, 41(3), pp. 338–342.
49. Siddique, R. *et al.* (2019) 'Qualitative and quantitative analysis of precipitate formation following interaction of chlorhexidine with sodium hypochlorite, neem, and tulsi', *Journal of conservative dentistry: JCD*, 22(1), pp. 40–47.
50. Souza-Flamini, L. E. *et al.* (2014) 'The Radix Entomolaris and Paramolaris: A Micro-Computed Tomographic Study of 3-rooted Mandibular First Molars', *Journal of endodontics*, 40(10), pp. 1616–1621.
51. Sridharan, G. *et al.* (2019) 'Evaluation of salivary metabolomics in oral leukoplakia and oral squamous cell carcinoma', *Journal of oral pathology & medicine: official publication of the International Association of Oral Pathologists and the American Academy of Oral Pathology*, 48(4), pp. 299–306.
52. Teja, K. V. and Ramesh, S. (2019) 'Shape optimal and clean more', *Saudi Endodontic Journal*, 9(3), p. 235.
53. Teja, K. V., Ramesh, S. and Priya, V. (2018) 'Regulation of matrix metalloproteinase-3 gene expression in inflammation: A molecular study', *Journal of conservative dentistry: JCD*, 21(6), pp. 592–596.
54. Varghese, S. S., Ramesh, A. and Veeraiyan, D. N. (2019) 'Blended Module-Based Teaching in Biostatistics and Research Methodology: A Retrospective Study with Postgraduate Dental Students', *Journal of dental education*, 83(4), pp. 445–450.
55. Vijayashree Priyadharsini, J. (2019) 'In silico validation of the non-antibiotic drugs acetaminophen and ibuprofen as antibacterial agents against red complex pathogens', *Journal of periodontology*, 90(12), pp. 1441–1448.
56. Vishnu Prasad, S. *et al.* (2018) 'Report on oral health status and treatment needs of 5-15 years old children with sensory deficits in Chennai, India', *Special care in dentistry: official publication of the American Association of Hospital Dentists, the Academy of Dentistry for the Handicapped, and the American Society for Geriatric Dentistry*, 38(1), pp. 58–59.
57. Wahab, P. U. A. *et al.* (2018) 'Scalpel Versus Diathermy in Wound Healing After Mucosal Incisions: A Split-Mouth Study', *Journal of oral and maxillofacial surgery: official journal of the American Association of Oral and Maxillofacial Surgeons*, 76(6), pp. 1160–1164.
58. Walker, R. T. and Quackenbush, L. E. (1985) 'Three-rooted lower first permanent molars in Hong Kong Chinese', *British dental journal*, 159(9), pp. 298–299.

59. Wang, Q. *et al.* (2011) 'Evaluation of x-ray projection angulation for successful radix entomolaris diagnosis in mandibular first molars in vitro', *Journal of endodontia*, 37(8), pp. 1063–1068.